Title
CBCT Study of Mandibular, Vertical Facial and Airway Adaptation Related to the Temporomandibular Joint

Author
Dadgar-Yeganeh, Amir

Publication Date
2016

Peer reviewed|Thesis/dissertation

CBCT Study of Mandibular, Vertical Facial and Airway Adaptation Related to the Temporomandibular Joint

by

Amir Dadgar-Yeganeh, DDS

THESIS

Submitted in partial satisfaction of the requirements for the degree of

MASTER OF SCIENCE

in

Oral and Craniofacial Sciences

in the

GRADUATE DIVISION

of the

UNIVERSITY OF CALIFORNIA, SAN FRANCISCO

DEDICATION

I would like to dedicate this Master's Thesis to my amazing parents who have worked very hard and sacrificed by immigrating to the United States in order for my brother and me to have better opportunities in life. I also want to dedicate this Master's Thesis to my beloved grandmother, who was a symbol of strength and love, as she battled cancer for many years and stayed strong until the end. Last but not least, I would like to thank my loving brother for all his kindness and support throughout my life. Without my family, I would not be where I am today. I owe all of my successes in life to them.

ACKNOWLEDGEMENTS

First, I would like to thank my mentor, Dr. Snehlata Oberoi, for her utmost and constant support throughout the past 7 years, first, while I was as a dental student and then during my Orthodontic residency. Dr. Oberoi always pushed me to work harder, kept me on track and provided invaluable guidance including to facilitate collaboration with Dr. David Hatcher.

In addition, I would like to thank Dr. Hatcher for his dedication including to help guide me on this project, for sharing his knowledge and expertise, CBCT scans from the DDI Centers and for the numerous GoToMeetings to discuss the project.

Also, I would like to thank Dr. Ib Leth Nielsen for his very valuable advice and guidance on the topic of this project since the beginning and his mentorship throughout the years and Dr. Arthur Miller and Dr. Steven Frank for their guidance for the past 3 years and his constructive feedback as I chose my topic, designed my study and wrote this thesis. In addition, I would like to thank Dr. Michael Kohn for his help with the statistics.

Lastly, many thanks to UCSF dental students, Cassie Truong, Lauren Frisch, Janice Hwang and Moham Ansari for assisting me with my Masters' thesis project.

ABSTRACT

Background and Objective:

The vertical skeletal pattern, temporomandibular joint (TMJ) and the airway size of individuals are important factors to consider during orthodontic diagnosis and treatment planning. There is a tendency for both a reduction in airway dimensions and adaptation of mandibular structures secondary to TMJ degenerative disorders, inflammatory disorders and fracture. The purpose of this study was to evaluate the association between these selected TMJ disorders and facial type, to correlate facial types with airway dimensions and to evaluate the association between selected TMJ disorders and airway dimensions.

Materials and Methods:
This was a two-component study: the first component was a case-control study, 22 cases and 242 controls, determining the association between facial type and TMJ degenerative disorders, inflammatory disorders and fracture with the outcome being TMJ degenerative, inflammatory disorder or fracture and the predictor being facial types. The second component was a cross-sectional study, 22 cases and 66 controls divided equally in three groups of low, normal and high mandibular plane angles, determining the association between airway dimensions and mandibular phenotypic characteristics. CBCT scans of adults (female 16 years of age or older and male 18 years of age and older) that included the entire mandible as well the cephalometric landmark nasion. The 3D CBCT scan of the individuals were evaluated and measurements were done using Invivo Anatomage, Dolphin Imaging and Vultus 3DMD programs. Odds ratio were calculated based on facial type and gender. ANOVA was used to compare the airway volume and cross section and mandibular measurements between the groups.

Results:

The odds of having a long face subject within the case group was significantly higher compared to having a long-face subject in control group. 81% of the case subjects with TMJ involvement had a long vertical facial dimension versus 11% of the control group that had a normal TMJ indicating a highly statistically significant difference. The condylar, ramus, and mandibular heights were significantly smaller in the case group with the TMJ pathology compared to the control group. Ramus height and mandibular alveolar housing for central incisors were significantly smaller in the long face subjects in the control group. The smallest cross sectional area of the airway of the cases was significantly narrower compared to the controls, however, there was no differences in airway volume. There was a considerable trend, not statistically significant, in reduction of the airway smallest cross sectional area and volume, as the facial type got longer within the control group.

Conclusions:

The results of this study suggest that a long facial type is strongly associated with previous TMJ inflammatory disorders and degenerative disorders or a fracture of the condyle. There are certain skeletal and dentofacial adaptations that follow resulting in vertical dimension changes, more specifically, smaller condylar process, ramus and body of the mandible height, thinner alveolar housing at the lower incisor region and smaller cross-sectional area of the airway.

The results from this study suggest that clinician should carefully monitor the TMJ status in adult individuals with hyperdivergent facial type.

Key words: TMJ, TMD, Airway, CBCT, Vertical facial height, Growth adaptation

TABLE OF CONTENTS **PAGE**

INTRODUCTION…….....1

Background……1

Condyle……...1

Airway……4

Temporomandibular Disease(TMD) ……..4

Specific Aims & Hypothesis……..7

HYPOTHESIS……....7

METHODS AND MATERIAL……8

Study Design……8

Inclusion Criteria.……...8

Exclusion Criteria……...8

Subjects…….……...9

TMJ & Condylar Analysis…….…….……..10

Cone Beam CT Scan…….…….……14

Individual Orientation…….…….……14

Lateral Ceph…….…….…….……...15

Measurement of Mandibular Phenotypic Characteristics.……...16

Measurement of Airway Volume and Smallest Cross-sectional Area. ……..19

Statistical Analysis…….……..….……20

RESULTS……...…22

Vertical Facial Dimensions……...…22

Mandibular Measurements…….....22

Airway Measurements…….....24

DISCUSSION…….25

CONCLUSIONS……...….31

REFERENCES……..……..…..32

LIST OF TABLES **PAGE**

TABLE 1: Type comparison……..……22

TABLE 2: Measurement comparison cases and controls long faces…….23

TABLE 3: Measurement by facial type in control groups…….23

LIST OF FIGURES **PAGE**

FIGURE 1: Flow chart of dividing the DICOM scans **…….10**

FIGURE 2: Vertical range of TMJ slices **…….11**

FIGURE 3: Example of the InVivo5 Anatomage slices of the TMJ **……12**

FIGURE 4: Sagittal oblique CBCT of the condylar shape, size and cortication**……...13**

FIGURE 5: Volumetric images of one subject from three different views **……..14**

FIGURE 6: Example of lateral cephalometric analysis **……15**

FIGURE 7: Example of the 2D panoramic view **……..16**

FIGURE 8: The different measurements from a CBCT generated panoramic vi**ew….17**

FIGURE 9: Horizontal view through the mandibular dentition **…….…..18**

FIGURE 10: Schematic of measurements through the sagittal view of the tooth**…..…19**

FIGURE 11: Example of the airway measurements **…….20**

FIGURE 12: Comparison of airway between long faces in cases and control **…….24**

FIGURE 13: Airway measurements in the control group **…….24**

INTRODUCTION

Background

The anterior facial vertical skeletal growth pattern of individuals is an important factor in orthodontic diagnosis and treatment planning. It is determined by the angle between sella-nasion line (SN) and the mandibular plane or gonion-gnathion line (MP), referred to as the mandibular plane angle. The low range of this angle is ≤ 28 degrees and is defined as hypodivergent; the average range is between 28 and 39 degrees, defined as normodivergent; and ≥ 39 degrees is hyperdivergent. Hypodivergence usually signifies a deep anterior overbite and a reduced lower vertical facial height.[1] Hyperdivergence is often associated with a shallow anterior overbite, in some cases, open bite, and an excessive vertical facial height.[2] Normodivergent is generally associated with well-balanced facial features.

Condyle

Condylar morphology and position within the temporomandibular joint (TMJ) is associated with vertical skeletal patterns. [3] The larger the condylar position discrepancy between the centric relation (CR) and maximum intercuspation (MIP), the more difficult to achieve the desired orthodontically ideal results post treatment.[3] In general, even small changes in condylar position will affect the occlusion with greatest effect in the hyperdivergent skeletal type.[3] Hyperdivergent facial types have a greater frequency of internal derangement; *i.e.,* when the condyle is distracted away from the eminence, the temporomandibular ligaments may be elongated in order to accommodate this mandibular position. This may be a consequence of degenerative changes within the temporomandibular joints.[4] Condylar size and shape are correlated with mandibular divergence in young adults. [5] However, little is known about the association between vertical skeletal pattern and condylar position and morphology.[5]

Individuals with hyperdivergent growth patterns display decreased superior joint spaces and posteriorly angled condyles, whereas, individuals with normal- or hypodivergent growth demonstrated increased superior joint spaces and anteriorly angled condyles.[6] Hyperdivergent facial morphology is associated with smaller antero-posterior and medio-lateral condyle width as well as smaller angle between the condylar axis and the midsagittal plane (condyle head angle).[7] In axial view, round condyles were found in individuals with hyperdivergent facial morphology, whereas oval condyles were noted in those with hypodivergent facial morphology.[7] Individuals with the hyperdivergent skeletal pattern tend to have smaller and more superiorly positioned condyles than those with hypodivergent skeletal pattern. Overall, condylar position and morphology varies according to vertical facial morphology.[7]

The condyle, shows a continuous adaptability to functional stimuli.[8] During adulthood, the condyle is often subjected to ongoing degeneration, such as flattening, erosion, sclerosis, osteophyte formation, and resorption, which could affect its size and shape.[8] The adaptations to stress concentrations in the TMJs results from the interaction of muscle and tooth force vectors. Maximum occlusal force, masticatory electromyography (EMG) activity, and medial mandibular flexure vary in relation to vertical facial pattern [9]

The size of the mandible, including the corpus, ramus, and condyle, as well as the timing and amount of condylar growth, vary considerably between individuals. [10] Factors potentially contributing to this individual variation are the extent of masticatory action and genetic predisposition. Several different acquired temporomandibular conditions (TMDs) when associated with a maxillofacial growth disorder manifest similar morphologic changes that can be detected radiographically. The range of conditions that result in morphological change

extends from minor insult (TMJ disc displacement) to severe insult (Juvenile Idiopathic Arthritis). [10]

The TMJ is in a constant state of remodeling, which under normal conditions maintains the functional and mechanical relationships between the articulating surfaces of the joint and ensures homeostasis of the joint form and function as well as an optimal occlusal relationship between the dental arches.[11] When the equilibrium between the host adaptive capacity and the stresses placed on the joint is lost, dysfunctional remodeling can cause changes in condylar shape and size.[12] The degenerative changes of the TMJ are more common in individuals with skeletal jaw discrepancies and wide variations are observed even in those with clinically similar malocclusion. [13]

Mandibular growth involves both endochondral and periosteal (interstitial) activity. The endochondral growth occurs along the anterosuperior surface of the condyle where undifferentiated mesenchymal cells reside in the fibrocartilage cap. Functional loading received by the fibrocartilage initiates differentiation of the mesenchymal cells to produce more fibrocartilage. The fibrocartilage thickens along the axis of the principle force vector. There is endochondral bone replacement of the thickened cartilage at the interface between the bone and cartilage, which enlarges condyle along the same principle axis of the force direction. Condylar growth occurring at the anterosuperior surface of the condyles drives mandibular growth in a counterclockwise (CCW) direction. Insults to the fibrocartilage (degenerative disorders, inflammatory disorders and fractures) reduce or stop the endochondral bone formation and therefore no CCW growth. [14]

Airway

Airway shape differs with various vertical jaw relationships. Variability is greater among the high vertical facial groups, and differences in shape are difficult to characterize. An extremely narrow airway, both antero-posteriorly (width) and superiorly-inferiorly (length), is associated more often with long-face individuals compared with individuals with normative facial proportions.[15]

The facial phenotype can be secondary to aberrant mandibular growth, which can be associated with alterations in airway dimensions, airway resistance, and functional airway patency.[16] The anteroposterior dimensions of the airway have been shown to have a proportional relationship to jaw growth and facial growth pattern.[17] The airway is largest when there is normal mandibular and maxillary growth and when facial growth pattern occurs with a counter-clockwise rotation. Conversely, the airway is smaller with deficient maxillary and mandibular growth and when there is a clockwise facial growth pattern. Because mandibular growth is linked to condylar growth, and reduced condylar growth can be associated with degenerative joint disease (DJD), also known as osteoarthritis, it is reasonable to postulate that a developmental onset of DJD may limit airway dimensions. [19]

Temporomandibular Joint Disease (TMD)

TMD is a collective term used to describe a number of related disorders associated with the TMJ and does not distinguish between muscle or joint-related problems[20] Degenerative joint disease (DJD) is a localized noninflammatory degenerative disorder of synovial joint characterized by destruction and repair of articular fibrocartilage and underlying subchondral bone. Osseous signs of DJD are usually preceded by nonreducing anteriorly displaced disc. DJD incidence is highest prior to age 40 with a peak for females following puberty; females are most

susceptible between puberty and menopause. There is a 8.5;1 ratio of female to male predilection. DJD progresses until equilibrium between form and function is achieved. Progressive condylar resorption (PCR) is a localized non-inflammatory degenerative disorder of the TMJs that is characterized by lysis and repair of the articular fibrocartilage and underlying subchondral bone following onset of puberty in females. PCR is associated with rapid loss of condylar volume. PCR closely follows onset of puberty and has a rare occurrence after age 20. Gender predilection is 9:1 Female to male. Juvenile Idiopathic Arthritis (JIA) is an autoimmune musculoskeletal inflammatory disease in childhood with female predilection that is 70% asymptomatic. Condylar fracture occurs at condylar neck and often accompanied by dislocation of condyle with a male to female predilection ratio of M>F (3:1). [14]

TMD has been recognized to have a predilection for women and can be identified at all ages after puberty. Individuals with bilateral PCR, may develop a dolichofacial growth pattern.[19] It has been suggested that sex hormones and hormone receptors may play a role in the early age onset and sex predilection of this phenomenon.[19, 21] The dolichofacial growth pattern may be associated with short condylar processes, short rami, a short mandibular body, and increased vertical dimension of the anterior region of the mandible along with labiolingual reduction in the dimensions of the alveolar process in the anterior region of the mandible. The mandibular plane may be steep, and the gonial angles obtuse. There is a tendency for a reduction in airway dimensions secondary to a small mandible, and posterior inferior repositioning of the mandibular symphysis.[19]

Imaging of the TMJs and the maxillofacial complex and subsequent interpretation of selected anatomic features is the method used to diagnose the specific acquired abnormality present. There is similar facial growth pattern for any number of jaw joint issues such as

fracture, inflammatory and non-inflammatory arthritis, and disc displacement. If joint damage occurs in a growing individual, the growth pattern and the phenotypic features of the mandible and face will be changed. The occurrence of condylar changes due to fracture, degenerative or inflammatory disease has the potential to significantly limit mandibular growth. The combination of the clockwise rotation of the mandible (dolichofacial growth pattern) and a small mandible may allow posterior inferior repositioning of the tongue and suprahyoid tissues, leading to a reduction in the airway dimension. [19]

The elongated symphysis in individuals with a dolichofacial growth may be associated with a labiolingually deficient alveolar trough of bone to support the incisor teeth. Orthodontic manipulations of the teeth in a narrow alveolar trough may exceed the anatomic boundary of the mandible and result in root resorption, periodontal disease, and tooth loss. [19]

The idea behind this study is based on extensive clinical and radiographic interpretation of numerous 3D scans of individuals with different vertical face heights, TMJ characteristics, mandibular phenotypes, and airway measurements. This study is introducing the idea that "the long vertical face" may be an adaptation to a TMJ insult including inflammatory disorders, degenerative disorders and fractures. The purpose of this present study is to evaluate the TMJ and airway in different facial types, as it is believed that the compensatory adaptation and growth pattern of the mandible can affect the airway as a consequence of growth characteristics of the condyle. Since the TMJ, vertical jaw relationship, and airways are areas of high interest to the orthodontists, it would be important to study the relationship among them.

The mandibular growth deficiency is inversely proportional to the age of onset. Therefore, if subsequent growth does not occur, the growth deficit will be greater the earlier the insult occurs. If joint damage occurs well after puberty, then the craniofacial growth is closer to

normal. The eventual outcome has to do primarily with timing and the severity of the insult, to a lesser degree the type of insult. [19]

Specific Aims and Hypotheses

This study has three objectives and specific aims: 1) to evaluate the association between TMJ degenerative disorders, inflammatory disorders, and fractures with vertical facial type; 2) to study the correlation of vertical facial types with airway volume and smallest cross-sectional area; 3) to evaluate the association between TMJ degenerative disorders, inflammatory disorders and fracture with airway volume and smallest cross-sectional area.

This study is proposing that "the long vertical face" is an adaptation to a TMJ insult because no matter what the TMJ problem, very similar morphologic changes occur. This study is not suggesting that people with dysfunctional joints always have a dolicofacial type of face or that a patient with dolicofacial type of face always has joint problems.

The following null hypotheses will be tested:

- There is no association between TMJ degenerative disorders, inflammatory disorders and fracture and different facial types.
- There is no association between TMJ degenerative disorders, inflammatory disorders and fracture and airway volume and smallest cross-sectional area
- There is no correlation between airway volume and smallest cross-sectional area among different facial types

METHODS AND MATERIALS

Study design

This is a study with two components: The first component is a case-control study of association between vertical facial type and TMJ degenerative disorders, inflammatory disorders and fracture; outcome being TMJ degenerative, inflammatory disorder and fracture and the predictor being facial types.

The second component is a cross-sectional study of the association between predictors of facial type and presence or absence of TMJ disorder and two outcomes:

- Airway volume and smallest cross-sectional area
- Mandibular phenotypic characteristics (ramus height, body of the mandible height, condylar height, mandibular thickness/lower incisor alveolar housing)

Inclusion Criteria

Adult individuals (females who were 16 years of age or older and males 18 years of age and older) with scans that included the entire mandible as well the cephalometric landmark nasion with no obvious radiographic disease of TMJ were included.

Exclusion Criteria

Subjects were excluded if they were growing individuals at the time of the scan, had previous orthodontic treatment before the initial CBCT scan, or had any type of craniofacial anomaly (*i.e.,* cleft lip/palate, hemifacial microsomia). Subjects were also excluded for the following reasons: Radiographically visible mandibular asymmetry, post-orthognathic surgery scans**,** subjects lacking posterior vertical dental stops (affects vertical dimension of occlusion), scans taken with dental splints (affects vertical dimension of occlusion), poor scan resolution,

scans not taken in maximum intercuspal position, or apparent history of craniofacial trauma seen in CBCT

Specifically, for the control group, any subjects with radiographically evidence of degenerative disorders, inflammatory disorders and fractures were excluded.

Subjects

CHR approval was obtained for the study with an approval number of 10-00564. Non-growing individuals, females aged 16 and above and males aged 18 and above at the time of the cone-beam computed tomography scan were studied with scans taken at the DDI Imaging Center in Sacramento, California. All scans were taken using the i-CAT Cone Beam 3D Imaging System (Imaging Sciences International Inc., Hartfield, PA) with the subjects in an upright sitting position and with the individual's Frankfort horizontal plane parallel to the floor. The scanning settings for the CBCT machine were as follows: 120 kVP tube voltage, 18.45 to 47.74 mAS tube current, and 20-second scan time. All of the subject's personal identifying information was removed except for the birthdate.

For the case group, 44 consecutive DICOM files of individuals with a diagnosed TMJ degenerative disorder [*i.e.,* either Progressive Condylar Resorption (PCR), Degenerative Joint Disease (DJD)] and inflammatory disorder [i.e., Juvenile Idiopathic Arthritis] or fracture were selected. Thirty-one of those individuals' files met the inclusion criteria, and 13 were excluded.

For the control group, consecutive samples of 606 anonymous DICOM cone beam CT data files were obtained, previously used in a study by Contro *et al*. [22] Of this sample, 423 were female, 183 were males, ranging in age from 18 years to 90 years old. The initial sample was organized by DDI Imaging Center by decades of age as well as gender. No other demographic information was available on the subjects. Using inclusion and exclusion criteria, a sample of

242 subjects was compiled. This sample included 169 females and 73 males, which were considered eligible for the purpose of this study.[19] Considering our inclusion and extrusion criteria , our total sample was 273.

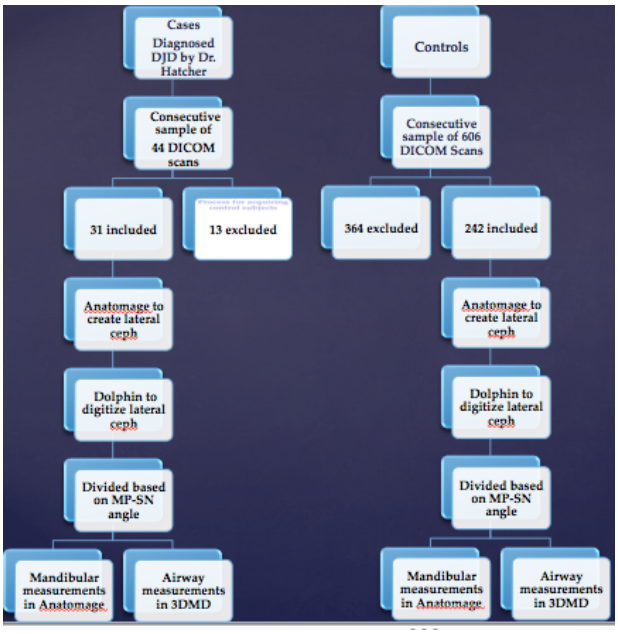

Figure 1. Flow chart of dividing the DICOM scans of cases and control subjects

TMJ and Condylar Analysis

The left and right condyles were evaluated using the following steps in the Invivo5 Anatomage software. In the TMJ Module, under Vertical Range and Orientation, the box "Adjust" was checked, which allowed the investigator to adjust the vertical range of the TMJ slices (green lines). The vertical range was determined to be between mid-ramus length and above condyle, as seen in Figure 2.

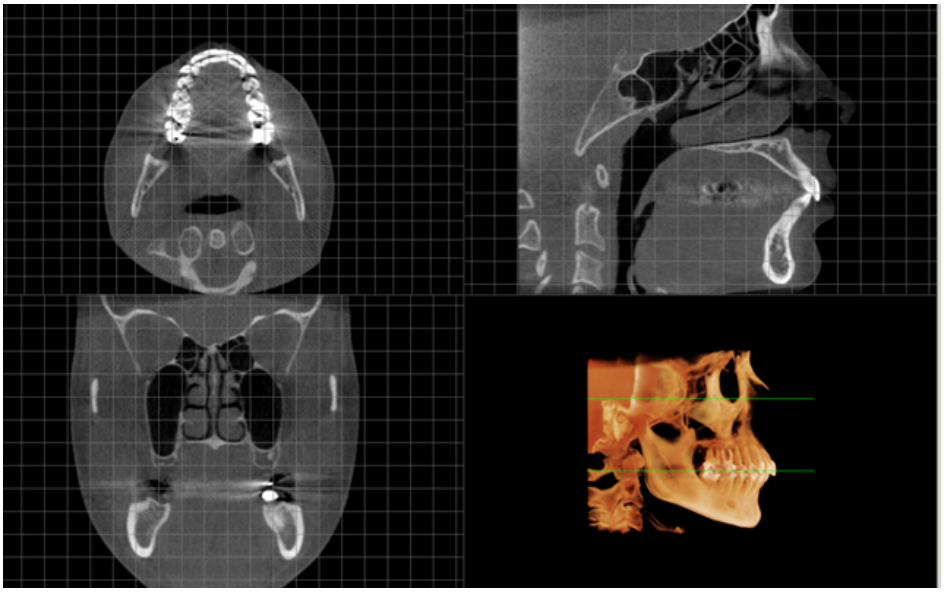

Figure 2: Vertical range of TMJ slices are determined by the green lines (mid-ramus and above condyle).

Then, the Adjust box was unchecked, and arch splines with green markings appeared at the center of the screen, with the axial slices in view. The arch splines (green markings) were aligned perpendicular to medial-lateral dimensions of the condyles on the axial slice, making sure the orange poles were parallel to the anterior surface of the condyle. Then, TMJ was assessed by scrolling through the condyle on the axial slices as well as the coronal slices (Figure 3). The left and right condyles were then compared to the graph of TMJ morphology (Figure 4).[23]

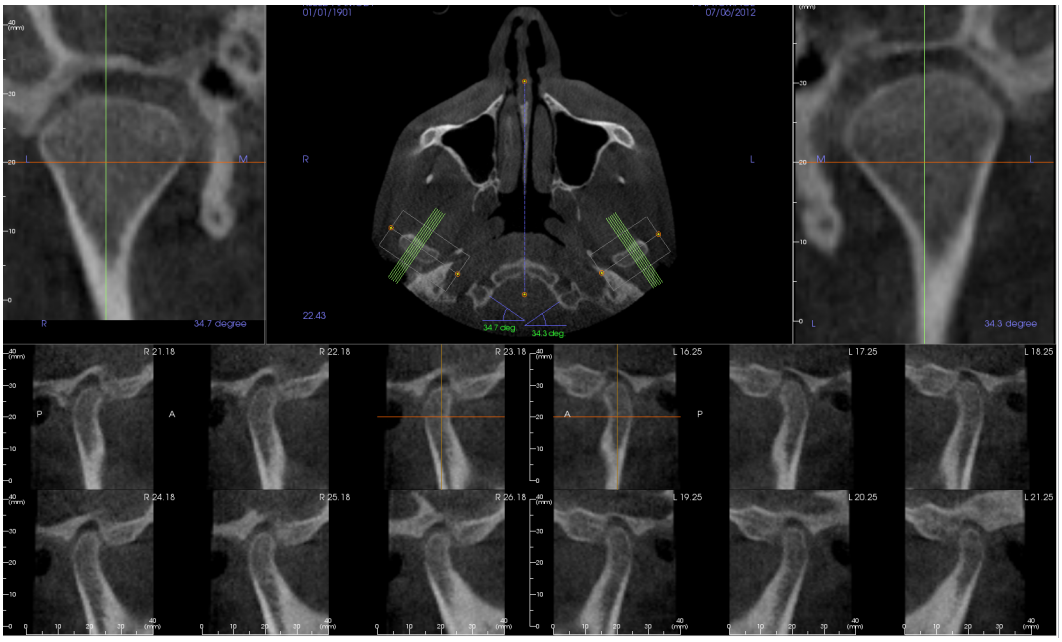

Figure 3: Example of the InVivo5 Anatomage slices of the TMJ, in which a corrected anteroposterior image was determined perpendicular to the mediolateral axis.

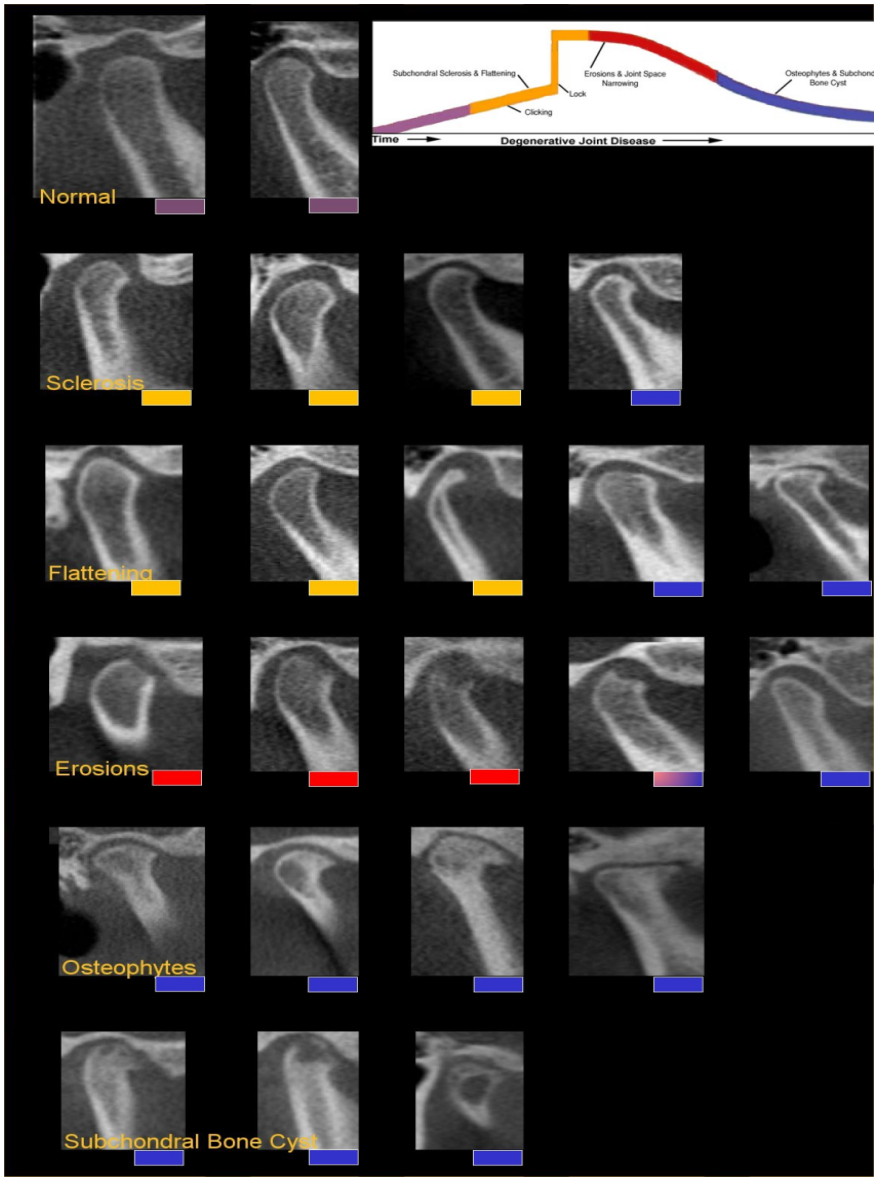

Figure 4: Sagittal oblique CBCT of the condylar shape, size and cortication. Degenerative joint disease progression is arranged so that severity increases from left to right and top to bottom. The purple color indicates normal. The yellow indicates remodeling. The red color indicates erosion during active DJD. The red-blue color shows incomplete repair. The blue indicates recortication, flattening and sclerosis of superior surface of the condyle. The blue further denotes formation of osteophytes and subcondylar bone cysts, joint space narrowing and joint congruence.

Cone beam CT Scans

Each of the 273 CBCT scans was loaded into the Anatomage InVivo software (Anatomage, San Jose, CA) for proper 3D individual orientation prior to rendering 2D radiographic cross sections for appropriate and consistent measurements.

Individual Orientation

As seen in the following figure, each scan volume was oriented in 3 planes (sagittal, axial, and coronal) prior to taking any measurements. Each subject was oriented to the Frankfort Horizontal plane (Figure 5a). On the coronal plane, they were oriented through a line passing through both infraorbital notches (Figure 5b). Axially, they were aligned to the line passing through a corresponding landmarks on skull base anatomy, the posterior border of foramen spinosum on both sides.(Figure 5c)

A. B. C.

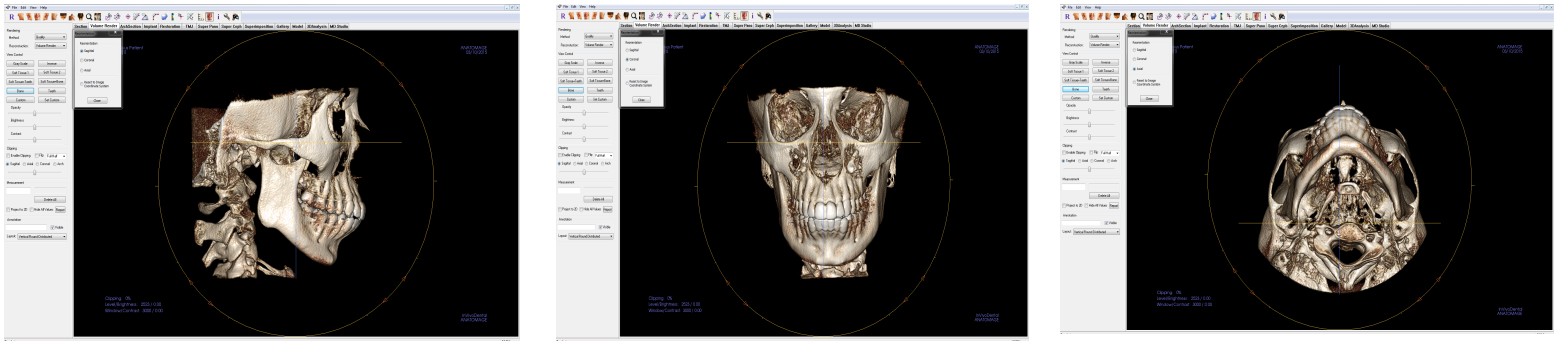

Figure 5: Volumetric images of one subject from three different views used to orient the scan prior to measurement. A. Sagittal, B. Coronal, C. Axial

Lateral Ceph

Each of the 273 CBCT scans was loaded into the Anatomage InVivo software (Anatomage, San Jose, CA) to generate traditional lateral cephalograms from the three-dimensional data. This was done aligning the three-dimensional scan facing right with malar prominences and each sides of the mandible lined up to best fit. Next the lateral cephalograms were loaded into Dolphin Imaging (Dolphin, Chatsworth, CA) and digitally traced and analyzed. The mandibular plane and sella-nasion line angle measurement was obtained on each subject to categorize them into different skeletal vertical pattern; low angle cases were: $\leq$ 28 degrees; average angle: 29-39 degrees; and high angle: $\geq$39 degrees (Figure 6).

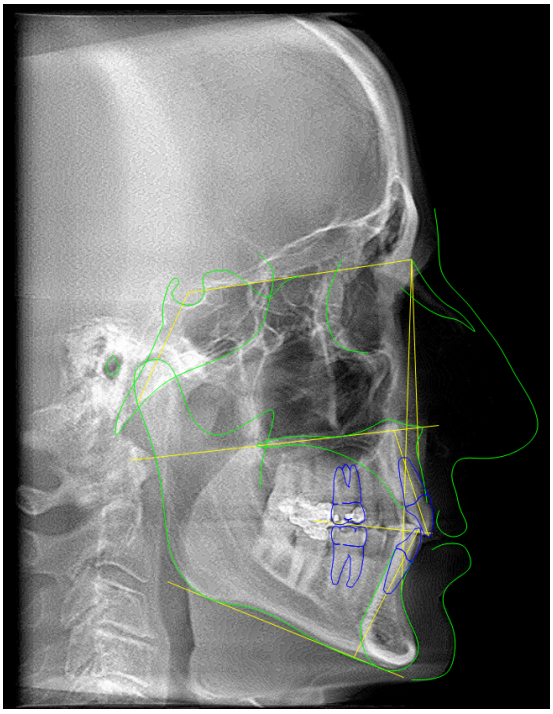

Figure 6: Example of lateral cephalometric analysis of one individual showing the SN-MP angle to determine the vertical facial dimension.

Measurement of mandibular Phenotypic Characteristics

For measurements of mandibular phenotypic characteristics, a panoramic view of the entire dentition including the condyles and a sagittal periapical cross section of lower incisors were generated (Figure 7).

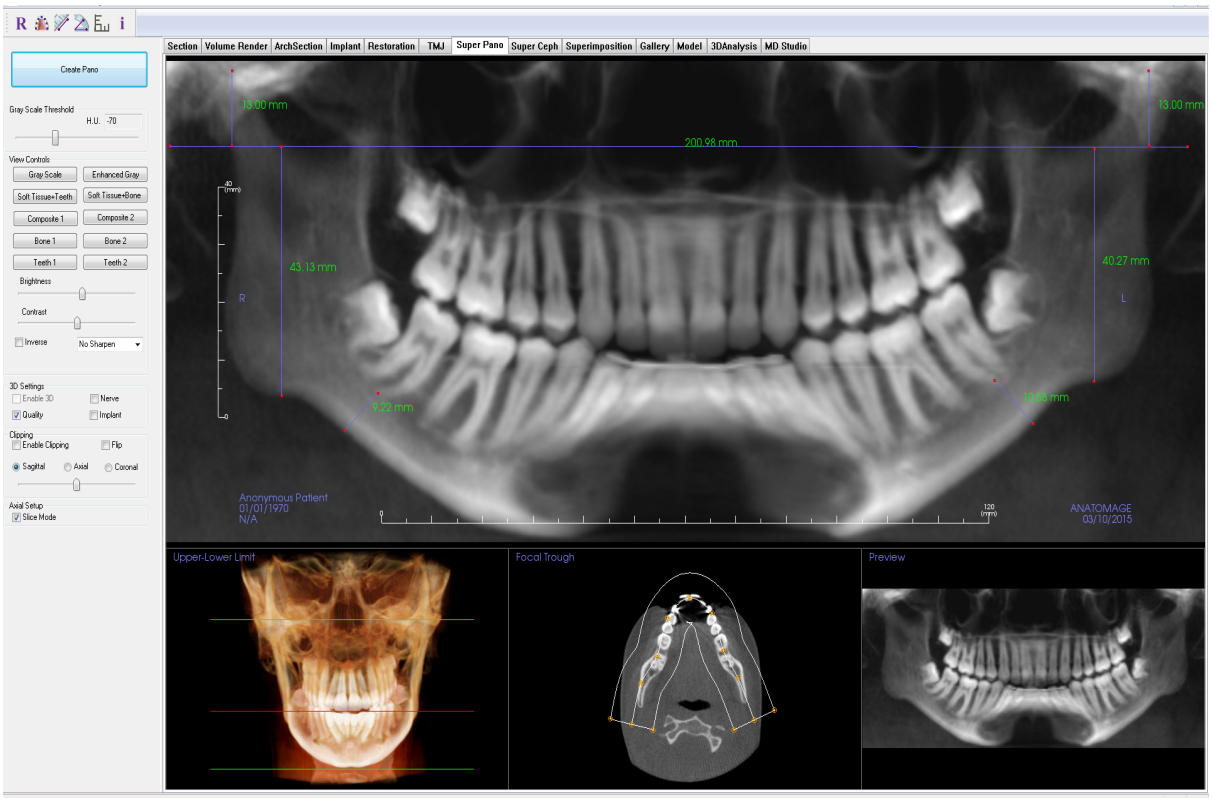

Figure 7: Example of the 2D panoramic view reconstructed from the volumetric view and horizontal view of one subject. Showing the measurements (green) that used.

Using the "Super-pano" tab in Anatomage, on slice, the green boundary was selected to be just above TMJ and under the symphysis. Then the horizontal red line indicator was selected to be on the occlusal plane, so the dentition at the focal trough could be viewed. Then the entire view was remapped by clicking on the "creating focal through" button. The points chosen as creating the focal through included the lateral border continuous with the end of the condyle, the condyle, the molar, the right cuspid, the midline, the left cuspid, the left molar, the condyle, and

the end on the other side at the border. The condyles were double checked within the focal point by moving the red horizontal line indicator. The contrast and brightness were adjusted to improve the anatomy. Using the panoramic radiograph generated from the 3D, the following were measured: condylar height, ramus height, body of the mandibular vertical height. To complete this step, the first horizontal line was drawn bisecting the lowest part of the sigmoid notch from the right side to the left side. At the line at the highest part of the condylar process, a vertical line to the line was dropped and constructed before bisecting the 2 sigmoid notches (a = condylar process). Then from the lowest part of the sigmoid notch, a vertical line was dropped on each side ending at the border of the mandible (b=ramus height). The apex of the mesial root of the second molar was located, and a line was drawn in the same plane axis of the tooth angulation to the lower border of the mandibular body (c= body of the mandible vertical height). The right and left side measurements were treated similarly.

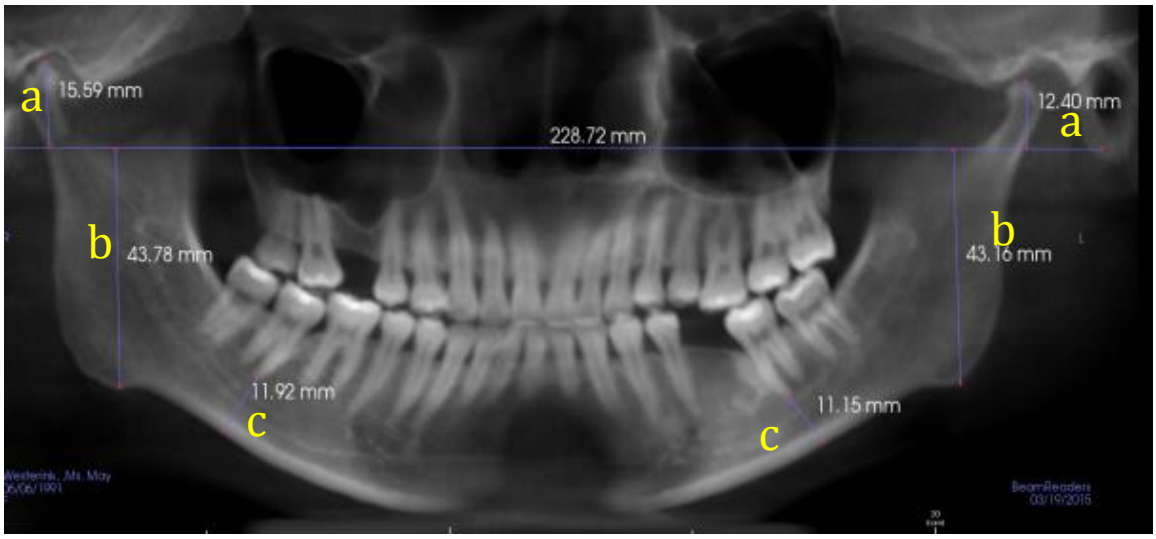

Figure 8: The different measurements from a CBCT generated panoramic view in which the linear measurements are anatomically accurate (a = condylar process, b=ramus height, c= body of the mandible vertical height)

Using Anatomage Invivo5, sagittal slices were taken through the middle of the root canal, at the midpoint of the long axis of the right central incisor, with the assumption that the bony support of the left and right central incisor should be the same (Figure 9).[23]

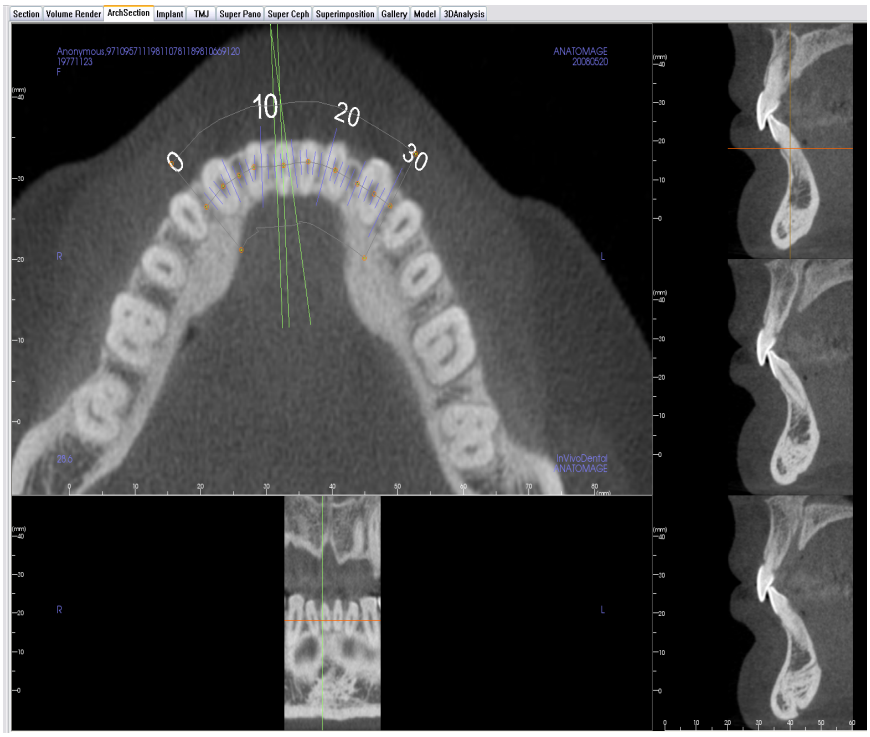

Figure 9: Horizontal view through the mandibular dentition indicating the location of the sagittal slices to evaluate the alveolar bone and teeth. The slice through the center of the root canal (middle slice on the right) is then used for measurement of the tooth and surround bony support.

From the sagittal slice of the center of the incisor, measurements were taken as shown below (Figure 10).

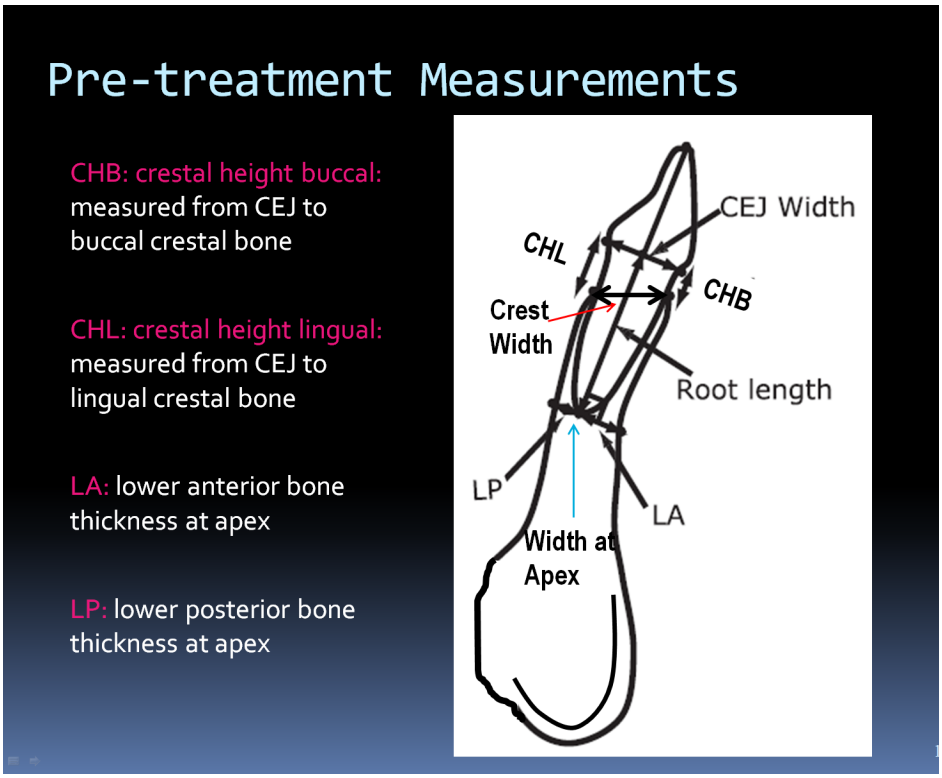

Figure 10: Schematic of measurements taken through the sagittal view of the tooth and mandibular alveolar bone. **CHB**: crestal height buccal, measured from CEJ to buccal crestal bone. **CHL**: crestal height lingual, measured from CEJ to lingual crestal bone. **LA**: lower anterior bone thickness at apex. **LP**: lower posterior bone thickness at apex. **Crest Width**: the width of the alveolar bone from buccal crestal bone to lingual crestal bone. **CEJ Width**: the width of the CEJ. **Root Length**: measured from incisal tip to apex of root. **Width at Apex**: width of the alveolar bone at the apex of the tooth, perpendicular to the long axis of the tooth.[23]

Measurement of Airway Volume and Smallest Cross-sectional Area

Using 3DMD Vultus software, each DICOM data was opened. Measurements were done based on Chiang et al's protocol.[18] Once loaded in the software, selection of "radiography" from the drop down menu on the top right was done, and then the "airway" button was chosen. Analysis was started from the lower limit of airway, the base of the valleculae. The mouse curser was place where the initial point needed to be, then the space bar was selected and a dot was placed. To progress up the airway to map it was completed by placing a dot using the space bar. The upper limit of the airway was the horizontal plane off the hard palate. On the lower right

side of the view, the slice depth was set to be 1mm and the step size to 2mm. The investigator had to shape and fit the box created on the airway to match the airway. On the upper right side, the "analysis" tab was selected, then the "update" button. For every step of the measurement, the dimensions of the airway were computed and the smallest cross sectional area was highlighted in red. The total volume of the airway was also mapped.

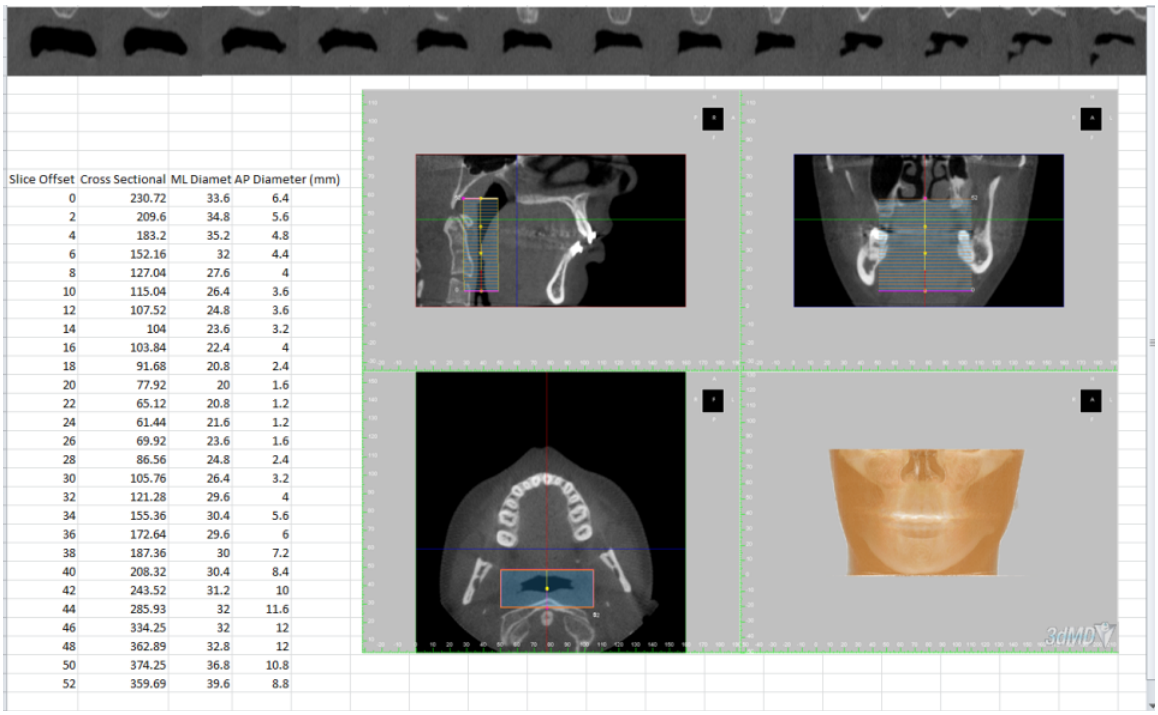

Slice Offset	Cross Sectional	ML Diamet	AP Diameter (mm)
0	230.72	33.6	6.4
2	209.6	34.8	5.6
4	183.2	35.2	4.8
6	152.16	32	4.4
8	127.04	27.6	4
10	115.04	26.4	3.6
12	107.52	24.8	3.6
14	104	23.6	3.2
16	103.84	22.4	4
18	91.68	20.8	2.4
20	77.92	20	1.6
22	65.12	20.8	1.2
24	61.44	21.6	1.2
26	69.92	23.6	1.6
28	86.56	24.8	2.4
30	105.76	26.4	3.2
32	121.28	29.6	4
34	155.36	30.4	5.6
36	172.64	29.6	6
38	187.36	30	7.2
40	208.32	30.4	8.4
42	243.52	31.2	10
44	285.93	32	11.6
46	334.25	32	12
48	362.89	32.8	12
50	374.25	36.8	10.8
52	359.69	39.6	8.8

Figure 11: Example of the airway measurements at each of the axial sections proceeding rostrally.

Statistical Analysis

A Chi-Square test was done and the odds ratio for each category of facial type and gender was calculated. The airway volume and smallest cross-sectional area were compared among the three groups of control subjects divided by vertical facial dimension using single factorial ANOVA using a Bonferroni correction and accepting a $P<0.05$ for level of significance. The same measurements were then compared between the long vertical face subjects' airway volume of smallest cross-sectional area by an unpaired test. A similar approach was completed for the

three mandibular measurements: condylar process, ramus, and body of the mandibular heights and alveolar housing thickness at the apex of lower incisors.

RESULTS

Vertical Facial Dimensions

The total number of subjects was 273 individuals divided into 31 cases subjects (29 female and 2 males) with TMJ pathology and 242 control subjects (169 females and 73 males) with radiographically normal TMJs. In the case group, 26 had long, 4 had normal, and 2 had short vertical facial dimensions. In the control group, 27 had long, 150 had normal, and 65 had short vertical facial dimensions. A Chi-Square test was performed and the odds ratio for each category of facial type and gender was calculated. The odds of having a long face subject within the case group was significantly higher compared to having a long-face subject in control group. 81% of the case group had a long vertical facial dimension versus 11% of the control group indicating a highly statistically significant difference (Table 1).

Table 1. Type Comparison

	Case		Control		OR
Long MP-SN≥39	25	81%	27	11%	34.7
Normal MP-SN 28-39	4	13%	150	62%	ref
Short MP-SN≤ 28	2	6%	65	27%	1.2
Total	**31**		242		
					P < 0.00001
Female	29	94%	169	70%	6.3
Male	2	6%	73	30%	ref
					P = 0.0046

Table 1. Comparison of case and control groups based on facial type and gender with odds ratio

Mandibular Measurements

Mandibular phenotypic characteristics were measured in all categories of facial types in both cases and controls. Comparison between the long facial type in both groups showed that the condylar process, ramus, and mandibular heights were significantly smaller in the case group compared to the control group. Mandibular thickness/alveolar housing mean linear

measurements were smaller in the case group compared to the controls, but the difference was not statistically significant (Table 2).

Table 2. Measurements comparing Cases and Controls long faces			
	Cases	Controls	
	Long N*=25	Long N*=25	P-Value**
Condylar Height	13.6 (3)	16.9 (3.5)	0.0016
Ramus Height	42.5 (4.8)	44.9 (2.6)	0.0161
Mandibular Height	11.6 (2.9)	13.8 (2.7)	0.0041
Mandibular Thickness	6.9 (1.7)	7.5 (1.8)	0.3272
Smallest Section	147.4 (112.8)	186.5 (89.9)	0.0361
Airway Volume	63.7 (56.6)	50.9 (41.9)	0.8009
*All 25 Cases with Long Type and a random sample of 25 from 27 Controls			
**Mann-Whitney Test			

Table 2. Comparison of mandibular phenotypic characteristic and airway measurements between case and control group

Ramus height and mandibular alveolar housing for central incisors were significantly smaller in long face subjects within the control group. Mandibular height was smaller in long face group compared to other groups within the controls. However, the difference was not statistically significant. There was no statistically significant difference of condylar process height, airway volume and airway smallest cross-sectional area within the control group (Table 3).

Table 3. Measurements By Facial Type in Control Group*				
	Short N*=65	Normal N*=150	Long N*=27	P-Value**
Condylar Height	16.0 (2.5)	16.0 (2.4)	16.9 (3.5)	0.6631
Ramus Height	50.5 (5.2)	45.3 (3.4)	44.9 (2.6)	<.0001
Mandibular Height	15.1 (3.7)	12.9 (2.1)	13.8 (2.7)	0.0737
Mandibular Thickness	8.8 (1.7)	7.2 (1.6)	7.5 (1.8)	0.007
Smallest Section	207.6 (175.2)	192.6 (105.9)	186.5 (89.9)	0.9442
Airway Volume	72 (59.6)	42 (41.6)	50.9 (41.9)	0.2078
*Measurements based on random sample of 25 from each group				
**Kruskal—Wallis Test				

Table 3. Comparison of mandibular phenotypic characteristic and airway measurements between different facial types in the control group

Airway Measurements

The smallest cross sectional area of the airway of the cases was significantly narrower compared to controls, however, there was no difference in airway volume. (Figure 12)

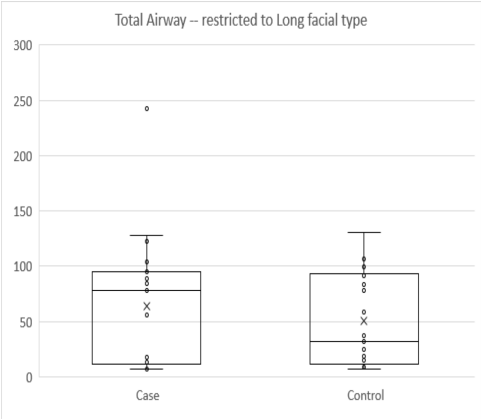

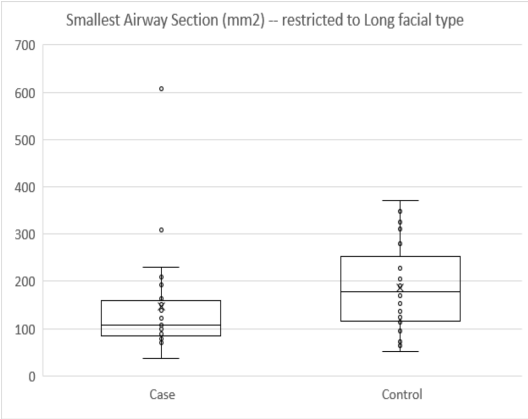

Figure 12: Comparison of airway measurements between long facial type in cases and control group. A. Total airway volume. B. Airway smallest cross- sectional area

There was a considerable trend in reduction of the airway smallest cross sectional area and volume, as the facial type got longer within the control group. However, this was not statistically significant due to large standard deviations (Figure 13).

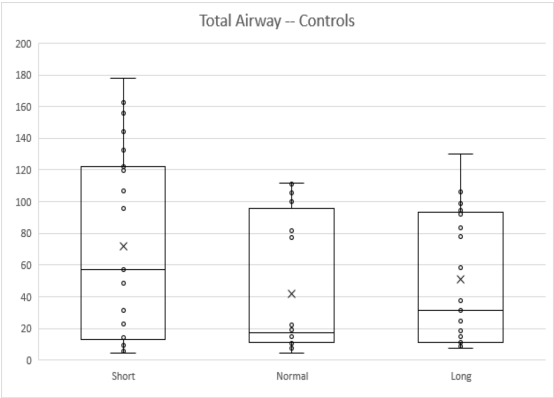

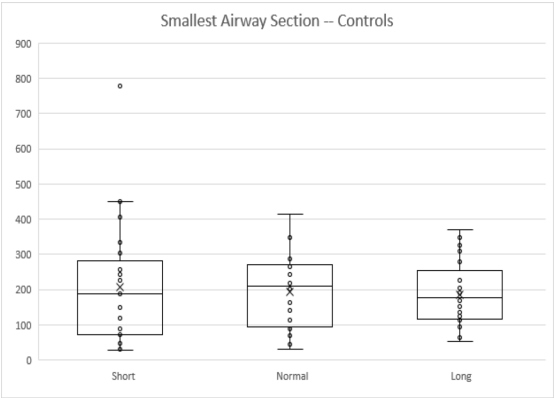

Figure 13: Airway measurements in the control group between different facial types. A. The total airway volume. B. Airway smallest cross sectional area.

DISCUSSION

In this study, the prevalence of long face was evaluated between the case and control groups. In the case group, 81% had long vertical face dimensions whereas control group, had11% of long vertical face dimensions. This clearly indicated that with a history of a radiographically interpreted degenerative or inflammatory disorder and fracture, individuals are more prone to developing a long facial growth pattern. Chi-square test showed the odds of having a long face was significantly higher when there was a history of radiographic degenerative disorder of the TMJ, inflammatory disorder of the TMJ or condylar fracture and/or fracture.

Previously, studies of facial growth using metallic implants demonstrated that the most common direction of condylar growth is vertical with some anterior component (upward and forward) and posterior growth is less frequent. Individuals with "long face syndrome" showed pronounced increase in lower anterior face height and have a more posteriorly directed growth pattern of the mandibular condyle.[24, 25] However, the status of the TMJ was not assessed. Therefore, it was unclear if developing a long face was a result of an inherited growth pattern or result of TMJ disorder.

In this study, there were more female subjects than males. Of the 273 subjects, 94% of cases and 70% of controls were females and 6% of cases and 30% of controls were males. Previous studies assessing gender differences in TMJ disc displacement (DD) status and vertical facial type concluded there is no significantly different dentofacial characteristics, associated with DD, between men and women.[26, 27] Most published studies only include female participants due to the prevalence of TMJ involvement being significantly higher in female individuals[28] and females seeking orthodontic treatment more often than males.[26] In this

study, the odds of females being afflicted with a degenerative disorder or inflammatory disorder are higher than males, taking into account that there were more female subjects than males. Our findings were similar to a study that looked at gender differences in dentofacial characteristics of adult patient with temporomandibular disc displacement. [26]

In this study, mandibular phenotypic characteristics were measured in all categories of facial types in both cases and controls. Only the mean values for long face group of cases and long face group of controls were compared. The height of the condylar process, vertical dimension of ascending rami and body of the mandible are significantly smaller in long face subjects of cases with TMJ radiographic evidence of pathology compared to controls with normal TMJs. The mean thickness of alveolar housing at the anterior region of the mandible was smaller in the cases compared to the controls, but the difference was not statistically significant. (Table 2).

A key anatomic part cannot be segregated or altered without affecting the balance of other parts and their state of physiologic equilibrium. [14] Therefore, the disturbance of condylar growth influences maxillofacial morphology. More specifically, the mandible rotates postero-inferiorly resulting in reduction in over bite, influencing airway dimensions, and jaw shape. It also reduces vertical dimensions of ascending rami and body of the mandible and increases vertical dimension of anterior region of the mandible and reduces thickness of alveolar bone in the anterior region of the mandible. This results in a long face with the some or all of the following characteristics: SN-MP angle ≥ 39 degrees, dolicofacial pattern, skeletal open bite, hyperdivergent: steep mandibular plane, obtuse gonial angle, posteriosuperior growth of the condyle, inferoposterior displacement of the mandible, large vertical dimension and thin AP

dimension of anterior region of the mandible, and higher probability of degenerative or inflammatory disorders. [14]

In this study, the mandibular phenotypic characteristics between different facial types in the control group were compared. Ramus height and mandibular alveolar housing for central incisors were significantly smaller in long face subjects within the control group. (Table 3) The alveolar housing thickness in different facial types was in accordance with previous 2D as well as 3D imaging studies. [23, 29-32] The main difference between hypodivergent and hyperdivergent individuals is the thickness of the labial/buccal and lingual bone plates at the level of root apices in the anterior region of the mandible. [23, 29-32] Within the control group, the mean vertical dimension of the body of the mandible was smaller in long faces relative to other groups within the controls, however the difference was not statistically significant. The condylar process height difference within control group for the different facial types was not significant.

In this study, the airway volume was smaller in the control group, however, this difference was not statistically significant. The smallest cross sectional area of the airway in the case group was significantly smaller compared to that of the controls (Figure 12).

Comparing different facial types in the control groups, there was a considerable trend in reduction of the airway smallest cross sectional area and volume, as the facial type got longer. However, this was not statistically significant due to large standard deviations (Figure 13).

The anteroposterior dimensions of the airway have been shown to have a proportional relationship to jaw growth and facial growth pattern. The airway is largest when there is normal mandibular and maxillary growth and when facial growth pattern occurs with a counter-

clockwise rotation. Conversely, the airway is smaller with deficient maxillary and mandibular growth and when there is a clockwise facial growth pattern. [17, 33]

Because mandibular growth has been linked to condylar growth and degenerative joint disease (DJD, also known as osteoarthritis) affects condylar growth, it is reasonable to postulate that a developmental onset of DJD may limit airway dimensions. The facial phenotype can be secondary to aberrant mandibular growth, which can be associated with alterations in airway dimensions, airway resistance, and functional airway patency.[16]

In this study, an attempt was made to evaluate joint changes as a result of various etiologies and assess secondary adaptational changes on the facial type, mandible and airway. Several acquired TMD or trauma with associated growth disorders manifest similar radiographic and facial characteristics, from the most severe type of Juvenile Idiopathic Arthritis to abnormal position or displacement of the TMJ disc. [10] The results from this study indicate that if there have been degeneration or inflammatory insult or fracture in TMJ, somewhere in the growth cycle, there is a potential for change in facial growth pattern to become more vertical as a consequence of a mandibular adaptation and airway to become narrower, secondarily to TMJ change. This is an acquired change because when condyle size is decreased, the body adapts to the newly changed jaw through modeling and remodeling. Previous studies have indicated, that individuals with TMJ disk displacement have higher percentage of altered skeletal morphology, such as a decreased ramus and posterior facial height and clockwise rotation of the ramus and mandible. [34, 35]

In this study, the mandibular morphologic and airway measurement changes were observed for the selected articular disorders. The individuals in case group of this study had either degenerative disorder such as DJD or PCR, an inflammatory disorder such as JIA, or

condylar fracture. The etiology of these disorders is different, however they all have predilection for females, mostly during growth. However, condylar fractures are more common in males. [14]

Apart from the belief that long face is a result of genetic posterior growth pattern of the condyle[24, 25], more recent studies have shown that individuals with steep mandibular plane and a dolicofacial facial type are at a higher risk of having TMJ disorder and altered skeletal morphology, such as a decreased ramus and posterior facial height and clockwise rotation of the ramus and mandible, regardless of sex. [27, 28, 34, 36]. These skeletal differences become more prominent as TMJ disorder progress in severity.

It is still uncertain whether TMJ disc displacement affects facial morphology or whether altered facial morphology affects TMJ disk displacement. Skeletal Cl II and hypergivergence deformity may cause TMJ disk displacement, while TMJ disk displacement may cause skeletal Cl II and or a hyper divergence deformity.[27] Considering that experimentally induced TMJ disk displacement leads to significant impairment of vertical and horizontal mandibular growth, and the amount of vertical and/or horizontal skeletal change gradually increase as TMJ disc displacement increases in severity, the specific skeletal deformities may be the result of progress in TMJ disc displacement. [37, 38]

Previously, differences in mandibular rest position between normal and high angle cases and patency of the airway often been connected with the “long face syndrome” airway problems, such as large adenoids, tonsils or blocked airways due to septum deviation, large turbinates or allergies are frequently observed in high angle cases and may affect mandibular posture allowing more freedom for posterior eruption.[25] Closing of the mandibular plane angle and reduction in the anterior face height occur following removal of adenoids or tonsillectomy. [39] In addition, alteration from the normal pattern of nasal respiration occurring during active growth can affect

the development of the craniofacial skeleton in humans and experimental animals. [40-43] The compilations of craniofacial and occlusal traits produce a facial phenotype that has been cited in the orthodontic literature as “adenoidal faces,” thus ascribing an etiology and expressing a bias that hypertrophic adenoidal tissues are the cause of an obtunded nasal airflow that results in a specific pattern of craniofacial deformation. [16] However, this facial phenotype may also occur secondary to aberrant mandibular growth. The end result in several craniofacial growth scenarios may be associated with alterations in airway dimensions, airway resistance, and functional airway patency, but the cause-and-effect relationships need to be considered. [16]

CONCLUSIONS

The results of this study suggest that a long facial type is strongly associated with a history of TMJ inflammatory and degenerative disorders or fracture. There are certain skeletal and dentofacial adaptational changes that follow resulting in smaller condylar process, ramus and body of the mandible height, thinner alveolar housing at the lower incisor region and smaller airway cross-sectional area. The results from this study suggest that clinician should carefully monitor the TMJ status in individuals with hyperdivergent facial type.

REFERENCES

1. Opdebeeck, H. and W.H. Bell, *The short face syndrome*. American Journal of Orthodontics, 1978. **73**(5): p. 499-511.
2. Cangialosi, T.J., *Additional criteria for sample division suggested*. American Journal of Orthodontics and Dentofacial Orthopedics, 1989. **96**(2): p. A24.
3. Jr., Girardot, R.A., *Comparison of condylar position in hyperdivergent and hypodivergent facial skeletal types*. Angle Orthod. **71**(240): p. 6.
4. Stringert, H.G, and F.W. Worms., *Variation in skeletal and dental patterns in patients with structural and fucntional alterations of the TMJ*. AJO: p. 285-297.
5. Saccucci, M., et al., *Do skeletal cephalometric characteristics correlate with condylar volume, surface and shape? A 3D analysis*. Head Face Med, 2012. **8**: p. 15.
6. Burke *et al.,, Correlations between condylar charactersitics and facial morphology in Cl II preadolescent patients.* Am J Orthod Dentofacial Orthop 1998. p. 328-36...
7. Park, I.Y., J.H. Kim, and Y.H. Park, *Three-dimensional cone-beam computed tomography based comparison of condylar position and morphology according to the vertical skeletal pattern*. Korean J Orthod, 2015. **45**(2): p. 66-73.
8. Katsavrias; *Morphology of the TMJ in subjects with Cl II Div 2 malocclusion,* Am J Orthod Dentofacial Orthop *2006. p. 470-78..*
9. Custodio W, *et al.. Occlusal force, electromyographic activity of masticatory muscles and mandibular flexure of subjects with different facial types.* J Appl Oral Sci 2011;19:p.343-349..
10. Pirttiniemi, P., et al., *Abnormal mandibular growth and the condylar cartilage*. Eur J Orthod, 2009. **31**(1): p. 1-11.
11. Arnett, G.W., S.B. Milam, and L. Gottesman, *Progressive mandibular retrusion—Idiopathic condylar resorption. Part I*. American Journal of Orthodontics and Dentofacial Orthopedics, 1996. **110**(1): p. 8-15.
12. Arnett, G.W., S.B. Milam, and L. Gottesman, *Progressive mandibular retrusion—idiopathic condylar resorption. Part II*. American Journal of Orthodontics and Dentofacial Orthopedics, 1996. **110**(2): p. 117-127.

13. Krisjane, Z., et al., *The prevalence of TMJ osteoarthritis in asymptomatic patients with dentofacial deformities: a cone-beam CT study*. Int J Oral Maxillofac Surg, 2012. **41**(6): p. 690-5.

14. Tamimi, D.F. and D.C. Hatcher, *Specialty Imaging: Temporomandibular Joint*. 1 ed. Elsevier Publishing, 2016.

15. Grauer, D., et al., *Pharyngeal airway volume and shape from cone-beam computed tomography: relationship to facial morphology*. Am J Orthod Dentofacial Orthop, 2009. **136**(6): p. 805-14.

16. Hatcher, D.C., *Cone beam computed tomography: craniofacial and airway analysis*. Dent Clin North Am, 2012. **56**(2): p. 343-57.

17. Stratemann S., *3D craniofacial imaging: airway and craniofacial morphology* [Unpublished MSc thesis], 2005.

18. Chiang, C.C., et al., *Three-dimensional airway evaluation in 387 subjects from one university orthodontic clinic using cone beam computed tomography*. Angle Orthod, 2012. **82**(6): p. 985-92.

19. Hatcher, D.C., *Progressive Condylar Resorption: Pathologic Processes and Imaging Considerations*. Seminars in Orthodontics, 2013. **19**(2): p. 97-105.

20. Macfarlane, T.V., et al., *Twenty-year cohort study of health gain from orthodontic treatment: temporomandibular disorders*. Am J Orthod Dentofacial Orthop, 2009. **135**(6): p. 692 e1-8; discussion 692-3.

21. Wang, W., T. Hayami, and S. Kapila, *Female hormone receptors are differentially expressed in mouse fibrocartilages*. Osteoarthritis Cartilage, 2009. **17**(5): p. 646-54.

22. Curtis, C., *Evaluating Condylar Head Morphology as it Relates to the Skeletal Vertical Facial Dimension: A Three-Dimensional Semi-Automated Landmark Study*, *in Department of Orofacial Sciences*. 2015, University of California at San Francisco.

23. Huang, N., *Evaluation of Mandibular Anterior Alveolus in Different Skeletal Patterns*, in *Department of Orofacial Science*. 2013, University of California San Francisco.

24. Bjork A, S.V., *Normal and abnormal growth of the mandible. A synthesis of longitudinal cephalometric implant studies over a period of 25 years*. Eur J Orthod. **5**: p. 1-46.

25. Nielsen, I., *Vertical malocclusions: etiology, development, diagnosis and some aspects of treatment*. Angle Orthod. **61**(4): p. 247-260.

26. Kwon, H., Kim H., Jung W., Kim T., Ahn S., *Gender differences in dentofacial characteristics of adult patients with temporomandibular disc displacement*. J Oral Maxillofac Surg, 210. **71**: p. 1178-1186.

27. Jung, W.S., et al., *Magnetic resonance imaging-verified temporomandibular joint disk displacement in relation to sagittal and vertical jaw deformities*. Int J Oral Maxillofac Surg, 2013. **42**(9): p. 1108-15.

28. Nebbe, B., P.W. Major, and N. Prasad, *Female adolescent facial pattern associated with TMJ disk displacement and reduction in disk length: part I*. Am J Orthod Dentofacial Orthop, 1999. **116**(2): p. 168-76.

29. Beckmann, S.H., et al., *Alveolar and skeletal dimensions associated with lower face height*. Am J Orthod Dentofacial Orthop, 1998. **113**(5): p. 498-506.

30. Handelman, C.S. and C.S. Greene, *Progressive/Idiopathic Condylar Resorption: An Orthodontic Perspective*. Seminars in Orthodontics, 2013. **19**(2): p. 55-70.

31. Gracco, A., et al., *Computed tomography evaluation of mandibular incisor bony support in untreated patients*. Am J Orthod Dentofacial Orthop, 2010. **138**(2): p. 179-87.

32. Garib, D.G., Yatabe, M. S., Ozawa, T. O., Filho, O. G., *Alveolar bone morphology under the perspective of the computed tomography: defining the biologic limits of tooth movement*. Dental Press J Orthod, 2010. **15**(5): p. 192-205.

33. Cheung, T. and S. Oberoi, *Three dimensional assessment of the pharyngeal airway in individuals with non-syndromic cleft lip and palate*. PLoS One, 2012. **7**(8): p. e43405.

34. Ahn, S.J., T.W. Kim, and D.S. Nahm, *Cephalometric keys to internal derangement of temporomandibular joint in women with Class II malocclusions*. Am J Orthod Dentofacial Orthop, 2004. **126**(4): p. 486-94; discussion 494-5.

35. Ahn, S.J., et al., *Discrimination of internal derangement of temporomandibular joint by lateral cephalometric analysis*. Am J Orthod Dentofacial Orthop, 2006. **130**(3): p. 331-9.

36. Emshoff, R., et al., *Are temporomandibular joint disk displacements without reduction and osteoarthrosis important determinants of mandibular backward positioning and clockwise rotation?* Oral Surg Oral Med Oral Pathol Oral Radiol Endod, 2011. **111**(4): p. 435-41.

37. Bryndahl, F., et al., *Bilateral TMJ disk displacement induces mandibular retrognathia*. J Dent Res, 2006. **85**(12): p. 1118-23.

38. Legrell, P.E. and A. Isberg, *Mandibular height asymmetry following experimentally induced temporomandibular joint disk displacement in rabbits*. Oral Surg Oral Med Oral Pathol Oral Radiol Endod, 1998. **86**(3): p. 280-5.

39. Linder-Aronson, S., *[Adenoid vegetation and the effect of adenoidectomy]*. Sven Tandlak Tidskr, 1971. **64**(6): p. 399-415.

40. Woodside, D.G., et al., *Mandibular and maxillary growth after changed mode of breathing*. Am J Orthod Dentofacial Orthop, 1991. **100**(1): p. 1-18.

41. Yamada, T., et al., *Influences of nasal respiratory obstruction on craniofacial growth in young Macaca fuscata monkeys*. Am J Orthod Dentofacial Orthop, 1997. **111**(1): p. 38-43.

42. Solow, B., S. Siersbaek-Nielsen, and E. Greve, *Airway adequacy, head posture, and craniofacial morphology*. Am J Orthod, 1984. **86**(3): p. 214-23.

43. Vargervik, K., et al., *Morphologic response to changes in neuromuscular patterns experimentally induced by altered modes of respiration*. Am J Orthod, 1984. **85**(2): p. 115-24.

Publishing Agreement

It is the policy of the University to encourage the distribution of all theses, dissertations, and manuscripts. Copies of all UCSF theses, dissertations, and manuscripts will be routed to the library via the Graduate Division. The library will make all theses, dissertations, and manuscripts accessible to the public and will preserve these to the best of their abilities, in perpetuity.

Please sign the following statement:

I hereby grant permission to the Graduate Division of the University of California, San Francisco to release copies of my thesis, dissertation, or manuscript to the Campus Library to provide access and preservation, in whole or in part, in perpetuity.

Author Signature _____ Date 6/07/2016