

# UC San Diego

## UC San Diego Previously Published Works

### Title

Portalvein reconstruction with a cadaveric descending thoracic aortic homograft

### Permalink

<https://escholarship.org/uc/item/5fd1t3fh>

### Journal

Journal of Vascular Surgery Cases and Innovative Techniques, 8(2)

### ISSN

2468-4287

### Authors

Gaffey, Ann C  
Zhang, Jason  
Lee, Major K  
et al.

### Publication Date

2022-06-01

### DOI

10.1016/j.jvscit.2022.04.001

Peer reviewed

# Portalvein reconstruction with a cadaveric descending thoracic aortic homograft

Ann C. Gaffey, MD, MS,<sup>a</sup> Jason Zhang, MD,<sup>b</sup> Major K. Lee, MD, PhD,<sup>c</sup> Robert Roses, MD,<sup>d</sup> Benjamin M. Jackson, MD,<sup>d</sup> and Jon G. Quatromoni, MD,<sup>e</sup> La Jolla, CA; Philadelphia, PA; and Cleveland, OH

## ABSTRACT

Improvements in chemoradiotherapy have rendered complex pancreatic cancers involving the portal vein (PV) amenable to resection. PV reconstruction (PVR) is an essential component. Various conduits have been proposed; however, the optimal choice remains unknown. Fourteen patients underwent PVR with a cadaveric descending thoracic aortic homograft from 2014 to 2020. The primary diagnosis was pancreatic cancer. The splenic vein was ligated in seven patients (50%). The 30-day and 3-, 12-, and 24-month primary patency rates were 100%, 86%, 76%, and 76%, respectively. We found a cadaveric descending thoracic aortic homograft is an excellent conduit for PVR, given the optimal size, rapidly availability, favorable risk profile, and absence of harvest site complications. (*J Vasc Surg Cases Innov Tech* 2022;8:294-7.)

**Keywords:** Homograft; Oncologic reconstruction; Portal vein reconstruction

Pancreatic adenocarcinoma is one of the most biologically aggressive neoplasms. Because the pancreatic head is anatomically related to major arteries and veins, in nearly 40% of patients, the cancer will involve one or more vascular structures at the diagnosis.<sup>1,2</sup> The resection of the portal–mesenteric venous axis en bloc during pancreatoduodenectomy (PD) is considered a safe approach in high-volume centers with acceptable morbidity.<sup>3,4</sup>

Vascular reconstruction of the portal confluence is classified into four types. Type 1 involves partial venous excision with direct closure; type 2, partial venous excision using a patch; type 3, segmental resection with primary venovenous anastomosis; and type 4, segmental resection with an interposed venous conduit.<sup>5</sup> The use of an internal jugular vein interposition graft for this purpose was first reported by Cusack et al.<sup>6</sup> Since its first description, this particular surgical technique has been further refined, and other conduits have been used.<sup>7,8</sup> However,

no consensus has been reached regarding the best alternate conduit for portal–mesenteric vein reconstruction in the setting of pancreatic resection for pancreatic cancer.

One alternative option for the conduit is a cadaveric homograft. The use of an aortic homograft represents an obvious advantage compared with prosthetic grafts owing to its low immunogenicity,<sup>9</sup> low thrombogenicity, no known need for long-term anticoagulation therapy, and its large caliber and resistance to kinking and infection. For portal vein (PV) reconstruction (PVR), an aortic homograft provides an excellent size match and is readily available without the need to emergently prepare in another field for cases in which the need for PVR has not been anticipated. In the present study, we have proposed the use of a cryopreserved cadaveric descending thoracic aortic (CDTA) homograft for venous reconstruction of the portal–mesenteric venous axis during PD. The present study was designed to investigate the feasibility of using a CDTA homograft in this setting, its effects on the perioperative outcomes after PD, and postoperative PV patency.

## METHODS

The institutional review board of the Hospital of the University of Pennsylvania approved the present study. We performed a retrospective medical record review of a prospectively maintained oncologic database. The records of all patients who had undergone PVR with a CDTA homograft between 2014 and 2020 were examined. During the study period, a CDTA homograft was the preferred conduit for reconstruction. Patients who had undergone other venous reconstruction techniques such as primary repair, end-to-end primary anastomosis, or patch repair were excluded. (A homograft was not typically used for patch angioplasty; instead, bovine pericardium was used for type 2

---

From the Division of Vascular and Endovascular Surgery, Department of Surgery, University of California, San Diego, La Jolla<sup>a</sup>; the Division of Vascular Surgery and Endovascular Therapy,<sup>b</sup> Division of Gastrointestinal Surgery,<sup>c</sup> and Division of Endocrine and Oncologic Surgery,<sup>d</sup> University of Pennsylvania Health System, Philadelphia; and the Department of Vascular Surgery, Cleveland Clinic, Cleveland.<sup>e</sup>

Author conflict of interest: none.

Correspondence: Ann C. Gaffey, MD, MS, Division Vascular and Endovascular Surgery, Department of Surgery, University of California, San Diego, 9434 Medical Center Dr, Mail Code 7403, La Jolla, CA 92037 (e-mail: [agaffey@health.ucsd.edu](mailto:agaffey@health.ucsd.edu)).

The editors and reviewers of this article have no relevant financial relationships to disclose per the Journal policy that requires reviewers to decline review of any manuscript for which they may have a conflict of interest.

2468-4287

© 2022 The Authors. Published by Elsevier Inc. on behalf of Society for Vascular Surgery. This is an open access article under the CC BY-NC-ND license (<http://creativecommons.org/licenses/by-nc-nd/4.0/>).

<https://doi.org/10.1016/j.jvscit.2022.04.001>

reconstructions.) The demographic and clinical data were reviewed. The outcome measures included technical success (no intraoperative death and patent reconstruction as assessed by Doppler ultrasound), hospital mortality, operative time, early (<30 days) complications, late (>30 days) complications, and primary patency rates.

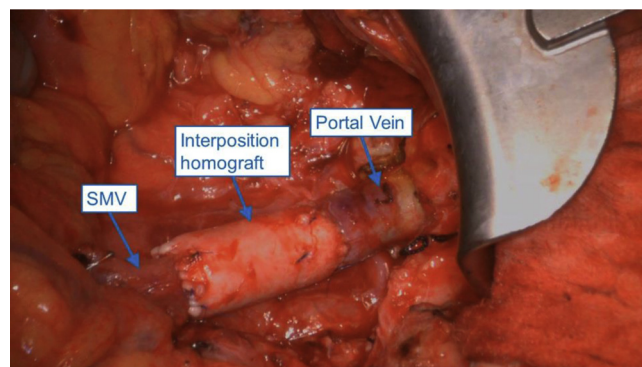
The surgical technique was as follows. After segmental resection of the PV, together with the Whipple specimen, frozen pathologic examination of the proximal and distal ends of the resected vein was performed to ensure that the venous margins were cancer free. The allograft was then cut to the appropriate length. In general, the CDTA homograft ranged from 15 to 18 mm in diameter, with an average CDTA implant of  $17.2 \pm 0.6$  mm when not exposed to arterial pressure. The size of the CDTA homograft matched well with the PV/superior mesenteric vein (SMV) confluence of 11 to 15 mm.<sup>3</sup> The interposition CDTA homograft was anastomosed with running 4-0 Prolene suture (Fig 1). Approximately 50 mL of static blood was exsanguinated to prevent aeroembolism before the last suture.

Unfractionated heparin (5000 U three times daily) was subcutaneously administered after surgery and throughout hospitalization when deemed safe by the oncologic surgery team. Rectal aspirin was administered on postoperative day 1. Once the patients had been cleared for enteral access, oral daily enteric aspirin (81 mg) was started and continued indefinitely. Duplex ultrasound was performed on postoperative day 4 or sooner if concerns existed regarding patency. After the initial hospitalization, the patients were followed up only by the medical and surgical oncologists to reduce the number of office visits. PV graft surveillance was performed using abdominal cross-sectional imaging as deemed appropriate from an oncologic perspective or for other clinical indications (eg, abdominal pain, bowel obstruction).

## RESULTS

A total of 14 patients had undergone PD with PVR using a CDTA homograft. Most of the patients had had an oncologic diagnosis of adenocarcinoma ( $n = 13$ ; 93%), and one patient had had a neuroendocrine tumor. Of the 14 patients, 12 (85%) had received neoadjuvant chemotherapy.

The average age was  $62.6 \pm 7.3$  years, and most patients were women ( $n = 8$ ; 57%). The operative technical success was 100%. Perioperative complications included pancreatic leak ( $n = 1$ ), which was treated by closed suction drainage, and chyle leak ( $n = 1$ ), which had required percutaneous drainage. Neither patient had evidence of an anastomotic pseudoaneurysm on postoperative imaging. In addition, no patient showed symptoms of infection or rejection of the allograft.



**Fig 1.** Portal vein reconstruction (PVR) using a cadaveric descending thoracic aortic (CDTA) homograft. The splenic vein was ligated. SMV, Superior mesenteric vein.

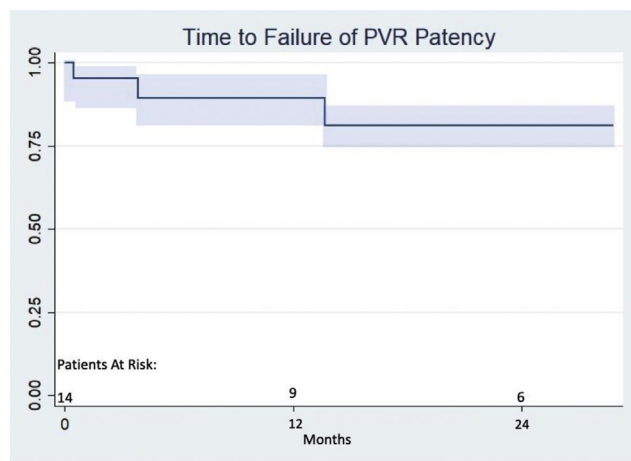
Patency of the PVR at 30 days and 3, 12, and 24 months was 100%, 86%, 76%, and 76%, respectively (Fig 2). No patient had required an additional procedure (eg, PV stenting or catheter-directed thrombolysis) to restore patency. Patency was assessed on computed tomography (CT) scans obtained for staging, surveillance, or other clinical indications (eg, abdominal pain, bowel obstruction).

## DISCUSSION

Resection of a localized segment of the SMV or PV at PD will not significantly increase morbidity and mortality and has been associated with a reasonable prognosis.<sup>10-12</sup> Ideally, these resections will have been anticipated and planned for preoperatively. Nevertheless, the possible need for venous reconstruction might not become apparent until the operation and mobilization of the tumor.

Generally, venous grafting will be necessary if the length of the resected segment is >5 cm. Many conduits used as interposition venous grafts have been described, including an autologous vein graft such as a spiral great saphenous vein,<sup>13</sup> femoral vein,<sup>14</sup> external iliac vein,<sup>15</sup> left renal vein and internal jugular vein,<sup>16</sup> and a synthetic graft.<sup>8</sup> In the present series, we used a portion of the CDTA as an allogeneic (but nonimmunogenic owing to the sterilization processes) conduit to restore PV/SMV continuity.

Like prosthetic grafts, a CDTA homograft does not require harvesting during the surgery and can be selected to match the size of the mesenteric veins. However, a CDTA homograft will, theoretically, be superior to a prosthetic graft in regard to infectious concerns, which is relevant given the proximity to biliary, pancreatic, and intestinal anastomoses. With the high incidence (11.6%-64.3%) of pancreatic fistulas after PD and the possible occurrence of a biliary or an intestinal leak, efforts to mitigate the risk of prosthetic infection are warranted.<sup>7</sup> Furthermore, although the literature on conduit patency after PVR is sparse, the best data currently available have



**Fig 2.** Cumulative portal vein (PV) patency (Kaplan-Meier curve) after reconstruction using a cadaveric descending thoracic aorta (CDTA) homograft. PVR, Portal vein reconstruction.

suggested that a prosthetic conduit is a risk factor for PV thrombosis after pancreatic resection.<sup>15</sup>

Compared with autologous conduits, the CDTA homograft has neither the additional associated morbidity of an additional incision nor the additional time required for conduit harvest. The latter is an important consideration given data suggesting that a longer operative time is an independent risk factor for postoperative PV thrombosis.<sup>7</sup> Also if PV/SMV reconstruction has not been planned, the potential donor sites will often not have been prepared and included in the surgical field. In addition, unexpected operative events (including bleeding from the mesenteric veins during dissection or resection) can, at times, require clamping of the PV and its branches. In such cases, the intestines can become ischemic and edematous while the autologous conduit is harvested. Also, compared with synthetic grafts, the CDTA homograft closely matches the PV in terms of its diameter and thickness. Additionally, the use of a CDTA homograft does not require long-term anticoagulation therapy, which has been recommended for synthetic grafts.<sup>17</sup> One potential obstacle for the use of the CDTA homograft is the associated cost of ~\$6400 per graft. However, we believe that the reduction in the associated morbidity from a second incision will offset the cost of the graft.

The present study had several limitations. The most notable was the lack of a temporal comparison group of patients who had undergone PD without PVR. We plan to investigate this comparison in a future study. Furthermore, we believe that the use of preoperative CT is helpful to predict the possibility of PV involvement. However, owing to the loss of the fat plane and compression of the PV/SMV confluence, we have not found that measurement of the preoperative PV will accurately

represent the true lumen size. Finally, we did not ensure ABO compatibility between the CDTA and recipient owing to the lack of antigenicity in the grafts.<sup>9</sup> However, a lack of ABO compatibility COULD lead to early graft failure and requires further elucidation.

Overall, the use of the CDTA homograft in the present study achieved satisfactory long-term patency. The finding of PV thrombosis uniformly correlated with disease progression. Given that independent duplex ultrasound or CT venography imaging studies were not obtained for these patients, the finding of PV thrombosis was incidental on a CT scan obtained because of small bowel obstruction ( $n = 2$ ) or gastric outlet obstruction ( $n = 1$ ). With the progression of disease, we did not believe that intervention of the thrombosed PV would result in improvement of symptoms. The technique performed did not add the associated morbidity of another incision nor the potential risks of prolonged bowel ischemia and edema during the harvest of an autologous vein graft. As shown by our results, the use of a CDTA homograft offered an “off the shelf” (~20-minute preparation time) conduit for venous grafting in complex PD cases.

In clinical practice, venous interposition grafting after segmental resection of the PV remains a small part of all vascular reconstructions. It is, however, crucial to enabling PD in selected cases. The long-term outcomes still require a detailed evaluation. Our results have shown that the use of a CDTA homograft is a viable option for intraoperative reconstruction of the PV.

## CONCLUSIONS

Reconstruction of the PV after PD can be performed safely and effectively and has been performed with increasing frequency given the improved outcomes after neoadjuvant therapy. The ideal conduit remains unclear; however, the benefit of using a CDTA conduit, given its off-the-shelf availability, appropriate size, and resistance to infection, is an attractive option. The results of the present study have shown that PVR can be performed safely with a CDTA homograft.

## REFERENCES

1. Garces-Descovich A, Beker K, Jaramillo-Cardoso A, James Moser A, Mortelet KJ. Applicability of current NCCN Guidelines for pancreatic adenocarcinoma resectability: analysis and pitfalls. *Abdom Radiol* 2018;43:314-22.
2. Gilbert JW, Wolpin B, Clancy T, Wang J, Mamon H, Shinagare AB, et al. Borderline resectable pancreatic cancer: conceptual evolution and current approach to image-based classification. *Ann Oncol* 2017;28:2067.
3. Morelli L, Berchiolli R, Cuadagni S, Palmeri M, Furbetta N, Gianardi D, et al. Pancreatoduodenectomy without vascular resection in patients with primary resectable adenocarcinoma and unilateral venous contact: a matched case study. *Gastroenterol Res Pract* 2018;2018:1081494.
4. Renikumar R, Sabin C, Hilal MA, Bramhall S, White S, Wigmore S, et al. Portal vein resection in borderline resectable pancreatic cancer: a United Kingdom multicenter study. *J Am Coll Surg* 2014;218:401-11.

5. Bockhorn M, Uunoglu FG, Adham M, Imrie C, Milicevic M, Sandbery AA, et al. Borderline resectable pancreatic cancer: a consensus statement by the international study group of pancreatic surgery (ISGPS). *Surgery* 2014;155:977-88.
6. Cusack JC Jr, Fuhrman GM, Lee JE, Evans DB. Managing unsuspected tumor invasion of the superior mesenteric-portal venous confluence during pancreaticoduodenectomy. *Am J Surg* 1994;168:352-4.
7. Dardik H, Shander A, Dardik S, Silvestri F, Ciervo A, Benotti PN. Portal mesenteric shunting for reconstruction of the visceral venous system. *J Am Coll Surg* 2000;191:469-73.
8. Leon LR, Hughes JD, Psalms SB, Guerra R, Biswas A, Prasad A, et al. Portomesenteric reconstruction during Whipple procedures: review and report of a case. *Vasc Endovascular Surg* 2008;41:537-46.
9. L'Italien GJ, Maloney RD, Abbott WM. The preservation of the mechanical properties of venous allografts by freezing. *J Surg Res* 1979;27:239-43.
10. Selvaggi F, Mascetta G, Daskalaki D, Molin M, Salvia R, Buttirini G, et al. Outcome of superior mesenteric-portal vein resection during pancreatotomy for borderline ductal adenocarcinoma: results of a prospective comparative study. *Langenbecks Arch Surg* 2014;399: 659-65.
11. Takahashi S, Ogata Y, Tsuzuki T. Combined resection of the pancreas and portal vein for pancreatic cancer. *Br J Surg* 1994;81:1190-3.
12. Harrison LE, Klimstra DS, Brennan MF. Isolated portal vein involvement in pancreatic adenocarcinoma: a contraindication for resection? *Ann Surg* 1996;224:342-9.
13. Doty DB, Baker WH. Bypass of superior vena cava with spiral vein graft. *Ann Thorac Surg* 1976;22:490-3.
14. Sigel B, Bassett JC, Cooper DR, Dunn MR. Resection of the superior mesenteric vein and replacement with a venous autograft during pancreaticoduodenectomy: case report. *Ann Surg* 1965;162:941-5.
15. Kaneoka Y, Yamaguchi A, Isogai M, Suzuki M. Longer than 3-year survival following hepato-ligamto-pancreatoduodenectomy for hilar cholangiocarcinoma with vascular involvement: report of a case. *Surg Today* 2003;33:772-6.
16. Fuhrman GM, Leach SD, Staley CA, Cusack JC, Charnsangavej C, Cleary KR, et al. Rationale for en bloc vein resection in the treatment of pancreatic adenocarcinoma adherent to the superior mesenteric-portal vein confluence. Pancreatic Tumor Study Group. *Ann Surg* 1996;223:154-62.
17. Masmajan S, Deslarzes-Dubuis C, Petitprez S, Longchamp A, Haller C, Saucy F, et al. Ten year experience of using cryopreserved arterial allografts for distal bypass in critical limb ischaemia. *Eur J Vasc Endovasc Surg* 2019;57:823-31.

Submitted Jan 6, 2022; accepted Apr 2, 2022.