

# UCLA

## UCLA Previously Published Works

### Title

Masquerading Superior Oblique Palsy.

### Permalink

<https://escholarship.org/uc/item/5454p9ts>

### Authors

Demer, Joseph

Clark, Robert

### Publication Date

2022-10-01

### DOI

10.1016/j.ajo.2022.05.017

Peer reviewed



Published in final edited form as:

*Am J Ophthalmol.* 2022 October ; 242: 197–208. doi:10.1016/j.ajo.2022.05.017.

## Masquerading Superior Oblique Palsy

Joseph L. Demer, M.D., Ph.D.<sup>1,2,3,4</sup>, Robert A. Clark, M.D.<sup>1</sup>

<sup>1</sup>Department of Ophthalmology, University of California, Los Angeles.

<sup>2</sup>Stein Eye Institute, University of California, Los Angeles.

<sup>3</sup>Bioengineering Department, University of California, Los Angeles.

<sup>4</sup>Department of Neurology, University of California, Los Angeles.

### Abstract

**Purpose:** We evaluated patients with hypertropia compatible with diagnosis of superior oblique (SO) palsy to ascertain if the 3-step test (3ST) can distinguish SO atrophy characteristic of trochlear nerve pathology from masquerading conditions.

**Design:** Prospective cross-sectional study.

**Methods:** In an academic practice, we performed quasi-coronal plane, surface coil magnetic resonance imaging in 83 patients clinically diagnosed with SO palsy. We evaluated alignment, SO cross sectional area, SO contractility, and rectus muscle pulley positions.

**Results:** 57 patients (average age  $39 \pm 21$  years, standard deviation, SD) had unilateral SOP manifested by SO atrophy (22 congenital and 35 acquired). There was normal SO size in 26 (age  $39 \pm 16$  years) considered masquerades (8 congenital and 18 acquired). Maximum palsied SO cross section averaged  $9.5 \pm 3.8 \text{ mm}^2$ , less than  $18.4 \pm 3.9 \text{ mm}^2$  contralaterally ( $P < 10^{-24}$ ). In masquerades, maximum hypertropic SO cross section was  $20.7 \pm 3.1 \text{ mm}^2$ , not different from the hypotropic SO or the contralesional muscle in SO palsy. Head tilt testing in masquerades was indistinguishable from SOP. In SOP, central hypertropia averaged  $13.2 \pm 9.4^\circ$ , increasing to  $21.1 \pm 14.0^\circ$  in ipsilateral tilt, and decreasing to  $4.3 \pm 5.3^\circ$  in contralateral tilt. In masquerades, central HT averaged  $13.1 \pm 8.7^\circ$ , and was  $17.7 \pm 11.1^\circ$  in ipsilateral and decreasing to  $4.9 \pm 5.1^\circ$  in contralateral tilt. Upright hypertropia was larger at  $17.7 \pm 9.9^\circ$  in congenital than  $12.0 \pm 8.4^\circ$  in acquired SOP ( $P = 0.025$ ), but indistinguishable from congenital masquerades. Contractile change in SO cross section was bilaterally similar in masquerades. Relevant coordinates of rectus pulleys were similar bilaterally in masquerades.

**Conclusions:** The 3ST pattern characteristic of unilateral SO palsy may be mimicked in all respects by masquerades.

### Keywords

head tilt testing; hypertropia; magnetic resonance imaging; superior oblique palsy

---

**Address for Correspondence and Reprints** Joseph L. Demer, M.D., Ph.D., Stein Eye Institute, 100 Stein Plaza, UCLA, Los Angeles, California, 90095-7002 U.S.A. Telephone: 310-825-5931. Facsimile: 310-206-7826, jld@jsei.ucla.edu.

**Conflict of Interest:** No conflicting relationship exists for any author.

It is widely stated that superior oblique (SO) palsy<sup>1-4 5,6</sup> is commonest cause of vertical diplopia or cyclovertical muscle paralysis<sup>7</sup>, perhaps because SO palsy has been the default diagnosis in absence of obvious alternative cause of hypertropia. The Parks-Bielschowsky 3-step test (3ST) has been standard for diagnosis of cyclovertical strabismus<sup>8</sup>. A positive 3ST in unilateral SO palsy consists of: 1) ipsilesional central gaze hypertropia, 2) that is greater in contralesional than ipsilesional gaze, 3) and greater in ipsilesional than contralesional head tilt<sup>9-11</sup>. The presumed basis of the 3ST is that unopposed activity of inferior oblique muscle, the palsied SO's antagonist, increases the hypertropia in contralateral gaze<sup>12</sup>. The increase in hypertropia associated with ipsilesional head tilt is supposed to result from deficit of the palsied SO's incycloduction during ocular counter-rolling<sup>10</sup> that is replaced by ipsilateral superior rectus contraction<sup>13,14</sup>. When the 3ST is fulfilled, it has been customary to infer SO weakness, and attribute variable hypertropia incomitance to other changes such as "inferior oblique overaction" and superior rectus contracture<sup>1,15</sup>.

Yet there are problems with diagnosis of SO palsy. Denervation of other extraocular muscles, such as the lateral rectus<sup>16</sup> or any muscles innervated by the oculomotor nerve<sup>17</sup>, rapidly results in corresponding muscle atrophy. Experimental extirpation of the subarachnoid trochlear nerve in monkeys induces striking atrophy of the SO muscle in a matter of weeks<sup>18</sup>. While in humans the absence of the subarachnoid trochlear nerve is strongly correlated with marked hypoplasia of the corresponding SO muscle<sup>19</sup>, about a third of cases of clinically diagnosed congenital SO palsy exhibit neither of these MRI findings<sup>20</sup>. Robust SO contractile force generation has been measured intraoperatively in a muscle diagnosed as palsied by positive 3ST<sup>21</sup>. The magnitude of the third step in the 3ST, comprising the difference in hypertropia between ipsilateral and contralateral head tilt, lacks quantitative relationship to size, and presumably to function, of the SO muscle<sup>22</sup>. Consequently, although the 3ST has been widely employed diagnostically<sup>7,23</sup>, its errors<sup>24</sup> have been recognized in common clinical situations, further contributing to the finding that the 3ST is only 70%<sup>25</sup> to 75% sensitive<sup>14</sup> and 50% specific for actual SO atrophy or hypoplasia<sup>26</sup>. In comparison, the anatomical criterion of volume reduction in ipsilateral SO to 75% or less of contralateral muscle is 99% sensitive and 95% specific for absence of the trochlear nerve in congenital SO palsy<sup>19</sup>.

Computational simulations indicate that displacement of the rectus muscle pulleys can mimic the horizontal and vertical patterns of incomitance caused by unilateral SO weakness<sup>27</sup>. A frequent cause of such pulley displacements is the sagging eye syndrome (SES), a common cause of acquired cyclovertical diplopia in older adults<sup>28-34</sup>. The SES can sometimes replicate the 3ST pattern of unilateral SO palsy, establishing that at least one entity may masquerade as acquired SO palsy (Demer, J. L. and Wei, Q, presented at meeting of American Association for Pediatric Ophthalmology and Strabismus, Scottsdale, AZ, March 24, 2022.).

Etiologic diagnosis of cyclovertical strabismus may have clinical importance for diagnosis and management. In acquired vertical diplopia, it may be clinically important to ascertain if there exists congenital hypoplasia or a structural lesion involving the trochlear nerve, or a disorder of neuromuscular transmission such as ocular myasthenia gravis, or if there even anatomically exists a SO muscle whose function might be surgically augmented. It is notable

that SO muscle abnormality is a feature of congenital fibrosis of the extraocular muscles type 1 (CFEOM1)<sup>35,36</sup>, CFEOM3<sup>37</sup>, DRRS<sup>38</sup>, and dominant Duane syndrome<sup>39</sup>. Congenital SO palsy is now suggested, at least in some cases, to represent a congenital cranial dysinnervation disorder<sup>40</sup>, and a gain of function mutation in a mouse model is associated with abnormal trochlear nerve projection and branching<sup>41</sup>. This suggests that some cases diagnosed as SO palsy might involve nerve misdirection to the SO or other muscles. To understand the pathophysiology and genetic basis of cyclovertical strabismus, it is important that internal phenotypes be clinically defined, because genetic association studies can be profoundly confounded by phenocopy, the mimicking of external appearance by multiple different causes. It is important to define under what conditions clinical information can reliably indicate the phenotype of a cranial nerve disorder that weakens contraction of the SO muscle, which is the explicit meaning of the terms “SO palsy” and “trochlear palsy.”

The present study aimed to clarify conditions that may masquerade as unilateral SO palsy by correlating clinical examination findings with the endophenotype of the extraocular muscles demonstrated by high resolution magnetic resonance imaging (MRI). Atrophy of the ipsilateral SO muscle belly was considered a reliable and objective feature confirming unilateral SO palsy since experimental neurectomy of the subarachnoid trochlear nerve in monkey rapidly produces atrophy of the SO belly<sup>18</sup>, humans with unilateral SO palsy exhibit reduced SO size and loss of contractile thickening in infraduction<sup>42</sup>, and marked SO hypoplasia correlates strongly with absence of the trochlear nerve<sup>19</sup>. Since abnormalities of rectus pulley positions can cause incomitant strabismus similar to SO palsy (such as in sagging eye syndrome), MRI was also used to determine if masquerading is attributable to abnormal pulleys.

## METHODS

The University of California, Los Angeles, Institutional Review Board has continuously approved this prospective observational study of strabismus since 1989. Written informed consent from subjects was obtained prior to participation. As described elsewhere,<sup>43</sup> this study has recruited strabismic patients for testing of ocular motility and surface coil MRI of the orbits. We considered data from all participants with complete alignment measurements supporting the clinical diagnosis of unilateral SO palsy, and had undergone digitally-stored, quasi-coronal plane MRI of each orbit imaged separately using surface coils, during target fixation by the scanned eye. We excluded patients who had previously undergone strabismus, retinal, glaucoma, or orbital surgery or had subnormal vision in either eye, neuromuscular disease, myopathy, dissociated vertical deviation, other cranial nerve palsy, significant horizontal strabismus not typically associated with SO palsy, or other confounding conditions.

All participants were examined by the senior author before MRI was performed. Facial asymmetry was not used as a diagnostic criterion<sup>44</sup>. Patients provided ophthalmological history and underwent examination, including evaluation of ocular versions, as well as measurement of binocular alignment at 4 m distance using prism-cover testing in horizontal and vertical secondary positions, as well as right and left lateral head tilt. Prism-cover measurements reported here represent maxima revealed through alternate cover testing.

Consistent with prior studies, misalignment of at least 12° were considered significant<sup>14,25</sup>. Torsion was measured as the difference in angular orientation of double Maddox rods in central gaze.

Patients were considered to have a congenital strabismus if they either gave unequivocal history of congenital onset of strabismus and head tilt, or could intermittently fuse hypertropia of at least 20° for a distance target, constituting ten-fold maximum normal vertical fusional vergence<sup>45</sup>. Other cases were considered to have acquired strabismus.

After clinical examination, high resolution MRI was performed using investigational surface coils by the senior author, as elsewhere described<sup>43</sup>. Each orbit was imaged separately as published<sup>42,46-48</sup>. Imaging with T1 or T2-weighted sequences was in 2 mm thick, contiguous quasi-coronal planes perpendicular to the long axis of the orbit using an 80 mm square field of view and 256 x 256 matrix yielding 312 micron in-plane resolution. Patients monocularly fixated a target centered for each separately scanned eye. Imaging was performed supine in most patients, but in both right and left lateral decubitus in a minority. Although the functional effect of decubitus counter-rolling is negligible compared with SO palsy<sup>27,42,49-51</sup>, ipsilateral decubitus causes slight SO contraction and decubitus slight relaxation<sup>52</sup>. Data for both decubitus positions was averaged. Participants able to undergo additional MRI were also imaged supine in target-controlled maximal supraduction and infraduction to assess SO contractile changes.

The MRI images were analyzed using the program *Fiji*<sup>53</sup>. Cross sectional area of the SO in the acquired plane was automatically determined after manual outlining using a digital cursor, and the maximum value was recorded for each orbit. Rectus muscle path centroids were determined automatically after manually outlining muscle cross sections by an examiner masked to laterality of the hypertropia. Rectus paths were plotted in an oculocentric coordinate system as published for determination of pulley positions<sup>54</sup>.

In this paper, the term “atrophy” encompasses possible congenital hypoplasia. The presence of unilateral SO palsy was considered confirmed by demonstration of unilateral SO atrophy evidenced by reduction in maximum cross sectional area in quasi-coronal MRI. Atrophy was confirmed by examination of additional images anterior and posterior to the plane of maximum cross section. Figure 1A illustrates the MRI appearance of this unilateral right SO hypoplasia in the case of a 15 year old female with congenital right SO palsy; the left SO is normal (Fig. 1B). Prism-cover measurements in Fig. 1C demonstrate an unequivocally positive 3ST. The strikingly small right SO in Fig. 1A may be contrasted with the bilaterally normal SO muscles in the 15 year old male with congenital right hypertropia whose MRI appears in Fig. 1D and 1E, and whose alignment measurements in Fig. 1F. Note that the central gaze hypertropia is identically 12° for these age-matched patients, and that the HT for both readily fulfills the 3ST. The patient in Fig. 1D-F is considered to have masquerading right SO palsy. Although hypoplasia of the SO is so profound in Fig. 1A as to require no quantitative evidence of SO palsy, the ratio of maximum SO cross section in the hypertropic to the hypotropic orbit was used as the criterion for discrimination of SO palsy from masquerade. Cases in which maximum hypertropic SO cross section was less than 80%

of the hypotropic SO were considered to represent SO palsy, and the other cases to be masquerades.

Parametric statistical analysis was performed using Microsoft Excel, with computation of 95% confidence intervals (CIs) for means based on the normal distribution. Statistical comparisons employed paired and unpaired, two-sided Student t-testing.

## RESULTS

### Classification.

A total of 83 patients qualified for inclusion. Of these, 57 (average age  $39 \pm 21$  years, standard deviation, SD) were classified as unilateral SO palsy because maximum hypertropic SO cross section orbit was less than 80% of the fellow SO. This area ratio, which provided non-overlapping discrimination of all SO palsy from masquerade cases, is similar to the value of 75% for SO volume reported by Yang et al. as providing 99% sensitivity and 95% specificity for trochlear nerve absence in congenital SO palsy<sup>19</sup>. Of the current cases of SO palsy, 22 were congenital and 35 acquired. As seen in Figure 2, the ratio of ipsilateral to contralateral SO cross sections averaged  $0.52 \pm 0.18$  (CI 0.47–0.56) for all SO palsy cases, and  $1.06 \pm 0.12$  (CI 1.02–1.11) for all masquerade cases ( $P < 10^{-22}$ ). Corresponding ratios for subgroups of congenital cases were  $0.43 \pm 0.19$  (CI 0.35–0.51) for SO palsy and  $1.03 \pm 0.10$  for masquerade (CI 0.96–0.11,  $P < 10^{-25}$ ), and in acquired cases  $0.57 \pm 0.14$  (CI 0.52–0.61) of SO palsy and  $1.06 \pm 0.13$  in acquired masquerades (CI 1.00–1.12,  $P < 10^{-31}$ ). Masquerading cases were thus robustly distinguishable from both congenital and acquired SO palsy based on relative SO size.

### Size of the SO Muscle.

Data on absolute SO cross sections, rather than ratio, are summarized in Fig. 3. For the unaffected hypotropic SO contralateral to SO palsy, mean maximum cross section was  $18.9 \pm 3.9$  (CI 17.6–20.2)  $\text{mm}^2$  in acquired, not significantly different from  $17.9 \pm 3.6$   $\text{mm}^2$  in congenital SO palsy (CI 16.4–19.4,  $P = 0.307$ ). Mean maximum cross section of the hypertropic SO was significantly lower at  $10.7 \pm 3.5$   $\text{mm}^2$  in acquired (CI 9.6–11.9,  $P < 10^{-16}$ ) and  $7.7 \pm 3.8$   $\text{mm}^2$  in congenital (CI 6.1–0.3,  $P < 10^{-9}$ ) SO palsy, although the former was significantly larger than the latter ( $P = 0.003$ ). Pooling all 57 cases, maximum cross section of the palsied SO averaged  $9.5 \pm 3.8$  (CI 8.5–10.5)  $\text{mm}^2$ , significantly less than  $18.4 \pm 3.9$   $\text{mm}^2$  contralaterally (CI 17.4–19.4,  $P < 10^{-24}$ ).

In masquerades, mean maximum hypertropic SO cross section was not significantly different from the hypotropic SO, neither in the overall group, nor in congenital or acquired subgroups ( $P > 0.25$ , Fig. 3). The trend for larger maximum SO cross section in acquired than congenital masquerades was insignificant ( $P > 0.07$ ). Overall, maximum SO cross section was highly significantly reduced in hypertropic orbits in both acquired and congenital SO palsy, but not reduced at all in fellow hypotropic orbits, nor in either orbit in either acquired or congenital masquerades.

### Contractility of the SO Muscle.

Multipositional MRI in eccentric vertical gazes was performed only in masquerades because it has already well established that SO hypoplasia is strongly correlated with diminished contractility<sup>42</sup>. The increase in maximum cross section from supraduction to infraduction quantified SO contractility. In all 14 masquerade patients in whom MRI was performed in both supraduction and infraduction, maximum hypertropic SO cross section increased  $3.8 \pm 8.7 \text{ mm}^2$ , not significantly different from  $4.9 \pm 4.1 \text{ mm}^2$  of the hypotropic SO ( $P = 0.675$ ), Fig. 4). This similarity was also evident when masquerades were subdivided into 8 acquired and 4 congenital cases (Fig. 4). Thus, SO contractility was similarly present in both orbits of masquerade cases.

### Prism-cover Hypertropia in Central Gaze.

The first step in the 3ST is demonstration of ipsilesional hypertropia, which averaged  $14.2 \pm 9.3$  for all cases of SO palsy, subdivided into  $17.7 \pm 9.9$  in congenital, and  $12.0 \pm 8.4$  in acquired SO palsy. Ipsilesional hypertropia averaged  $13.1 \pm 8.7$  in the pooled group of masquerades, not significantly different from the pooled average in SO palsy ( $P = 0.609$ , Fig. 5). Ipsilesional hypertropia in central gaze averaged  $17.3 \pm 8.8$  in congenital and  $11.2 \pm 8.3$  in acquired masquerades, neither of which differed significantly from comparable groups with SO palsy ( $P > 0.1$ ).

### Lateral Gaze Incomitance.

A positive second step in the 3ST requires that hypertropia in contralateral gaze exceed that ipsilateral horizontal version. As evident from Fig. 5, in both SO palsy and masquerades, mean hypertropia in both lateral versions fulfilled the second step and was similar in both groups. In the pooled group with SO palsy, hypertropia increased from  $7.9 \pm 8.7$  in ipsilateral version to  $21.7 \pm 11.7$  in contralateral version (Fig. 5). In the pooled group of masquerades, mean hypertropia increased from  $8.3 \pm 6.6$  in ipsilateral version to  $18.2 \pm 10.3$  in contralateral version (Fig. 5). The foregoing values did not differ significantly between groups ( $P > 0.2$ ). In congenital SO palsy, hypertropia increased from  $9.5 \pm 7.8$  in ipsilateral version to  $27.9 \pm 10.4$  in contralateral version; while corresponding values in acquired SO palsy were  $6.9 \pm 9.1$  and  $17.9 \pm 10.9$ , respectively. Contralesional hypertropia was significantly greater in congenital than acquired SO palsy ( $P = 0.002$ ). In congenital masquerades, hypertropia increased from  $12.3 \pm 5.8$  in ipsilateral version to  $23.5 \pm 11.8$  in contralateral version; corresponding values in acquired masquerades were  $8.3 \pm 6.6$  and  $17.2 \pm 10.3$ , respectively. None of these values for the masquerades differed significantly from SO palsy ( $P > 0.4$ ).

### Vertical Gaze Incomitance.

While not a component of the 3ST, hypertropia due to SO weakness would be expected to increase in downward gaze since the SO is an infraductor. As evident from Fig. 6, mean hypertropia in down gaze was significantly larger in the overall group with SO palsy at  $14.7 \pm 11.6$  (CI 11.6-17.8) than in the overall group of masquerades at  $9.2 \pm 9.1$  (CI 5.6-12.7,  $P = 0.036$ ). However, when considering only acquired cases, this difference was



insignificant, as mean hypertropia in down gaze was in  $13.6\pm 9.6$  in SO palsy and  $8.3\pm 9.4$  in acquired masquerades ( $P=0.061$ ).

### Head Tilt Testing.

Figure 7 illustrates results of head tilt testing in pooled groups of SO palsy and masquerades. For contralesional tilt in SO palsy, hypertropia was  $4.3\pm 5.3$ , increasing to  $21.1\pm 14.0$  in ipsilesional tilt. For contralesional tilt in SO masquerades, hypertropia was  $4.9\pm 5.1$ , increasing to  $17.7\pm 11.1$  in ipsilesional tilt. These values did not differ significantly between pooled groups of SO palsy and masquerades, nor did corresponding hypertropia values differ significantly between congenital vs. acquired subgroups ( $P>0.26$  for both comparisons). Mean differences in hypertropia associated with head tilt were in the 10-20 range, and are plotted in Fig. 8. Although individual differences ranged widely, these differences did not significantly vary among acquired vs. congenital cases of SO palsy nor masquerade. ( $P>0.3$ )

### Torsion.

Excyclotropia measured using double Maddox rods averaged  $6.5\pm 4.7^\circ$  in the pooled group with SO palsy, not significantly different from  $7.2\pm 4.3^\circ$  in masquerades ( $P=0.549$ ). In congenital cases, excyclotropia was  $5.2\pm 3.0^\circ$  in SO palsy, and  $7.3\pm 4.8^\circ$  in masquerades. In acquired cases, excyclotropia was  $7.1\pm 5.3^\circ$  in SO palsy, and  $7.1\pm 4.2^\circ$  in masquerades. There were no significant differences in torsion for subgroup comparisons ( $P>0.2$ ).

### Rectus Pulley Positions.

Rectus pulley positions for masquerade cases are plotted separately for the hyper- and hypotropic orbits in Fig. 9, shown in gray ovals with the published 95% bivariate confidence limits for mean normal pulley positions obtained using identical technique<sup>54</sup>. Kinematically relevant pulley displacement in this analysis are vertical for the horizontal pulleys and horizontal for the vertical pulleys. While in masquerades most medial rectus pulleys lie superior to average normal position and LR pulleys inferior to normal, mean kinematically relevant positions for corresponding pulleys were statistically identical for the hyper- and hypotropic orbits ( $P>0.3$ ). This excludes asymmetrical pulley sag as the typical cause of masquerading SO palsy in this sample of cases, although it does not exclude this phenomenon as a cause in other cases not included here.

## DISCUSSION

High resolution MRI of 83 patients whose 3ST met classical clinical diagnostic criteria for congenital and acquired unilateral SO palsy showed that, while the majority had an abnormally small ipsilateral SO muscle consistent with SO denervation and thus unequivocal SO weakness, a significant minority of 26 patients (31%) had ipsilateral SO size statistically identical to that in the fellow orbit, a finding inconsistent with SO denervation. In this latter group, there were similar gaze-related contractile changes in SO cross section indicating that SO contractility was similar in the hyper- and hypotropic orbits. As summarized in the Table, every alignment measure was statistically identical to SO palsy in these patients who had bilaterally normal SO muscles, so we regard this latter group of



patients has having “masquerading SO palsy.” The mildly abnormal rectus pulley locations in masquerading cases were statistically symmetrical in both orbits and thus cannot account for the hypertropia in central gaze observed in these patients.

The sagging eye syndrome (SES) is a common cause of acquired hypertropia in older adults in whom asymmetric sag of the lateral rectus pulley results in hypotropia and excyclotropia of the affected eye<sup>28</sup>. The majority of acquired diplopia in adults over age 50 years may be caused by SES<sup>55</sup>. It has recently been reported that hypertropia caused by SES can fulfill the 3ST, and thus also masquerade as SO palsy so effectively that even machine learning cannot always distinguish it perfectly (Demer, J. L. and Wei, Q, presented at meeting of American Association for Pediatric Ophthalmology and Strabismus, Scottsdale, AZ, March 24, 2022.). However, the current cases of masquerading SO palsy reflect little or no contribution from SES, and therefore cannot be attributed to it. First, SES is acquired, and never congenital, so it could not masquerade as congenital SO palsy in any of the 8 such masquerade cases included here. Secondly, the average age of strabismus onset in the acquired masquerade cases was 34 years, well below the minimum for SES that is around 50 years. Thirdly, the mild LR sag observed in the masquerade cases was highly symmetrical (Fig. 9), inconsistent with the asymmetrical sag that causes vertical strabismus in SES.

The current findings concord with the study of Lee *et al.* performed in Korean adults in their mid 20 years of age who were diagnosed with unilateral SO palsy by the 3ST, although unlike the current study 30-40% of their patients had concurrent horizontal strabismus and 6-10% had dissociated vertical deviation<sup>14</sup>. Lee *et al.* correlated SO size with the presence of the subarachnoid trochlear nerve on MRI. The trochlear nerve was present in the 52% of patients in whom on average the SO had normal cross section, but absent in the other 48% who on average had profoundly subnormal SO cross section<sup>14</sup>. The trochlear nerve was absent in all cases of congenital SO palsy. These findings further support the inference that SO hypoplasia or atrophy result from trochlear nerve deficiency. Consistent with Manchandia and Demer’s finding that the 3ST is only 70% sensitive to actual SO atrophy demonstrable by MRI<sup>25</sup>, Lee *et al.* found that the 3ST was fulfilled in only 71-72% of their cases<sup>14</sup>. Although Ivanir and Trobe claimed that in their neuroophthalmology practice, hypertropia at least as great in sursumversion than central gaze was distinctive for congenital rather than acquired SO palsy<sup>56</sup>, in a strabismus practice this finding was more frequent in acquired SO palsy and thus cannot be considered an indicator of congenital onset<sup>43</sup>.

The current study and accumulated published evidence make it clear that the 3ST does not specifically reflect the size or function of the SO muscle, or even the presence versus absence of its trochlear nerve. Abnormalities of the SO tendon, such as “floppiness” or other elongation, have been proposed to account for ineffective oculorotary force transmission to the eye<sup>57,58</sup>. While there is association between SO tendon laxity and SO weakness, there is good reason to believe that tendon laxity is secondary to contractile weakness, rather than its cause. Some 18% of congenital SO palsy may be associated with absence of SO tendon altogether<sup>59</sup>, probably again associated with trochlear nerve agenesis and hypoplasia of the muscle belly. Laxity of the SO tendon is correlated with atrophy of the SO muscle as confirmed by MRI<sup>60</sup>. Moreover, traumatic discontinuity of the SO tendon has been found by MRI to shift SO muscle bulk posteriorly, increasing maximum SO cross section in a manner

not observed here in masquerade cases<sup>61</sup>. Since none of the current masquerade cases had a history of orbital trauma or surgery, it seems implausible that SO tendon elongation might develop as a primary event independent of the status of the muscle belly. It is highly unlikely that these relatively common cases of masquerading SO palsy are due primarily to hypothetical progressive tendon laxity that is not encountered for other extraocular muscles.

If congenital and acquired masquerading SO palsy are not due to an abnormality of the SO muscle or tendon, and the acquired form need not be secondary to a pulley abnormality such as sagging eye syndrome, what might be the etiology of masquerades? The current patients with masquerading SO palsy did not have large angle esotropia, exotropia, or dissociated vertical deviation that could suggest a major contribution from sensorimotor anomalies. An intriguing possibility has been hinted at by Kaeser and Brodsky, who used Duane syndrome as a model to suggest that some cases of Brown syndrome may represent a congenital cranial dysinnervation disorder (CCDD) due to synkinesis in which innervation normally destined for the inferior oblique muscle is misdirected to the SO<sup>40</sup>. Just as motor nerves commonly become misdirected in CCDDs such as congenital fibrosis of the extraocular muscles type 1 (CFEOM1)<sup>35,36</sup>, CFEOM3<sup>37</sup>, DRRS<sup>38</sup>, and dominant Duane syndrome<sup>39</sup>, perhaps some form of motor nerve misdirection might be involved in masquerading SO palsy.

It is a limitation that this study was performed at a single institution and was limited to correlation of clinical binocular alignment with imaging of the structure and function of the SO muscle. This study did not concurrently image both SO and trochlear nerve anatomy, given that their correlative changes are already well established<sup>14</sup>, nor did this study specifically examine the SO tendon and trochlea. The current study was non-invasive and did not include forced duction testing of the SO, given that it is well established that SO tendon laxity occurs in the presence of SO muscle atrophy<sup>60</sup>. However, it is a strength of the study that all alignment measurements and MRI were prospectively performed using the same techniques by the same investigator before MRI was performed, that potentially confounding conditions were carefully excluded, and that although SES can masquerade as SO weakness, MRI excludes the possibility that masquerading cases are caused by SES. Additional investigations into mechanisms of masquerading SO palsy appear warranted.

## Supplementary Material

Refer to Web version on PubMed Central for supplementary material.

## Acknowledgement and Financial Disclosure

a. *Funding/Support*: National Eye Institute Grants EY008313 and EY00331, and an Unrestricted Grant to the UCLA Department of Ophthalmology from Research to Prevent Blindness. The sponsors or funding organizations had no role in the design or conduct of this research.

b. *Financial Disclosures*: Joseph L. Demer: National Eye Institute Grants EY008313, EY029715, and EY00331, and an Unrestricted Grant to the UCLA Department of Ophthalmology from Research to Prevent Blindness.

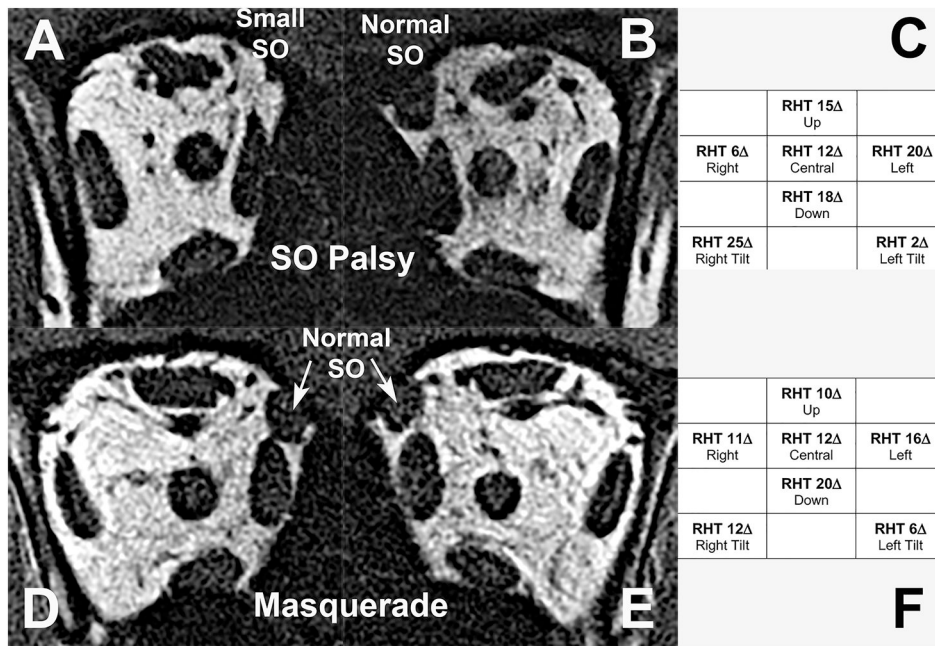
c. *Authorship*: All authors attest that they meet the current ICMJE criteria for authorship.

## REFERENCES

1. Knapp P. Classification and treatment of superior oblique palsy. *Am Orthoptic J.* 1974;24:18–22. [PubMed: 4151473]
2. Ellis FD, Helveston EM. Superior oblique palsy: Diagnosis and classification. *Int. Ophthalmol. Clin* 1976;16:127–135.
3. von Noorden GK, Murray E, Wong SY. Superior oblique paralysis. A review of 270 cases. *Arch. Ophthalmol* 1986;104:1771–1776. [PubMed: 3789976]
4. Chang MY, Coleman AL, Tseng VL, Demer JL. Surgical interventions for vertical strabismus in superior oblique palsy. *Cochrane Database Syst. Rev* Nov 27 2017;11:CD012447. 2017/11/28 10.1002/14651858.CD012447.pub2 [PubMed: 29178265]
5. von Noorden GK. *Binocular Vision and Ocular Motility: Theory and Management of Strabismus.* St. Louis: Mosby; 1996.
6. Plager DA. Superior oblique palsy and superior oblique myokymia. In: Rosenbaum AL, Santiago AP, eds. *Clinical Strabismus Management. Principles and Surgical Techniques.* Philadelphia: Saunders; 1999:219–229.
7. Ophthalmology AAo. Pediatric Ophthalmology and Strabismus. In: Liesgang TJ, Skuta GL, Cantor LR, eds. *Basic and Clinical Science Course. Vol 6.* San Francisco: American Academy of Ophthalmology; 2006:19–22.
8. Plager DA. Superior Oblique Palsy and Superior Oblique Myokymia. In: Rosenbaum AaS AP, ed. *Clinical Strabismus Management. Principles and Surgical Techniques.* Philadelphia, PA: W.B. Saunders Company; 1999:222–223.
9. Bielschowsky A. Lectures on motor anomalies. XI. Etiology, prognosis, and treatment of ocular paralysis. *Am J Ophthalmol.* 1939;22:723–734.
10. Parks MM. Isolated cyclovertical muscle palsy. *A.M.A. archives of ophthalmology.* Dec 1958;60(6):1027–1035. 1958/12/01 [PubMed: 13593934]
11. von Noorden GK, Murray E, Wong SY. Superior oblique paralysis. A review of 270 cases. *Archives of ophthalmology.* 1986;104(12):1771–1776. [PubMed: 3789976]
12. Scott WE, Kraft SP. Classification and surgical treatment of superior oblique palsies: I. Unilateral superior oblique palsies. *Transactions of the New Orleans Academy of Ophthalmology.* 1986;34:15–38. [PubMed: 3726951]
13. Kono R, Okanobu H, Ohtsuki H, Demer JL. Absence of relationship between oblique muscle size and bielschowsky head tilt phenomenon in clinically diagnosed superior oblique palsy. *Invest. Ophthalmol. Vis. Sci* 2009;50(1):175–179. [PubMed: 18791177]
14. Lee JE, Yang HK, Kim JH, Hwang JM. Diagnostic utility of the three-step test according to the presence of the trochlear nerve in superior oblique palsy. *J. Clin. Neurol* Jan 2018;14(1):66–72.s [PubMed: 29629542]
15. Khawam E, Scott AB, Jampolsky A. Acquired superior oblique palsy. Diagnosis and management. *Arch. Ophthalmol* 1967;77:761–768. [PubMed: 6026184]
16. Clark RA, Demer JL. Lateral rectus superior compartment palsy. *Am. J. Ophthalmol* 2014;15(2):479–487.
17. Demer JL. A 12-year, prospective study of extraocular muscle imaging in complex strabismus. *J. AAPOS* 2003;6(6):337–347.
18. Demer JL, Poukens V, Ying H, Shan X, Tian J, Zee DS. Effects of intracranial trochlear neurectomy on the structure of the primate superior oblique muscle. *Invest. Ophthalmol. Vis. Sci* 2010;51(7):3485–3493. [PubMed: 20164458]
19. Yang HK, Lee DS, Kim JH, Hwang JM. Association of superior oblique muscle volumes with the presence or absence of the trochlear nerve on high-resolution MR imaging in congenital superior oblique palsy. *Am. J. Neuroradiol* 2015;36(4):774–778. [PubMed: 25556205]
20. Lee DS, Yang HK, Kim JH, Hwang JM. Morphometry of the trochlear nerve and superior oblique muscle volume in congenital superior oblique palsy. *Invest. Ophthalmol. Vis. Sci* 2014;55(12):8571–8575. [PubMed: 25414184]

21. Simonsz HJ. Force-length recording of eye muscles during local-anesthesia surgery in 32 strabismus patients. *Strabismus*. 1994;2(4):197–218. [PubMed: 21314497]
22. Kono R, Okanobu H, Ohtsuki H, Demer JL. Absence of relationship between oblique muscle size and Bielschowsky head tilt phenomenon in clinically diagnosed superior oblique palsy. *Invest. Ophthalmol. Vis. Sci* 2009;50(1):175–179. [PubMed: 18791177]
23. Dosunmu EO, Hatt SR, Leske DA, Hodge DO, Holmes JM. Incidence and etiology of presumed fourth cranial nerve palsy: A population-based study. *Am. J. Ophthalmol* 2018;185:110–114. [PubMed: 29102606]
24. Kushner BJ. Errors in the three-step test in the diagnosis of vertical strabismus. *Ophthalmology*. 1987;96:127–132.
25. Manchandia A, Demer JL. Sensitivity of the three-step test in diagnosis of superior oblique palsy. *J. AAPOS* 2014;18(6):567–571. [PubMed: 25459202]
26. Demer JL, Clark RA, Kung J. Functional imaging of human extraocular muscles in head tilt dependent hypertropia. *Inv. Ophthalmol. Vis. Sci* 2011;52(6):3023–3031.
27. Suh SY, Le A, Clark RA, Demer JL. Rectus pulley displacements without abnormal oblique contractility explain strabismus in superior oblique palsy. *Ophthalmology*. 2016;123(6):1222–1231. [PubMed: 26983977]
28. Chaudhuri Z, Demer JL. Sagging eye syndrome: Connective tissue involution as a cause of horizontal and vertical strabismus in older patients. *JAMA Ophthalmol*. 2013;131(5):619–625. [PubMed: 23471194]
29. Chaudhuri Z, Demer JL. Long-term surgical outcomes in the sagging eye syndrome. *Strabismus*. 2018;26(1):6–10. [PubMed: 29297726]
30. Chaudhuri Z, Demer JL. Graded vertical rectus tenotomy for small-angle cyclovertical strabismus in sagging eye syndrome. *Br. J. Ophthalmol* 2016;100(5):648–651. [PubMed: 26307450]
31. Kato S, Hayashi Y, Kimura A, Shimohata T. Sagging eye syndrome: A differential diagnosis for diplopia. *Intern. Med* 2020;59(19):2437. [PubMed: 32611964]
32. Kawai M, Goseki T, Ishikawa H, Tatsui S, Shoji N. Standard coronal orbital magnetic resonance imaging is an effective technique for diagnosing sagging eye syndrome. *Graefes Arch. Clin. Exp. Ophthalmol* 2020;258(9):1983–1989. [PubMed: 32377825]
33. Kinori M, Pansara M, Mai DD, Robbins SL, Hesselink JR, Granet DB. Inferior rectus displacement in heavy eye syndrome and sagging eye syndrome. *Graefes Arch. Clin. Exp. Ophthalmol* 2020;258(5):1109–1113. [PubMed: 32095879]
34. Rutar T, Demer JL. “Heavy eye syndrome” in the absence of high myopia: A connective tissue degeneration in elderly strabismic patients. *J. AAPOS* 2009;13:36–44. [PubMed: 18930668]
35. Yamada K, Andrews C, Chan W-M, et al. Heterozygous mutations of the kinesin KIF21A in congenital fibrosis of the extraocular muscles type 1 (CFEOM1). *Nat. Genet* 2003;35:318–321. [PubMed: 14595441]
36. Demer JL, Clark RA, Engle EC. Magnetic resonance imaging evidence for widespread orbital dysinnervation in congenital fibrosis of extraocular muscles due to mutations in KIF21A. *Invest. Ophthalmol. Vis. Sci* 2005;46:530–539. [PubMed: 15671279]
37. Demer JL, Clark RA, Tischfield MA, Engle EC. Evidence of an asymmetrical endophenotype in congenital fibrosis of extraocular muscles type 3 resulting from TUBB3 mutations. *Invest. Ophthalmol. Vis. Sci* 2010;51:4600–4611. [PubMed: 20393110]
38. Demer JL, Clark RA, Lim K-H, Engle EC. Magnetic resonance imaging of innervational and extraocular muscle abnormalities in Duane-radial ray syndrome. *Invest. Ophthalmol. Vis. Sci* 2007;48:5505–5511. [PubMed: 18055799]
39. Demer JL, Clark RA, Lim KH, Engle EC. Magnetic resonance imaging evidence for widespread orbital dysinnervation in dominant Duane’s retraction syndrome linked to the DURS2 locus. *Invest. Ophthalmol. Vis. Sci* 2007;48:194–202. [PubMed: 17197533]
40. Kaeser PF, Brodsky MC. Fourth cranial nerve palsy and Brown syndrome: two interrelated congenital cranial dysinnervation disorders? *Curr. Neurol. Neurosci. Rep* 2013;13(6):352. [PubMed: 23636931]

41. Whitman MC, Engle EC. Ocular congenital cranial dysinnervation disorders (CCDDs): insights into axon growth and guidance. *Hum. Mol. Genet* Aug 1 2017;26(R1):R37–R44. [PubMed: 28459979]
42. Demer JL, Miller JM. Magnetic resonance imaging of the functional anatomy of the superior oblique muscle. *Invest. Ophthalmol. Vis. Sci* 1995;36(5):906–913. [PubMed: 7706039]
43. Demer JL. Vertical comitance of hypertropia in congenital and acquired superior oblique palsy. *J. Neuro-ophthalmol* 2022:(in press).
44. Velez FG, Clark RA, Demer JL. Facial asymmetry in superior oblique palsy and pulley heterotopy. *J. AAPOS* 2000;4:233–239. [PubMed: 10951300]
45. Demer JL, Clark RA. Magnetic resonance imaging demonstrates compartmental muscle mechanisms of human vertical fusional vergence. *J. Neurophysiol* 2015;113(7):2150–2163. [PubMed: 25589593]
46. Shin GS, Demer JL, Rosenbaum AL. High resolution dynamic magnetic resonance imaging in complicated strabismus. *J. Pediatr. Ophthalmol. Strabismus* 1996;33:282–290. [PubMed: 8934409]
47. Bhola R, Rosenbaum AL, Ortube MC, Demer JL. High-resolution magnetic resonance imaging demonstrates varied anatomic abnormalities in Brown syndrome. *J. AAPOS* 2004;9:438–448.
48. Demer JL, Dusyanth A. T2 fast spin echo magnetic resonance imaging of extraocular muscles. *J. AAPOS* 2011;15(1):17–23. [PubMed: 21397801]
49. Shin SY, Demer JL. Superior oblique extraocular muscle shape in superior oblique palsy. *Am. J. Ophthalmol* Mar 4 2015;59(6):1169–1179.e1162.
50. Suh SY, Clark RA, Le A, Demer JL. Extraocular muscle compartments in superior oblique palsy. *Invest. Ophthalmol. Vis. Sci* Oct 01 2016;57(13):5535–5540. [PubMed: 27768791]
51. Clark RA, Demer JL. Enhanced vertical rectus contractility by magnetic resonance imaging in superior oblique palsy. *Arch. Ophthalmol* 2011;129(7):904–908. [PubMed: 21746981]
52. Demer JL, Clark RA. Magnetic resonance imaging of human extraocular muscles during static ocular counter-rolling. *J. Neurophysiol* 2005;94:3292–3302. [PubMed: 16033934]
53. Schindelin J, Arganda-Carreras I, Frise E, et al. Fiji: an open-source platform for biological-image analysis. *Nat Methods*. 2012;9(7):676–682. [PubMed: 22743772]
54. Clark RA, Miller JM, Demer JL. Three-dimensional location of human rectus pulleys by path inflections in secondary gaze positions. *Invest. Ophthalmol. Vis Sci* 2000;41:3787–3797. [PubMed: 11053278]
55. Goseki T, Suh SY, Robbins L, Pineles SL, Velez FG, Demer JL. Prevalence of sagging eye syndrome in adults with binocular diplopia. *Am. J. Ophthalmol* 2020;209:55–61. [PubMed: 31526795]
56. Ivanir Y, Trobe JD. Comparing hypertropia in up and downgaze distinguishes congenital from acquired fourth nerve palsies. *J. Neuroophthalmol* Dec 2017;37(4):365–368. [PubMed: 27787462]
57. Helveston EM, Krach D, Plager DA, Ellis FD. A new classification of superior oblique palsy based on congenital variations in the tendon. *Ophthalmology*. 1992;99:1609–1615. [PubMed: 1454330]
58. Plager DA. Tendon laxity in superior oblique palsy. *Ophthalmol*. 1992;99:1032–1038.
59. Helveston EM, Giangiacomo JG. Congenital absence of superior oblique tendon. *Trans Am. Ophthalmol Soc* 1981;79:123–135. [PubMed: 7342398]
60. Sato M. Magnetic resonance imaging and tendon anomaly associated with congenital superior oblique palsy. *Am. J. Ophthalmol* 1999;127:379–387. [PubMed: 10218689]
61. Aleassa M, Le A, Demer JL. Special features of superior oblique hypofunction due to tendon abnormalities. *Strabismus*. 2021;29(4):243–251. [PubMed: 34787034]



**Fig. 1.** Two 15 year old patients with congenital right hypertropia. A, B, D, E: quasi-coronal MRI in mid-orbital MRI planes. C, F: Prism-cover binocular alignment measurements demonstrate similar fulfillment of the 3-step test (3ST). Panels A-C represent right SO palsy manifested by profound size reduction of the right SO muscle seen in A, contrasting with normal left SO in B. Panels D-F represent masquerading SO palsy with bilaterally normal SO cross sections in D and E. RHT – right hypertropia.



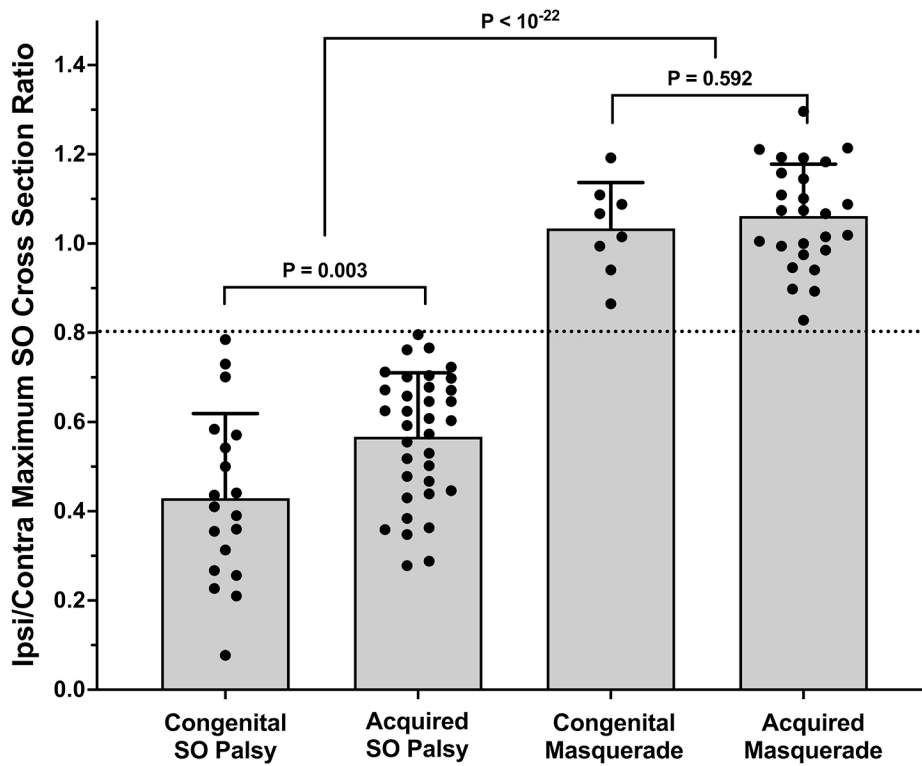
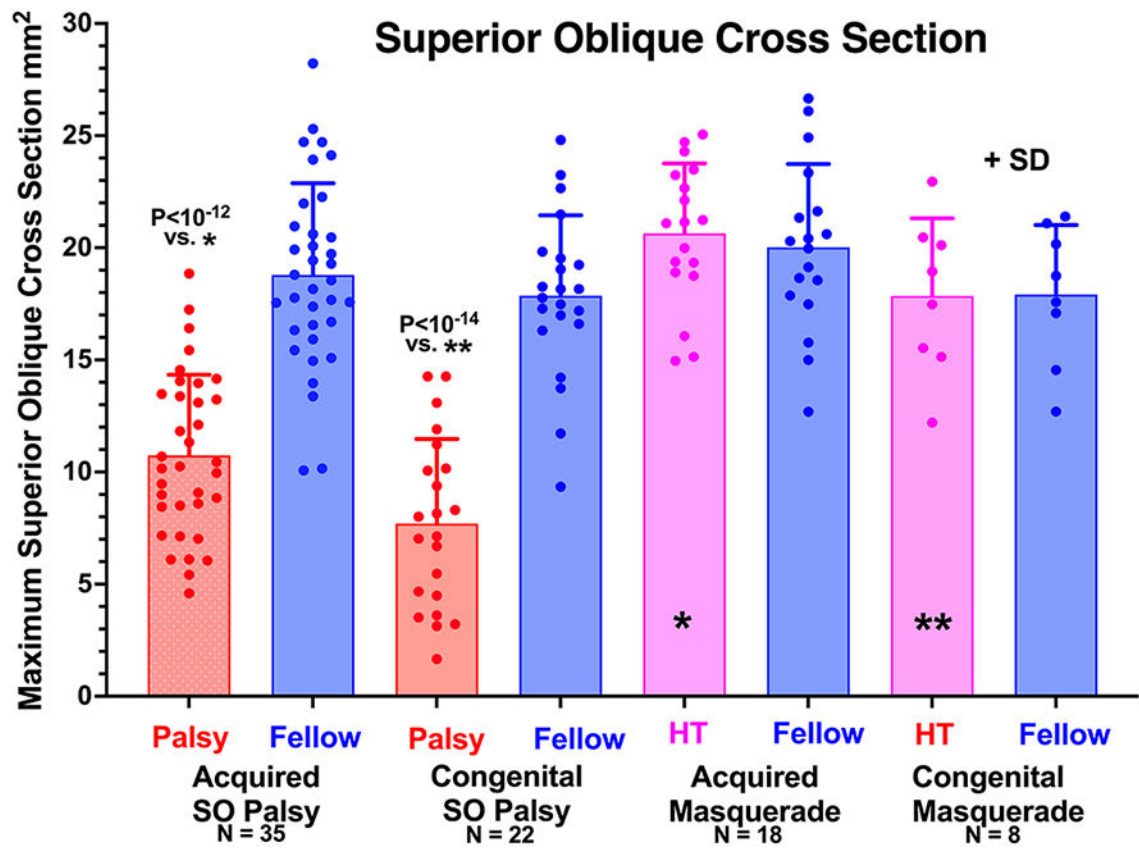
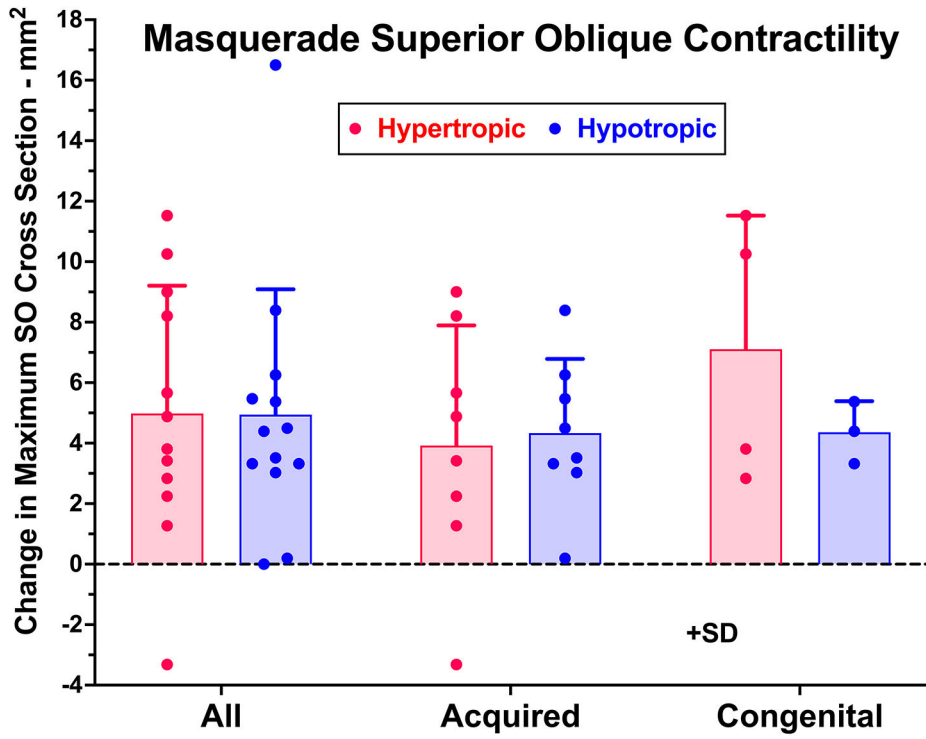


Fig. 2. Ratio of maximum cross sectional area of superior oblique (SO) muscle in the hypertropic to the fellow orbits of hypertropic patients. The ratio was less than 0.8 (dotted line) in acquired and congenital SO palsy, but greater in acquired and masquerading SO palsy. Symbols represent each individual muscle. 2-tail t-testing. SD – standard deviation.

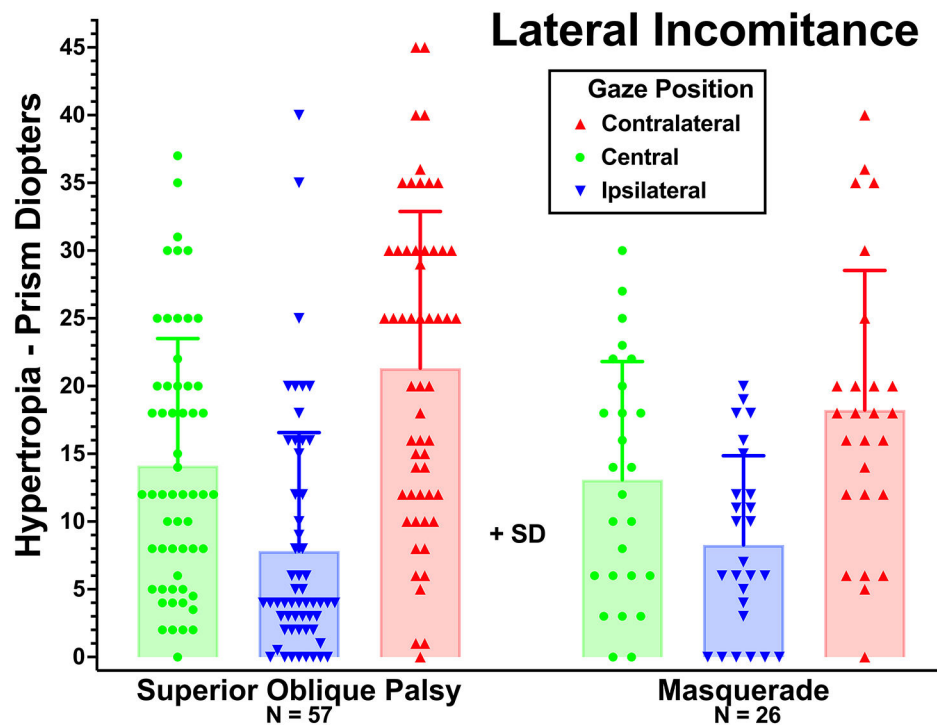




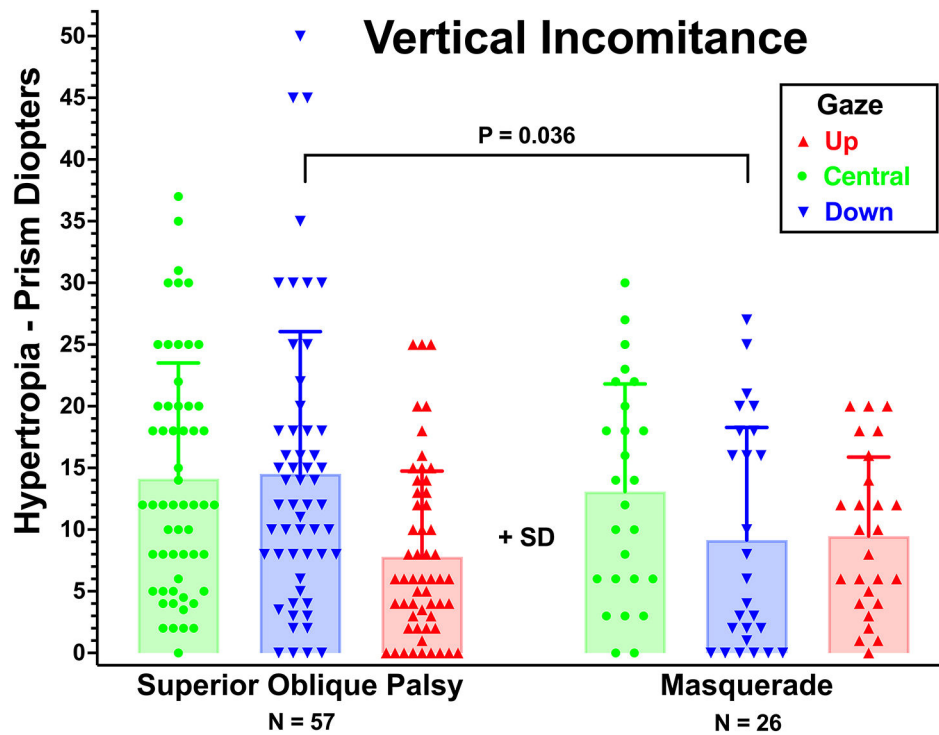
**Fig. 3.** Maximum cross sectional area of superior oblique (SO) muscle in the hypertropic (HT) and fellow orbits of patients with acquired and congenital SO palsy and masquerading SO palsy. Cross section is highly significantly decreased in SO palsy but not masquerades. Symbols represent each individual muscle. 2-tail t-testing. SD – standard deviation.



**Fig. 4.** Contractile change in maximum superior oblique (SO) cross section from relaxation in up gaze to contraction in down gaze in the two orbits of all masquerading cases in whom this imaging was performed. There was no significant difference in contractility between hypertropic and hypotropic SO muscles, either in acquired or congenital cases, or when all cases were pooled ( $P = 0.675$ ). Symbols represent each individual muscle. 2-tail t-testing. SD – standard deviation.



**Fig. 5.** Lateral incomitance of hypertropia in central gaze, and in ipsilateral and contralateral gazes in superior oblique (SO) palsy and masquerading SO palsy. None of these values for the masquerades differed significantly from SO palsy ( $P > 0.4$ ). Symbols represent each individual muscle. 2-tail t-testing. SD – standard deviation.



**Fig. 6.** Vertical incomitance of hypertropia in central gaze, and in up and down gazes in superior oblique (SO) palsy and masquerading SO palsy. Hypertropia in down gaze was significantly larger in SO palsy at  $14.7 \pm 11.6$  than in the overall group of masquerades at  $9.2 \pm 9.1$  ( $P=0.036$ ). Symbols represent each individual muscle. 2-tail t-testing. SD – standard deviation.

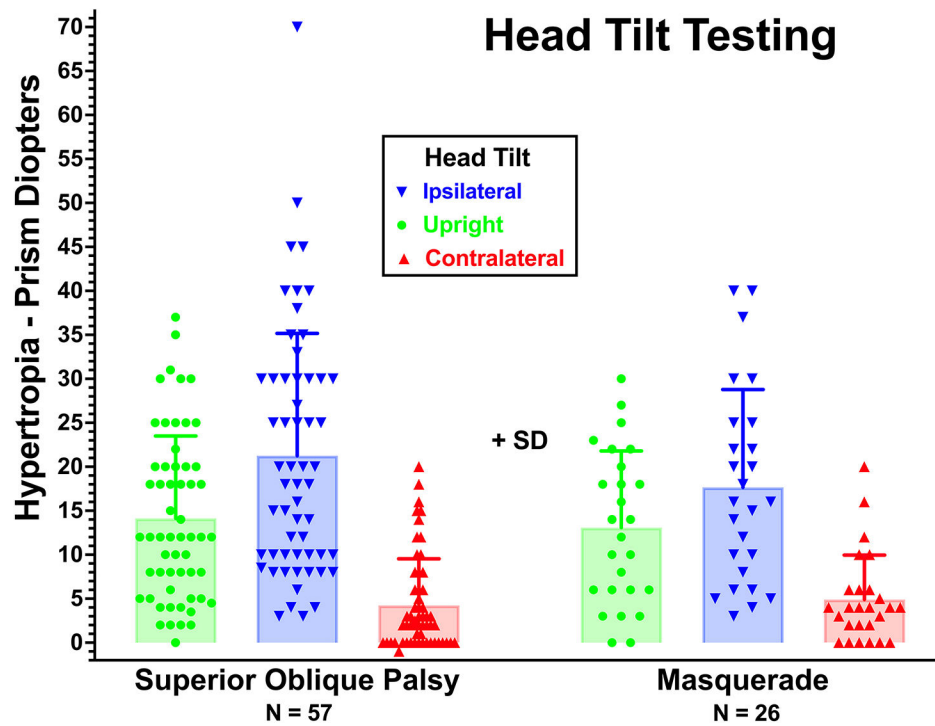
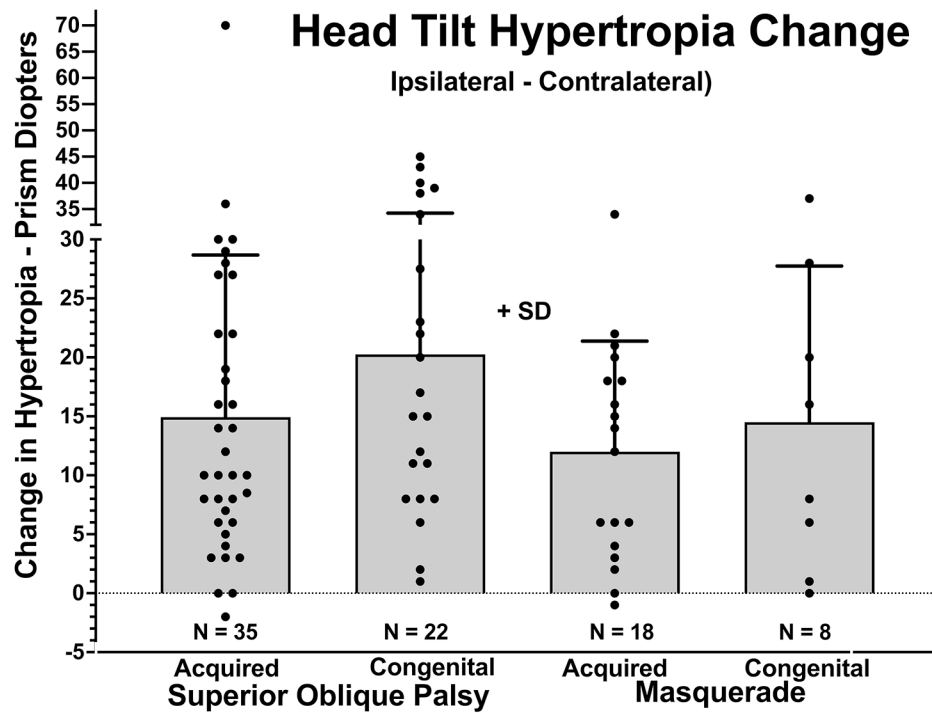
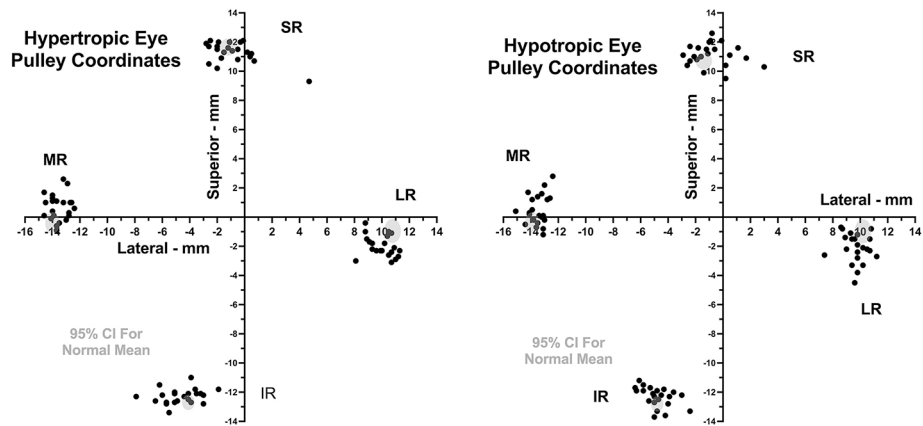


Fig. 7.

Hypertropia in upright gaze, and in head tilts ipsilateral and contralateral to the hypertropic eye in superior oblique (SO) palsy and masquerading SO palsy. The variation in hypertropia did not differ significantly between groups ( $P > 0.26$ ). Symbols represent each individual muscle. 2-tail t-testing. SD – standard deviation.



**Fig. 8.** Difference in hypertropia measured between head ipsilateral and contralateral to the hypertropic orbit, in superior oblique (SO) palsy and masquerading SO palsy. These values did not significantly differ between SO palsy and masquerade cases ( $P > 0.3$ ). Symbols represent each individual muscle. 2-tail t-testing. SD – standard deviation.



**Fig. 9.** Oculocentric coordinates of the inferior rectus (IR), lateral rectus (LR), medial rectus (MR), and superior rectus (SR) pulleys in all cases of masquerading superior oblique (SO) palsy. While vertical coordinates of the MR pulley were generally superior, and for the LR pulley generally inferior, to published mean normal coordinates whose 95% confidence limits are depicted in the gray ovals<sup>54</sup>, these abnormalities were statistically similar ( $P > 0.3$ ) in the hypertropic and hypotropic orbits. This excludes asymmetrical pulley sag as the typical cause of masquerading SO palsy in these cases.