

UC Davis

UC Davis Previously Published Works

Title

Infectious bovine keratoconjunctivitis (pinkeye)

Permalink

<https://escholarship.org/uc/item/9t65c79z>

Journal

Veterinary Clinics of North America - Food Animal Practice, 31(1)

ISSN

0749-0720

Author

Angelos, JA

Publication Date

2015

DOI

10.1016/j.cvfa.2014.11.006

Copyright Information

This work is made available under the terms of a Creative Commons Attribution-NonCommercial-NoDerivatives License, available at <https://creativecommons.org/licenses/by-nc-nd/4.0/>

Peer reviewed

Infectious bovine keratoconjunctivitis (pinkeye)

John A. Angelos, MS, DVM, PhD, DACVIM

Corresponding Author

John Angelos

jaangelos@ucdavis.edu

VM: Med&Epi

2108 Tupper Hall

Davis, CA 95616

Keywords

Pinkeye, Infectious bovine keratoconjunctivitis, *Moraxella bovis*, *Moraxella bovoculi*,

Treatment, Prevention

Key Points

- Effective treatment of pinkeye requires accurate diagnosis
- Antibiotic treatment can the shorten healing time
- Multiple routes of antibiotic delivery can be effective
- Efforts to develop herd preventive strategies must involve considerations of risk factors

Video of classical signs of Infectious bovine keratoconjunctivitis accompanies this article.

Abstract

As with many livestock diseases, the most successful efforts to control (Infectious bovine keratoconjunctivitis) IBK include multiple facets of disease control including the host, the environment, herd management, and ongoing surveillance even after the immediate crisis has passed. Research over many years has led to the discovery of a variety of antibiotic treatments

and antibiotic regimens that can be effective against IBK. The discoveries of *Mor bovoculi* and reports of IBK associated with *Mycoplasma* spp without concurrent *Mor bovis* or *Mor bovoculi* have raised new questions into the roles that other organisms may play in IBK. When collecting samples for submission to clinical microbiology laboratories, patient selection and correct sample submission is vitally important to maximize the chances for obtaining useful information. Discussions of IBK control programs with producers should take into consideration all aspects of the disease including the host immune response and reduction of potential risk factors.

Outline

Key Points

Abstract

Introduction

Patient Evaluation Overview

Pharmacologic Treatment Options

 Subconjunctival/topical penicillin

 Topical cloxacillin

 Parenteral oxytetracycline

 Parenteral tulathromycin

 Parenteral florfenicol

 Parenteral ceftiofur

 Parenteral/intrapalpebral tilmicosin versus intrapalpebral oxytetracycline

 Parenteral florfenicol versus parenteral oxytetracycline

 Parenteral plus oral oxytetracycline versus subconjunctival penicillin

Intrapalpebral versus parenteral oxytetracycline

Other pharmacologic treatment options

Nonpharmacologic Treatment Options

Combination Therapies

Surgical Treatment Options

Treatment Resistance/Complications

Evaluation of Outcome and Long-Term Recommendations

Summary/Discussion

References

Introduction

Infectious bovine keratoconjunctivitis (IBK or ‘pinkeye’) is the most common eye disease of cattle and can affect all breeds, however, a greater incidence of disease has been reported in lighter colored breeds such as Hereford or Hereford-crossbred cattle.¹⁻⁴ The etiologic agent of IBK is considered to be the gram-negative rod-shaped organism named *Moraxella bovis*. The pathogenicity of *Mor bovis* requires the expression of pilin for attachment to the ocular surface^{5,6} and a cytotoxin⁷ that damages corneal epithelial cells both in vitro⁸ and in vivo.^{9,10} Although a 2007 report of *Moraxella bovoculi*¹¹ isolated from eyes of calves affected with IBK has led to increased diagnoses of *Mor bovoculi* from ocular swabs of cattle with clinical IBK, experimental challenge studies have failed to demonstrate a role for *Mor bovoculi* in causing corneal ulcers associated with IBK.¹² Nevertheless, the identification of both a cytotoxin in *Mor bovoculi*¹³ and more recently of a putative pilin gene¹⁴ warrant further investigations into the role that *Mor bovoculi* may play in IBK. It is possible that *Mor bovoculi* may play a similar role to other pathogens such as *Mycoplasma* spp and infectious bovine rhinotracheitis (IBR; bovine herpesvirus) that induce ocular pathology and may assist in *Mor*

bovis-associated ocular colonization or spread.¹⁵⁻¹⁸ In this article, both *Mor bovis* and *Mor bovoculi* will be included in the discussion as both organisms are commonly isolated from cattle with IBK and treatment is often sought for one or both of these organisms. Nevertheless, studies published to date have not proven a direct causal role for *Mor bovoculi* in IBK.¹²

Colonization of the eyes of cattle by *Mor bovis*^{19,20} and *Mor bovoculi* (JAA; personal observation) can occur in the absence of clinical disease and both organisms can be cultured from the eyes of healthy cattle. Exactly what other intrinsic factors are that might play a role in stimulating otherwise commensal *Moraxella* spp. to cause disease are not well understood, however, during efforts to control an outbreak of IBK it is important to consider the role that extrinsic risk factors can play in IBK development. Such factors include exposure to ultraviolet radiation^{19,21,22}, flies²³⁻²⁶, *Mycoplasma* spp infection^{17,18}, infectious bovine rhinotracheitis (IBR) virus infection^{15,16}, and foreign bodies (dust, plant awns). The typical pattern of fluorescein dye staining of a cornea damaged by a plant awn such as a foxtail (see Fig. 1) embedded in the soft tissues surrounding the globe is that of uniform uptake to the corneal-limbal junction (see Fig. 2).

Published reports of *Mycoplasma* spp in ocular lesions identified clinically as IBK with no evidence of *Mor bovis*²⁷⁻²⁹ help to underscore why it is important to submit appropriate diagnostic specimens on appropriate test media to clinical microbiology laboratories when trying to establish an etiology for ocular lesions presumed to be IBK. It is also a good idea to consult with your clinical microbiology laboratory in advance of sample collection to determine the best sample to collect and media to use for sample transport. This relatively small investment in time can pay large dividends later by saving veterinarians and their clients both time and money. Opinions on the use and efficacy of autogenous vaccines to prevent IBK vary widely, however, if a client has expressed interest in development of an autogenous vaccine, it would be important

to request the clinical microbiology laboratory to preserve isolates for such use during initial sample submission.

Patient Evaluation Overview

A close-up examination of the bovine eye usually requires restraint in a chute, often with a halter to properly position the animal's head. Thorough examination of the eye to investigate for the presence of foreign bodies will require rotation of the head and close animal contact, especially in instances where a foreign body is suspected based on the pattern of fluorescein staining when no plant fibers are immediately visible. During such examinations and especially with cattle exhibiting severe epiphora, ocular secretions harboring *Moraxella* spp. can easily soak into the clothing of animal handlers and veterinarians performing such exams. For these reasons it is recommended to wear gloves and, if possible, an impervious apron or other non-absorbing type of clothing that can be disinfected with dilute bleach or chlorhexidine between animals. In addition to hands and clothing, halters should be disinfected between animals as well as any equipment used to examine the eye such as forceps used for removal of foreign bodies.

Classical signs of IBK include corneal ulceration and opacity (edema), photophobia, blepharospasm, lacrimation, and epiphora (see Fig. 3 and video). Early lesions can be extremely small and easily missed (see Fig. 4), and clear evidence of corneal edema may be difficult to appreciate from a distance. In these animals the presence of epiphora and slight photophobia/blepharospasm can provide early clues to the presence of disease. As IBK progresses other clinical signs including increased corneal opacity and worsening blepharospasm, photophobia, and epiphora will develop (see Figs. 5-8). Most corneal ulcerations associated with IBK will heal with varying degrees of corneal scarring that can

impair vision (see Fig. 9). The ocular pain associated with IBK along with reduced vision and subsequent reduced feed intake most likely account for reduced weight gains in cattle with IBK.^{2,30-32} In the most severe cases, corneal rupture can occur resulting in permanent blindness (see Fig. 10). Globe healing can occur following ocular rupture (see Fig. 11); calves with such protruberant-appearing globes during severe inflammation are often referred to by producers as ‘popeyes’.

Pharmacologic Treatment Options

IBK research reported over the past ~60 years has led to conclusions that a variety of antibiotics administered via intramuscular, subcutaneous, subconjunctival, and topical routes can be effective against IBK. Unfortunately, there has been a lack of randomization and adequate controls in many of these published studies; this finding underscores the need for better study designs for future studies that evaluate treatments for IBK.³³ At the present time in the U.S.A. only 2 parenterally administered antibiotics carry label claims to treat IBK due to *Mor bovis*: oxytetracycline and tulathromycin. In the event that approved treatments prove ineffective against IBK in some herds, however, legal routes to the use of alternate antibiotics exist through the Animal Medicinal Drug Use Clarification Act (AMDUCA) and its implementing regulations published at Title 21, Code of Federal Regulations, Part 530 (21 CFR 530).^{34,35} Many of the drugs/drug formulations that have been evaluated for efficacy against IBK are not currently available in the U.S.A. and the following discussion on treatment will focus on those drugs/formulations/preparations that would be most accessible to U.S. practitioners.

Moraxella bovis and *Mor bovoculi* are generally considered to be susceptible to a variety of different antibiotics. In the case of *Mor bovis*, the organism is known to survive in/on ocular surfaces, a fact that rationalizes the widely practiced method of sampling ocular fluids for bacterial culture (i.e., the swabbing of conjunctival fluid/ocular surfaces). To help reduce non-specific contamination and improve chances of isolating *Moraxella* spp when collecting ocular fluid samples, it is recommended to swab the edges of corneal ulcers rather than the subconjunctival fornix (K. Clothier, California Animal Health and Food Safety Laboratory; personal communication). In experimental and natural IBK infections, *Mor bovis* is also found to exist within the corneal stroma.^{10,36} To reach these surfaces adequately to assist in clearing an infection, an antibiotic would have to be delivered directly locally in the eye and/or by methods that ensure delivery of antibiotic via ocular fluid secretions.

Table 1 (for *Mor bovis*³⁷) and Table 2 (for *Mor bovoculi*³⁸) list antibiotic concentrations tested and breakpoints used in determining the minimum inhibitory concentrations (MIC) of selected antibiotics necessary to inhibit 90% of isolates (MIC₉₀) by the broth microdilution method in 2 studies that evaluated 88 isolates of *Mor bovis* and 57 isolates of *Mor bovoculi*. In Table 3, the compiled results from these 2 studies are summarized and show that both *Mor bovis* and *Mor bovoculi* are generally susceptible to a wide variety of antimicrobials. It is important to recognize that there are currently no established veterinary breakpoints approved by the Clinical and Laboratory Standards Institute (CLSI) for use with *Mor bovis* and *Mor bovoculi* isolated from cases of IBK. In this situation extrapolation from breakpoints established for pathogens associated with bovine respiratory disease can provide guidance when determining an appropriate antibiotic choice. Further information on the use of antibiotic susceptibility testing

and extrapolation of results in decision making for IBK therapy can be found in Article XX (“Using Individual Animal Susceptibility Test Results in Bovine Practice by B. Lubbers).

Subconjunctival/topical penicillin

Perhaps the most commonly used treatment for IBK is local ocular therapy with penicillin, usually administered in either the bulbar or palpebral conjunctiva. Two studies have evaluated the levels of penicillin in ocular fluid following subconjunctival injections. A dose of 600,000 international units (IU; 2 ml) procaine penicillin injected either through the skin or through the conjunctiva into the subconjunctival space produced a peak penicillin concentration in the conjunctival fluid of approximately 8 IU/ml for either route and a duration of therapeutic concentration (DTC; this was defined as 5 times the MIC of penicillin against *Mor bovis*) of ~68 h and ~40 h, respectively.³⁹ In that study, the difference between the DTC’s at these 2 routes were significantly different. When the dose of penicillin was reduced to 1 ml (300,000 IU) given subconjunctivally through the conjunctiva, the DTC was reduced to ~35 hr, however, this dose was not significantly different than the 2 ml dose given through the conjunctiva. These investigators concluded that all three dose/routes tested should, in theory, provide adequate anti-*Mor bovis* conjunctival fluid concentrations of penicillin to justify this therapy.

The same investigators also evaluated penicillin concentrations in conjunctival fluid following topical application of sodium benzyl-, procaine-, and benethamine-penicillin in various aqueous and ointment bases.⁴⁰ The oil-based products produced DTCs that ranged from ~37 to ~56 hours. In sum, these studies supported a rationale for why the use of penicillin subconjunctivally should be effective and the study authors suggested that a 48 hour treatment interval should be adequate between penicillin treatments.^{39,40}

When penicillin (300,000 U procaine penicillin G; 1 ml) administered either alone or in combination with dexamethasone (1 ml; 4 mg) was dosed subconjunctivally in the superior palpebral conjunctiva once daily for 3 consecutive days, no differences were observed between treatment and untreated control groups in the outcome of naturally occurring IBK.⁴¹ In a subsequent study, when penicillin (300,000 U of procaine penicillin G) was administered subconjunctivally in the bulbar conjunctiva (repeated 48 to 72 hours later), the prevalence of IBK was significantly reduced among calves that received procaine penicillin G compared with untreated control group calves. Most likely the difference in efficacy between these 2 studies can be attributed to differences in the route of penicillin delivery. In the 1995 study penicillin was administered subconjunctivally in the superior palpebral conjunctiva instead of in the bulbar conjunctiva.

In a study involving ocular penicillin treatment in dairy cows, a single bulbar subconjunctival dose of procaine penicillin G (300,000 units) resulted in milk penicillin that could be detected for up to 22 hours after injection.⁴²

Topical cloxacillin

Topical ocular application of 250 mg/eye and 375 mg/eye of benzathine cloxacillin were found to be effective against experimentally induced IBK where these treatments resulted in lower rates of *Mor bovis* isolations from ocular secretions and reduced clinical scores and corneal ulcer surface areas as compared to control groups of calves.⁴³ In that study, lower concentrations of benzathine cloxacillin (50 mg/eye and 125 mg/eye) were not found to be effective. In a similar study that evaluated the efficacy of benzathine cloxacillin against naturally occurring IBK, benzathine cloxacillin at the same doses described above were both effective, especially when administered early in the course of disease.⁴⁴ The commercially

available intramammary therapies in the U.S.A. that contain cloxacillin deliver between 200 and 500 mg of cloxacillin in a volume of 10 ml. In the studies described above, doses given to calves were contained within a 1 ml volume. The application of 1ml of an intramammary treatment of a commercially available cloxacillin preparation would only provide a small fraction of the drug levels necessary to achieve the desired result in treating IBK.

Parenteral oxytetracycline

Compared to untreated control group calves, calves that received 2 doses of long-acting oxytetracycline (20 mg/kg; 72 hours apart) had a lower incidence of IBK and decreased duration of *M. bovis* shedding following experimental infection.⁴⁵ This same dose of long-acting oxytetracycline was also found to shorten the number of days of lacrimation and blepharospasm in calves with experimentally induced IBK.⁴⁶

Parenteral tulathromycin

A single subcutaneous dose of tulathromycin (2.5 mg/kg) was compared to no treatment in calves experimentally infected with *Mor bovis*.⁴⁷ In that study the benefits of treatment included significantly fewer isolations of *Mor bovis* from ocular swabs, shorter healing times, lower corneal lesion scores, reduced sizes of corneal ulcers, and development of fewer ulcers bilaterally versus control group calves.

Parenteral florfenicol

Two studies have reported on the efficacy of florfenicol against experimentally induced⁴⁸ and naturally occurring IBK.⁴⁹ In the experimental study, calves were randomly assigned to receive 2 doses of florfenicol (20 mg/kg IM at 0 and 48 hours), 1 dose of florfenicol (40 mg/kg SC one time), or no treatment (control group). Ulcer healing rates were significantly greater in calves of the IM and SC groups (6.2 and 4.8 times, respectively) versus the control group.

Clinical scores and ulcer surface area measurements for the 2 florfenicol groups were significantly lower as compared to the control group. As both IM and SC groups were comparable in most variables evaluated in that study, it was suggested that SC dosing would be advantageous over IM dosing in that there would be decreased tissue damage associated with injections and decreased cost associated with labor with SC treatment. In a study of florfenicol against naturally occurring IBK, corneal ulcer healing rates were significantly greater in the IM and SC groups (3.3 and 2.6 times, respectively) versus the control group and both routes of administration were considered equally effective.⁴⁹

Parenteral ceftiofur

The use of ceftiofur crystalline-free acid (CCFA) administered at a single 6.6 mg/kg dose subcutaneously in the posterior aspect of the pinna for treatment of corneal ulceration associated with naturally occurring IBK was evaluated.⁵⁰ In that study a control group of calves were administered vehicle alone (control group). This treatment resulted in a 4 fold increased odds of corneal ulcer healing by 14 days as compared to control group calves and results supported that CCFA was effective against naturally occurring IBK. Although CCFA was shown to be effective against IBK, its use for IBK would be considered extralabel. Since 2012 in the U.S.A. the extralabel uses of cephalosporins (with the exception of approved cephalosporin products in food-producing animals) have been prohibited at unapproved dose levels, frequencies, durations or routes of administration and for disease prevention in cattle, swine, chickens, and turkeys.³⁵ This FDA ruling prohibits the use of cephalosporin drugs that are labelled for use in humans or companion animals in cattle if the drug is not approved for use in cattle. While CCFA could be used to treat IBK, it would have to be dosed exactly according to approved dosing regimens on the product label for specified indications (bovine respiratory disease, foot rot, and acute

metritis). Also, according to AMDUCA³⁴, the approved antibiotics for treatment of IBK (oxytetracycline and tulathromycin) would have to be determined by a veterinarian working with a client within the context of a valid veterinarian-client-patient-relationship to be clinically ineffective in order for ceftiofur to be legally prescribed for use in treatment of IBK.

Parenteral/intrapalpebral tilmicosin versus intrapalpebral oxytetracycline

The efficacy of tilmicosin versus no treatment or oxytetracycline was evaluated in one randomized blocked and blinded study.⁵¹ That study evaluated treatment effects over a 21 day period on 120 steers with naturally occurring IBK divided into 6 groups: no treatment (control); oxytetracycline (300 mg intrapalpebral injection; volume not described); tilmicosin (300 mg; 1 ml) administered into the eyelid (intrapalpebral); and tilmicosin (subcutaneous; SC) administered at 3 different doses (2.5, 5, and 10 mg/kg). Results showed that the percent improvement in clinical signs (ocular discharge, blepharospasm, and corneal lesion scores (a measurement that took into account the severity of corneal opacity, ulceration, vision compromise, and presence of globe rupture) between day 0 and 21 were significantly higher for the 10 mg/kg SC tilmicosin group versus the control and oxytetracycline group. Significantly higher percent improvement in corneal lesion scores from day 0 to day 21 was observed between the oxytetracycline versus all tilmicosin treatment groups, but not between the control versus tilmicosin treatment groups. The study authors concluded that tilmicosin at 5 or 10 mg/kg subcutaneously was therapeutically beneficial, however, they did not recommend use of tilmicosin by the intrapalpebral route.

Parenteral florfenicol versus parenteral oxytetracycline

One randomized study compared the efficacy of florfenicol versus oxytetracycline (each drug dosed at 20 mg/kg IM; 2 doses 48 hours apart) in 30 Brown Swiss calves with naturally occurring IBK over a 10 week period; in this study, blinding of study personnel was not

described.²⁶ The results of the study reported that while photophobia and lacrimation decreased only slightly at 48 hours in the oxytetracycline treated group, these signs disappeared completely at 24 hours in the florfenicol group. The mean time to disappearance of corneal opacity was 13.14 ± 3.39 days in the florfenicol group versus 18.56 ± 6.18 days in 9 of 15 calves the oxytetracycline group. IBK reoccurred in 3 of 15 oxytetracycline-treated calves during weeks 6 and 7 of the follow up period, however, no reoccurrences were observed in the florfenicol-treated calves. The overall conclusion of the study authors was that florfenicol was more effective than oxytetracycline. Whether these conclusions are justified is difficult to determine as there was limited study data available in the results and no reported results of any statistical analysis.

Parenteral plus oral oxytetracycline versus subconjunctival penicillin

The use of combined oral plus parenteral (SC) oxytetracycline to ameliorate IBK during an outbreak was evaluated in 119 Hereford calves.⁵² In that study calves were randomly assigned to receive either no treatment (control group), 300,000 U of procaine penicillin G subconjunctivally in the bulbar conjunctiva (repeated 48 to 72 hours later), or a combined parenteral plus oral oxytetracycline treatment. In the oxytetracycline group, calves were administered an injection of a long-acting formulation of oxytetracycline (20 mg/kg IM; repeated again 72 hours later if ulcers were present on days 1 and 2) plus oral oxytetracycline (2g/calf/day) for 10 days delivered in alfalfa pellets. Calves were examined 3 times per week for 7 weeks. Calves in the oxytetracycline group had significantly fewer ulcer recurrences versus control or penicillin group calves. The oxytetracycline group also had a significantly lower prevalence of IBK versus control group and penicillin group calves during days 11 through 49 and 21 through 49, respectively. *Moraxella bovis* was isolated from significantly fewer ocular secretion specimens from calves in the oxytetracycline group versus either the control or

penicillin treated groups. Between days 1-10 and 40-49 *Moraxella bovis* was isolated from significantly fewer ocular secretion specimens from calves in the penicillin group versus control group calves. Corneal ulcer healing times were significantly lower for both the oxytetracycline and penicillin treatment groups versus the control group. The authors of this study concluded that both oxytetracycline and penicillin (injected subconjunctivally in the bulbar conjunctiva) were effective in reducing healing times of corneal ulcers associated with IBK. The reduced prevalence of IBK as well as the reduced number of calves developing recurrent ulcers in the oxytetracycline group versus the penicillin group suggested that oxytetracycline was superior to penicillin treatment. It is not known, however, whether the benefit of oxytetracycline was attributable to parenteral treatment, oral treatment, or both from this study, however, another study had previously demonstrated the benefit of parenteral oxytetracycline (two doses of 20 mg/kg IM 72 hours apart) in reducing the incidence of IBK and decreasing the duration of *Mor bovis* shedding.⁴⁵ It is important to remember that under current federal laws in the U.S.A., use of oxytetracycline in feed to treat IBK would be illegal as extra-label use of drugs in animal feed is prohibited.³⁵

Intrapalpebral versus parenteral oxytetracycline

Oxytetracycline administered by the intrapalpebral (200 mg oxytetracycline hydrochloride solution (10%) injected through the skin) versus intramuscular (20 mg/kg IM) routes were evaluated for treatment of calves with naturally occurring IBK.⁵³ In this study both treatments were similar in the mean number of treatments per animal and the interval between diagnosis and healing, however, significantly less medication was required for the intrapalpebral group. As expected the calves with intrapalpebral injections of oxytetracycline developed large swellings around the eye that disappeared by 72 hours post injection. While administration of

oxytetracycline intrapalpebrally through the skin was considered effective, the administration of long-acting oxytetracycline (100 mg in the bulbar conjunctiva), however, was found in another study to cause conjunctival chemosis and necrosis and was not recommended.⁵⁴

Other pharmacologic treatment options

Antibiotic therapy for acute cases of IBK is generally recommended, however, no generally accepted guidelines exist on when to treat versus not treat based on corneal ulcer size. In the author's experience, ulcers that are less than 5 mm maximal diameter will often heal spontaneously, however, this is not always the case and in valuable animals or where concerns exist for an outbreak, antibiotics are recommended. In developing standard operating procedures for treatment of IBK for owners, it is important to emphasize that every calf with a cloudy-appearing eye does not necessarily require antibiotics. For example, a calf with the eye shown in Fig. 9 has a cloudy eye, however, further antibiotic treatment for this animal is not necessary, as the ulcer is healed and blood vessels are covering the entire lesion. In the author's experience, it is useful to give clients photographs of healed and unhealed eyes in order to educate them on how to identify corneal neovascularization. When corneal neovascularization has bridged the corneal defect, antibiotics are not usually necessary.

Besides antibiotics, treatment with a non-steroidal anti-inflammatory drug such as flunixin meglumine is likely to reduce ocular inflammation and improve the comfort level of the animal. Use of other drugs such as atropine could be considered, however, titrating atropine treatment to effect can be impractical in field settings.

The addition of dexamethasone (1 ml; 4 mg) to penicillin (300,000 U) administered in the superior palpebral conjunctiva did not appear to alter corneal ulcer healing time, severity,

diameter, surface area measurement, or frequency of ulcer recurrence versus untreated calves or calves treated with penicillin alone.⁴¹

One of the older treatments that cattle producers sometimes mention as being extremely effective is the use of ‘puffers’ that deliver nitrofurazone topically in the eye. While this treatment is effective, nitrofurazone is strictly prohibited from extralabel use in food producing animals in the U.S.A.⁵⁵ Because there are currently no nitrofurazone containing products that carry any label approval for use in food producing animals, this prohibition effectively bans any use of nitrofurazone products in food animals. This prohibition also applies to any remaining older products that may have indicated approval for use in cattle for treatment of IBK.

Nonpharmacologic Treatment Options

In more intensive treatment settings, application of autologous patient serum eye drops harvested from whole blood can provide corneal growth factors and anticollagenase activities that may aid in corneal ulcer healing.⁵⁶ In field settings this therapy is usually impractical as frequent (every 30 – 60 minutes) dosing is probably necessary to provide the most benefit. Dosing as often as is practically possible, however, should not be harmful and may be practical under some field settings with dedicated owners. To prepare serum it should be harvested under as sterile conditions as possible and then maintained under refrigeration and replaced every few days.

The use of denim patches to cover eyes of cattle with IBK can provide comfort to an affected animal by reducing ambient light and can also reduce exposure of flies to ocular secretions which can harbor *Moraxella* spp. When advising owners on use and application of patches it is a good idea to recommend that a ventral opening be left to prevent build-up of

ocular secretions and humidity and to remind owners to check eyes frequently after patches are placed to make sure that ulcers are not worsening under the patch.

Although no studies have evaluated ocular healing of trace mineral deficient and trace mineral replete cattle with experimentally induced IBK, it is likely that adequate trace mineral status (often copper and selenium) is important in maintaining optimal immune responses in cattle at risk of developing or that have already developed IBK.

Moraxella bovis is known to survive in/on flies²³⁻²⁶ and reducing fly burdens is an extremely important part of any IBK control program. A variety of different fly control products and methods of delivery are available and a complete listing of all such products is beyond the scope of this discussion. For further information on availability of such products consultations with local county/agriculture extension agents may be informative. If producers are using insecticide-impregnated ear tags, it is important to stress that such ear tags should be placed on (at the very least) calves and should be removed at the end of the fly season to prevent the development of insecticide resistance.

Combination Therapies

The use of multiple antibiotics in the treatment of IBK under field settings is not generally recommended for both economic reasons as well as from the standpoint of good stewardship relative to antibiotic use and concerns over development of antimicrobial resistance. *Moraxella bovis* and *Mor bovoculi* are typically very sensitive organisms and should respond to appropriate single drug therapies. In cases where multiple organisms (for example *Mycoplasma* spp plus Moraxellae) may be responsible for ongoing disease in a herd, it is important to select an appropriate antibiotic class that would be effective against both types of organisms.

Tulathromycin is currently licensed to treat IBK in the U.S.A. and also has a label claim for treatment and control of respiratory disease associated with *Mycoplasma bovis*. Whether or not this drug would be effective under field settings in controlling an IBK outbreak that involves *Mycoplasma* spp. is not known. In cases where the involvement of *Mycoplasma* spp is being considered, it is also important to remember that the use of a beta lactam antibiotic (e.g. penicillin or a cephalosporin class drug) that kills by inhibiting cell wall synthesis would be ineffective against an organism such as mycoplasma that lacks a cell wall.

Surgical Treatment Options

Surgical treatment options that have been used in treating cattle with IBK include third eyelid flaps and tarsorrhaphy. In cases where globe rupture has occurred or where severe scar formation and globe protrusion represents a potential liability to the animal, exenteration may be indicated.

Treatment Resistance/Complications

For an individual animal, a treatment failure should be considered when the severity of corneal ulceration is worsening or other clinical signs related to IBK are not improving. When therapy is delayed, corneal scarring can lead to reduced vision and possibly globe rupture and permanent blindness. At the herd level, failure of a pinkeye treatment/control program is apparent when numbers of active cases are observed to be increasing over time. When a specific antibiotic treatment does not appear to be working, it is worth collecting ocular samples for

bacterial culture and sensitivity testing. Samples should be collected from animals with early cases that have not been treated. Collecting samples from as many affected animals as possible is recommended, ideally from 10-20% of affected animals. Testing on such a scale can be cost prohibitive, however, and at the very least it is recommended that samples be collected from 10-12 animals if possible. As mentioned above, it can be cost saving to contact the clinical microbiology laboratory prior to sample collection to make sure that appropriate samples in the correct media are submitted along with an accurate culture request. If the development of an autogenous bacterin is being considered by your client, it is valuable to request that the laboratory preserve isolates for future use/submission to a vaccine manufacturer.

Evaluation of Outcome and Long-Term Recommendations

With successful therapy an IBK-affected animal will generally appear more comfortable with reduced ocular discharge and improved ability to hold the eyelids open. In outbreak or potential outbreak situations, early recognition of treatment failures is important and should prompt a discussion with the client/herd manager on a variety of topics that cover issues such as how the treatments are being done, whether gloves are being worn, and if equipment is being disinfected between animals. When vaccines are being used, it is important to stress the importance of proper timing of vaccination relative to when IBK typically occurs in a herd. Although there are widely divergent views on the merits of vaccination for IBK, producers who use vaccines should recognize that the full potential to realize a vaccine benefit is optimized when a vaccine series is initiated at least 4 weeks prior to the typical IBK season. In any herd setting, IBK is never just an individual animal problem and identification of IBK should prompt discussions with producers on all aspects of IBK control and prevention including reduction of

potential risk factors for disease (flies, foreign bodies (plant awns, dust), UV radiation, concurrent infections (*Mycoplasma* spp., IBR, possibly *Mor bovoculi*), vaccinations, and trace mineral status/supplementation.

Summary/Discussion

As with many livestock diseases, the most successful efforts to control IBK include multiple facets of disease control including the host, the environment, herd management, and ongoing surveillance even after the immediate crisis has passed. Research over many years has led to the discovery of a variety of antibiotic treatments and antibiotic regimens that can be effective against IBK. The discoveries of *Mor bovoculi* and reports of IBK associated with *Mycoplasma* spp without concurrent *Mor bovis* or *Mor bovoculi* have raised new questions into the roles that other organisms may play in IBK. When collecting samples for submission to clinical microbiology laboratories, patient selection and correct sample submission is vitally important to maximize the chances for obtaining useful information. Discussions of IBK control programs with producers should take into consideration all aspects of the disease including the host immune response and reduction of potential risk factors.

References

1. Frisch JE. The relative incidence and effect of bovine infectious keratoconjunctivitis in *Bos indicus* and *Bos taurus* cattle. *Animal Production* 1975;21:265-274.
2. Snowden GD, Van Vleck LD, Cundiff LV, et al. Genetic and environmental factors associated with incidence of infectious bovine keratoconjunctivitis in preweaned beef calves. *J Anim Sci* 2005;83:507-518.

3. Webber JJ, Selby LA. Risk factors related to the prevalence of infectious bovine keratoconjunctivitis. *J Am Vet Med Assoc* 1981;179:823-826.
4. Ward JK, Neilson MK. Pinkeye (bovine infectious keratoconjunctivitis) in beef cattle. *J Anim Sci* 1979;49:361-366.
5. Jayappa HG, Lehr C. Pathogenicity and immunogenicity of piliated and nonpiliated phases of *Moraxella bovis* in calves. *Am J Vet Res* 1986;47:2217-2221.
6. Annuar BO, Wilcox GE. Adherence of *Moraxella bovis* to cell cultures of bovine origin. *Res Vet Sci* 1985;39:241-246.
7. Hoiem-Dalen PS, Rosenbusch RF, Roth JA. Comparative characterization of the leukocidic and hemolytic activity of *Moraxella bovis*. *Am J Vet Res* 1990;51:191-196.
8. Kagonyera GM, George LW, Munn R. Cytopathic effects of *Moraxella bovis* on cultured bovine neutrophils and corneal epithelial cells. *Am J Vet Res* 1989;50:10-17.
9. Kagonyera GM, George LW, Munn R. Light and electron microscopic changes in corneas of healthy and immunomodulated calves infected with *Moraxella bovis*. *Am J Vet Res* 1988;49:386-395.
10. Rogers DG, Cheville NF, Pugh GW, Jr. Pathogenesis of corneal lesions caused by *Moraxella bovis* in gnotobiotic calves. *Vet Pathol* 1987;24:287-295.
11. Angelos JA, Spinks PQ, Ball LM, et al. *Moraxella bovoculi* sp. nov., isolated from calves with infectious bovine keratoconjunctivitis. *Int J Syst Evol Microbiol* 2007;57:789-795.
12. Gould S, Dewell R, Tofflemire K, et al. Randomized blinded challenge study to assess association between *Moraxella bovoculi* and Infectious Bovine Keratoconjunctivitis in dairy calves. *Vet Microbiol* 2013;164:108-115.

13. Angelos JA, Ball LM, Hess JF. Identification and characterization of complete RTX operons in *Moraxella bovoculi* and *Moraxella ovis*. *Vet Microbiol* 2007;125:73-79.
14. Calcutt MJ, Foecking MF, Martin NT, et al. Draft Genome Sequence of *Moraxella bovoculi* Strain 237T (ATCC BAA-1259T) Isolated from a Calf with Infectious Bovine Keratoconjunctivitis. *Genome Announc* 2014;2.
15. George LW, Ardans A, Mihalyi J, et al. Enhancement of infectious bovine keratoconjunctivitis by modified-live infectious bovine rhinotracheitis virus vaccine. *Am J Vet Res* 1988;49:1800-1806.
16. Pugh GW, Jr., Hughes DE, Packer RA. Bovine infectious keratoconjunctivitis: interactions of *Moraxella bovis* and infectious bovine rhinotracheitis virus. *Am J Vet Res* 1970;31:653-662.
17. Pugh GW, Hughes DE, Schulz VD. Infectious bovine keratoconjunctivitis: experimental induction of infection in calves with mycoplasmas and *Moraxella bovis*. *Am J Vet Res* 1976;37:493-495.
18. Rosenbusch RF. Influence of mycoplasma preinfection on the expression of *Moraxella bovis* pathogenicity. *Am J Vet Res* 1983;44:1621-1624.
19. Lepper AW, Barton IJ. Infectious bovine keratoconjunctivitis: seasonal variation in cultural, biochemical and immunoreactive properties of *Moraxella bovis* isolated from the eyes of cattle. *Aust Vet J* 1987;64:33-39.
20. Pugh GW, McDonald TJ, Kopecky KE. Infectious bovine keratoconjunctivitis: effects of vaccination on *Moraxella bovis* carrier state in cattle. *Am J Vet Res* 1980;41:264-266.
21. Hughes DE, Pugh GW, Jr., McDonald TJ. Ultraviolet radiation and *Moraxella bovis* in the etiology of bovine infectious keratoconjunctivitis. *Am J Vet Res* 1965;26:1331-1338.

22. Hughes DE, Pugh GW, McDonald TJ. Experimental bovine infectious keratoconjunctivitis caused by sunlamp irradiation and *Moraxella bovis* infection: resistance to re-exposure with homologous and heterologous *Moraxella bovis*. *Am J Vet Res* 1968;29:829-833.
23. Arends JJ, Wright RE, Barto PB, et al. Transmission of *Moraxella bovis* from blood agar cultures to Hereford cattle by face flies (Diptera: Muscidae). *Journal of Economic Entomology* 1984;77:394-398.
24. Glass HW, Jr., Gerhardt RR, Greene WH. Survival of *Moraxella bovis* in the alimentary tract of the face fly. *J Econ Entomol* 1982;75:545-546.
25. Steve PC, Lilly JH. Investigations on transmissibility of *Moraxella bovis* by the face fly. *J Econ Entomol* 1965;58:444-446.
26. Gokce HI, Citil M, Genc O, et al. A comparison of the efficacy of florfenicol and oxytetracycline in the treatment of naturally occurring infectious bovine keratoconjunctivitis. *Irish Veterinary Journal* 2002;55:573-576.
27. Naglic T, Sankovic F, Madic J, et al. Mycoplasmas associated with bovine conjunctivitis and keratoconjunctivitis. *Acta Vet Hung* 1996;44:21-24.
28. Levisohn S, Garazi S, Gerchman I, et al. Diagnosis of a mixed mycoplasma infection associated with a severe outbreak of bovine pinkeye in young calves. *J Vet Diagn Invest* 2004;16:579-581.
29. Alberti A, Addis MF, Chessa B, et al. Molecular and antigenic characterization of a *Mycoplasma bovis* strain causing an outbreak of infectious keratoconjunctivitis. *J Vet Diagn Invest* 2006;18:41-51.

30. Funk LD, Reecy JM, Wang C, et al. Associations between infectious bovine keratoconjunctivitis at weaning and ultrasonographically measured body composition traits in yearling cattle. *J Am Vet Med Assoc* 2014;244:100-106.
31. Killinger AH, Valentine D, Mansfield ME, et al. Economic impact of infectious bovine keratoconjunctivitis in beef calves. *Vet Med Small Anim Clin* 1977;72:618-620.
32. Thrift FA, Overfield JR. Impact of pinkeye (infectious bovine kerato-conjunctivitis) on weaning and postweaning performance of Hereford calves. *J Anim Sci* 1974;38:1179-1184.
33. O'Connor AM, Wellman NG, Evans RB, et al. A review of randomized clinical trials reporting antibiotic treatment of infectious bovine keratoconjunctivitis in cattle. *Anim Health Res Rev* 2006;7:119-127.
34. Animal Medicinal Drug Use Clarification Act of 1994 (AMDUCA). U.S. Food and Drug Administration. Accessed on August 31, 2014.
<http://www.fda.gov/AnimalVeterinary/GuidanceComplianceEnforcement/ActsRulesRegulations/ucm085377.htm>.
35. CFR - Code of Federal Regulations Title 21. U.S. Food and Drug Administration. Accessed on August 31, 2014.
<http://www.accessdata.fda.gov/scripts/cdrh/cfdocs/cfcfr/CFRSearch.cfm?CFRPart=530>.
36. Chandler RL, Smith K, Turfrey BA. Ultrastructural and histological studies on the corneal lesion in infectious bovine keratoconjunctivitis. *J Comp Pathol* 1981;91:175-184.
37. Zielinski G, Piscitelli H, Perez-Monti H, et al. Antibiotic sensitivity of an Argentine strain collection of *Moraxella bovis*. *Veterinary Therapeutics* 2000;1:199-204.

38. Angelos JA, Ball LM, Byrne BA. Minimum inhibitory concentrations of selected antimicrobial agents for *Moraxella bovoculi* associated with infectious bovine keratoconjunctivitis. *J Vet Diagn Invest* 2011;23:552-555.
39. Abeynayake P, Cooper BS. The concentration of penicillin in bovine conjunctival sac fluid as it pertains to the treatment of *Moraxella bovis* infection. (I) Subconjunctival injection. *J Vet Pharmacol Ther* 1989;12:25-30.
40. Abeynayake P, Cooper BS. The concentration of penicillin in bovine conjunctival sac fluid as it pertains to the treatment of *Moraxella bovis* infection. (II) Topical application. *J Vet Pharmacol Ther* 1989;12:31-36.
41. Allen LJ, George LW, Willits NH. Effect of penicillin or penicillin and dexamethasone in cattle with infectious bovine keratoconjunctivitis. *J Am Vet Med Assoc* 1995;206:1200-1203.
42. Liljebjelke KA, Warnick LD, Witt MF. Antibiotic residues in milk following bulbar subconjunctival injection of procaine penicillin G in dairy cows. *J Am Vet Med Assoc* 2000;217:369-371.
43. Daigneault J, George LW. Topically applied benzathine cloxacillin for treatment of experimentally induced infectious bovine keratoconjunctivitis. *Am J Vet Res* 1990;51:376-380.
44. George LW, Keefe T, Daigneault J. Effectiveness of two benzathine cloxacillin formulations for treatment of naturally occurring infectious bovine keratoconjunctivitis. *Am J Vet Res* 1989;50:1170-1174.
45. George LW, Smith JA. Treatment of *Moraxella bovis* infections in calves using a long-acting oxytetracycline formulation. *J Vet Pharmacol Ther* 1985;8:55-61.

46. Smith JA, George LW. Treatment of acute ocular *Moraxella bovis* infections in calves with a parenterally administered long-acting oxytetracycline formulation. *Am J Vet Res* 1985;46:804-807.
47. Lane VM, George LW, Cleaver DM. Efficacy of tulathromycin for treatment of cattle with acute ocular *Moraxella bovis* infections. *J Am Vet Med Assoc* 2006;229:557-561.
48. Dueger EL, Angelos JA, Cosgrove S, et al. Efficacy of florfenicol in the treatment of experimentally induced infectious bovine keratoconjunctivitis. *Am J Vet Res* 1999;60:960-964.
49. Angelos JA, Dueger EL, George LW, et al. Efficacy of florfenicol for treatment of naturally occurring infectious bovine keratoconjunctivitis. *J Am Vet Med Assoc* 2000;216:62-64.
50. Dueger EL, George LW, Angelos JA, et al. Efficacy of a long-acting formulation of ceftiofur crystalline-free acid for the treatment of naturally occurring infectious bovine keratoconjunctivitis. *Am J Vet Res* 2004;65:1185-1188.
51. Zielinski GC, Piscitelli HG, Perez-Monti H, et al. Efficacy of different dosage levels and administration routes of tilmicosin in a natural outbreak of infectious bovine keratoconjunctivitis (pinkeye). *Vet Ther* 2002;3:196-205.
52. Eastman TG, George LW, Hird DW, et al. Combined parenteral and oral administration of oxytetracycline for control of infectious bovine keratoconjunctivitis. *J Am Vet Med Assoc* 1998;212:560-563.
53. Starke A, Eule C, Meyer H, et al. Efficacy of intrapalpebral and intramuscular application of oxytetracycline in a natural outbreak of infectious bovine keratoconjunctivitis (IBK) in calves. *Dtsch Tierarztl Wochenschr* 2007;114:219-224.

54. George LW, Wilson WD, Baggot JD, et al. Antibiotic treatment of *Moraxella bovis* infection in cattle. *J Am Vet Med Assoc* 1984;185:1206-1209.
55. Electronic Code of Federal Regulations. Title 21: Food and Drugs. Part 530 - Extralabel Drug Use in Animals. Accessed September 1, 2014. http://www.ecfr.gov/cgi-bin/text-idx?SID=054808d261de27898e02fb175b7c9ff9&node=21:6.0.1.1.16&rgn=div5#se21.6.530_141.
56. Maggs DJ, Miller PE, and Ofri R. *Slatter's Fundamentals of Veterinary Ophthalmology*. 4th ed. St. Louis: Saunders Elsevier, 2008; p189.

Table 1. Concentrations and breakpoints used for antibiotics tested against 88 isolates of *Moraxella bovis* from Argentina.

* No defined breakpoints.

Antimicrobial agent	Concentration range tested (µg/ml)	Minimum Inhibitory Concentration (MIC) Breakpoint (µg/ml):		
		Sensitive	Intermediate	Resistant
Ampicillin	0.25 – 32	≤0.25	8	≥16
Ceftiofur	0.06 – 8	≤2	4	≥8
Enrofloxacin	0.03 – 4	≤0.5	1	≥2
Erythromycin	0.12 – 16	≤0.5	1	≥8
Florfenicol	0.12 – 16	≤2	4	≥8
Gentamicin	0.5 – 32	≤4	8	≥16
Lincomycin	0.25 – 32	≤0.5	1	≥4
Oxytetracycline	0.5 – 32	≤4	8	≥16
Spectinomycin	1 – 128	≤32	64	≥128
Tilmicosin	0.25 – 32	≤8	16	≥32
Trimethoprim/ Sulfamethoxazole	0.25/4.75 – 15/304	≤2/38		≥4/76
Tylosin	0.5 – 64	*	*	*

Adapted from Zielinski G, Piscitelli H, Perez-Monti H, et al. Antibiotic sensitivity of an Argentine strain collection of *Moraxella bovis*. *Veterinary Therapeutics* 2000;1:199-204, with permission.

Table 2. Concentrations and breakpoints used for antibiotics tested against 57 isolates of *Moraxella bovoculi* from cattle with infectious bovine keratoconjunctivitis in California, U.S.A. from 2002 through 2007.

Antimicrobial agent	Concentration range tested (µg/ml)	Minimum Inhibitory Concentration (MIC) Breakpoint (µg/ml):		
		Sensitive	Intermediate	Resistant
Ampicillin	0.25 – 16	≤8	16	≥32
Ceftiofur†	0.25 – 8	≤2	4	≥8
Chlortetracycline	0.5 – 8	≤2	4	≥8
Clindamycin	0.25 – 16	≤0.5	1-2	≥4
Danofloxacin†	0.12 – 1	≤0.25	*	*
Enrofloxacin†	0.12 – 2	≤0.25	0.5-1	≥2
Florfenicol†	0.25 – 8	≤2	4	≥8
Gentamicin	1 – 16	≤4	8	≥16
Neomycin	4 – 32	*	*	*
Oxytetracycline†	0.5 – 8	≤2	4	≥8
Penicillin	0.12 – 8	≤0.12		≥0.25
Spectinomycin†	8 – 64	≤32	64	≥128
Sulfadimethoxine	256	≤256		≥512
Tiamulin	0.5 – 32	≤16		≥32
Tilmicosin†	4 – 64	≤8	16	≥32
Trimethoprim/ Sulfamethoxazole	2/38	≤2/38		≥4/76
Tulathromycin†	1 – 64	≤16	32	≥64
Tylosin	0.5 – 32	*	*	*

* No defined breakpoints.

† Breakpoints based on Gram-negative pathogens associated with bovine respiratory disease.

Adapted from Angelos JA, Ball LM, Byrne BA. Minimum inhibitory concentrations of selected antimicrobial agents for *Moraxella bovoculi* associated with infectious bovine keratoconjunctivitis. *J Vet Diagn Invest* 2011;23:552-555, with permission.

Table 3. Compiled data from studies of minimum inhibitory concentrations of *Moraxella bovis* and *Moraxella bovoculi* as determined by the broth microdilution method.

Antimicrobial agent	<i>Moraxella bovis</i>		<i>Moraxella bovoculi</i>	
	MIC ₉₀	% Resistance	MIC ₉₀	% Resistance
Ampicillin	≤0.25	0.0	≤0.25	0.0
Ceftiofur	≤0.12	0.0	≤0.25	0.0
Chlortetracycline	n.t.*	n.c.†	1	1.8
Clindamycin	n.t.	n.c.	2	3.5
Danofloxacin	n.t.	n.c.	≤0.12	‡
Enrofloxacin	≤0.06	0.0	≤0.12	1.8
Erythromycin	≤1	0.0	n.t.	n.c.
Florfenicol	≤0.5	n.c.	0.5	3.5
Gentamicin	≤0.5	0.0	≤1	0.0
Lincomycin	≥32	98.8	n.t.	n.c.
Neomycin	n.t.	n.c.	≤4	‡
Oxytetracycline	≤1.0	0.0	1	3.5
Penicillin	n.t.	n.c.	0.25	12.3
Spectinomycin	≤8.0	n.c.	16	5.3
Sulfadimethoxine	n.t.	n.c.	>256	19.3
Tiamulin	n.t.	n.c.	1	5.3
Tilmicosin	≤1.0	0.0	≤4	3.5
Trimethoprim/ Sulfamethoxazole	≤0.25/4.75	0.0	≤2/38	7.0
Tulathromycin	n.t.	n.c.	4	0.0
Tylosin	≤4.0	n.c.	16	‡

*not tested

†not calculated

‡ no defined breakpoints; unable to determine

Adapted from Zielinski G, Piscitelli H, Perez-Monti H, et al. Antibiotic sensitivity of an Argentine strain collection of *Moraxella bovis*. *Veterinary Therapeutics* 2000;1:199-204 and Angelos JA, Ball LM, Byrne BA. Minimum inhibitory concentrations of selected antimicrobial agents for *Moraxella bovoculi* associated with infectious bovine keratoconjunctivitis. *J Vet Diagn Invest* 2011;23:552-555, with permission.

Fig 1. Left eye of a calf demonstrating presence of a plant awn (foxtail).

Fig 2. Same eye as in Fig. 1 after application of fluorescein dye. Note the staining pattern where the area of fluorescein dye uptake is continuous with the corneal-limbal junction; this pattern is characteristic of a foreign body-associated corneal ulcer.

Fig. 3. Calf with infectious bovine keratoconjunctivitis; the right eye has been stained with fluorescein dye. Note the presence of lacrimation, epiphora, and ocular pain in the right eye.

Fig 4. Early IBK lesion in a calf. Note the ~1mm diameter focal area of fluorescein dye uptake at the 6 o'clock position. Early IBK lesions can be difficult to identify and use of other clinical signs such as excessive lacrimation, epiphora, and/or blepharospasm/photophobia may be helpful to identify such cases.

Fig. 5. Close-up view of the right eye of a calf with IBK. Two areas of fluorescein staining are present along with corneal edema and whitish-yellow appearance to stromal layers that indicate infiltration of white blood cells.

Fig. 6. Same eye as in Fig. 5 one week later. Note the presence of ocular inflammation and ingrowth of blood vessels that indicate that active healing is taking place. The calf in this photo was treated with 40 mg/kg florfenicol subcutaneously on the day that this photo was taken.

Fig. 7. Same eye as in Fig. 6 one week later. Note that healing is ongoing as evidenced by the continued ingrowth of blood vessels toward the center of the corneal injury.

Fig 8. Same eye as in Fig. 7 one week later. Overall the inflammation remains most active at the center of the lesion and is resolving closer to the limbus.

Fig. 9. Same eye as in Fig. 8 one week later. Blood vessels appear to have bridged the site of the original ulcer. At this time the eye, although still cloudy, was much quieter and the calf appeared comfortable.

Fig. 10. Progression of corneal healing following perforation in a calf with IBK. The photographs depict a 77 day timeframe. The calf was treated with florfenicol (40 mg/kg SC) on day 0 when the ulcer was first identified. Although the globe healed, the calf was permanently blind in the affected eye.

Fig. 11. Eyes of calves with severe ocular inflammation following the development of IBK and likely rupture of the globe. Panels A and B represent 2 different calves with lesions described by producers as ‘popeyes’. Panels C, D, and E represent the calf depicted in panel B during the subsequent 3 weeks at each weekly interval. This calf received florfenicol (40 mg/kg SC) one time on the day that the photo in panel B was taken.

Video Legend

Video 1. Infectious bovine keratoconjunctivitis: clinical signs and healing

This video demonstrates clinical signs in a calf with bilateral infectious bovine keratoconjunctivitis and the progression of corneal healing over 21 days after the same calf was treated.

The progression of corneal healing following corneal perforation in another calf over a 77 day period is also demonstrated.

Fig 1. Left eye of a calf demonstrating presence of a plant awn (foxtail).

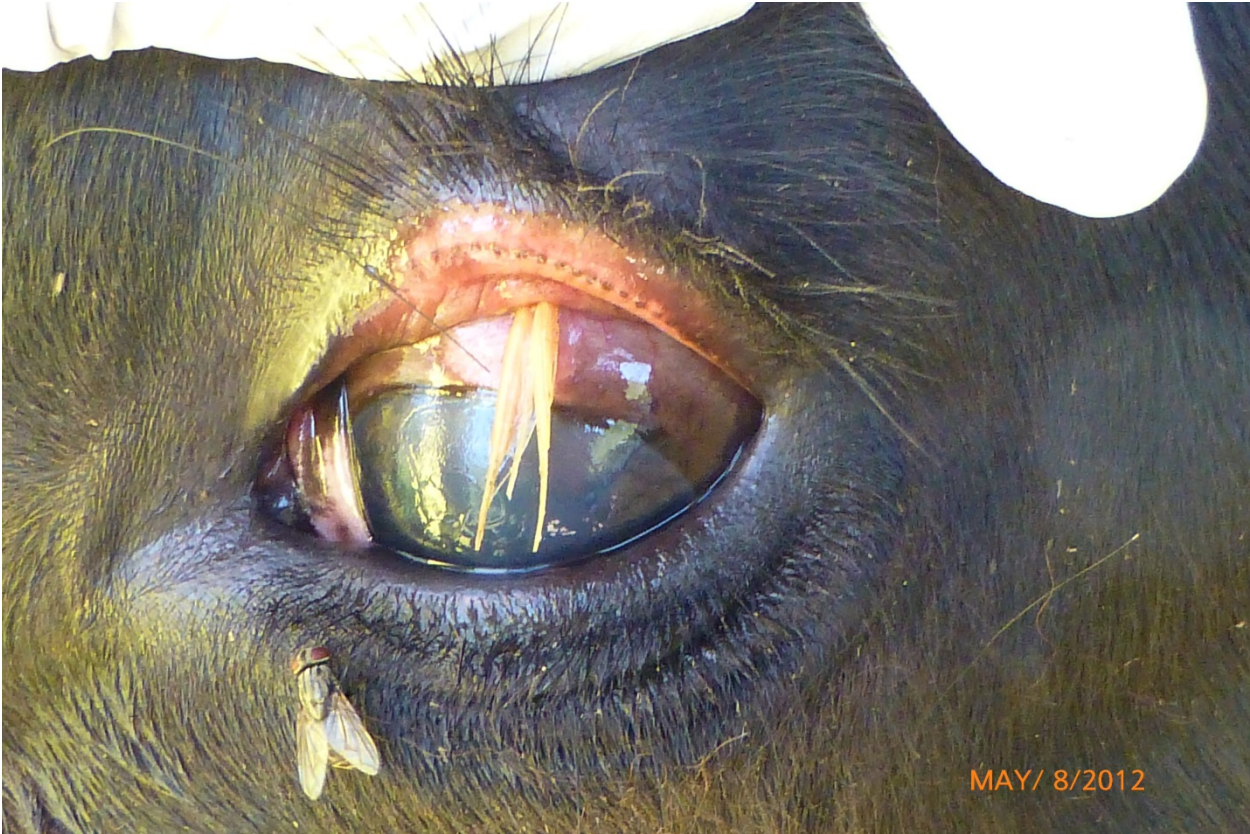

Fig 2. Same eye as in Fig. 1 after application of fluorescein dye. Note the staining pattern where the area of fluorescein dye uptake is continuous with the corneal-limbal junction; this pattern is characteristic of a foreign body-associated corneal ulcer.

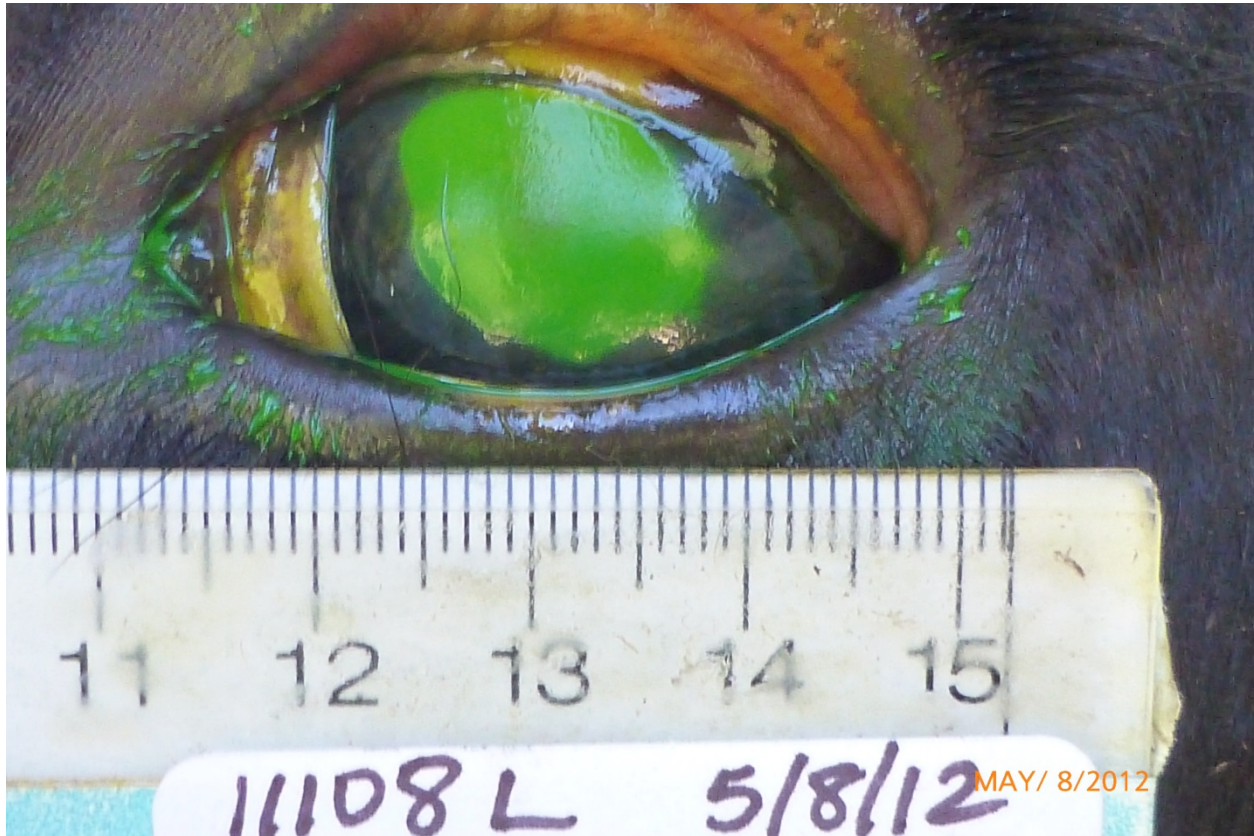


Fig. 3. Calf with infectious bovine keratoconjunctivitis; the right eye has been stained with fluorescein dye. Note the presence of lachrimation, ephiphora, and ocular pain in the right eye.



Fig 4. Early IBK lesion in a calf. Note the ~1mm diameter focal area of fluorescein dye uptake at the 6 o'clock position. Early IBK lesions can be difficult to identify and use of other clinical signs such as excessive lacrimation, epiphora, and/or blepharospasm/photophobia may be helpful to identify such cases.

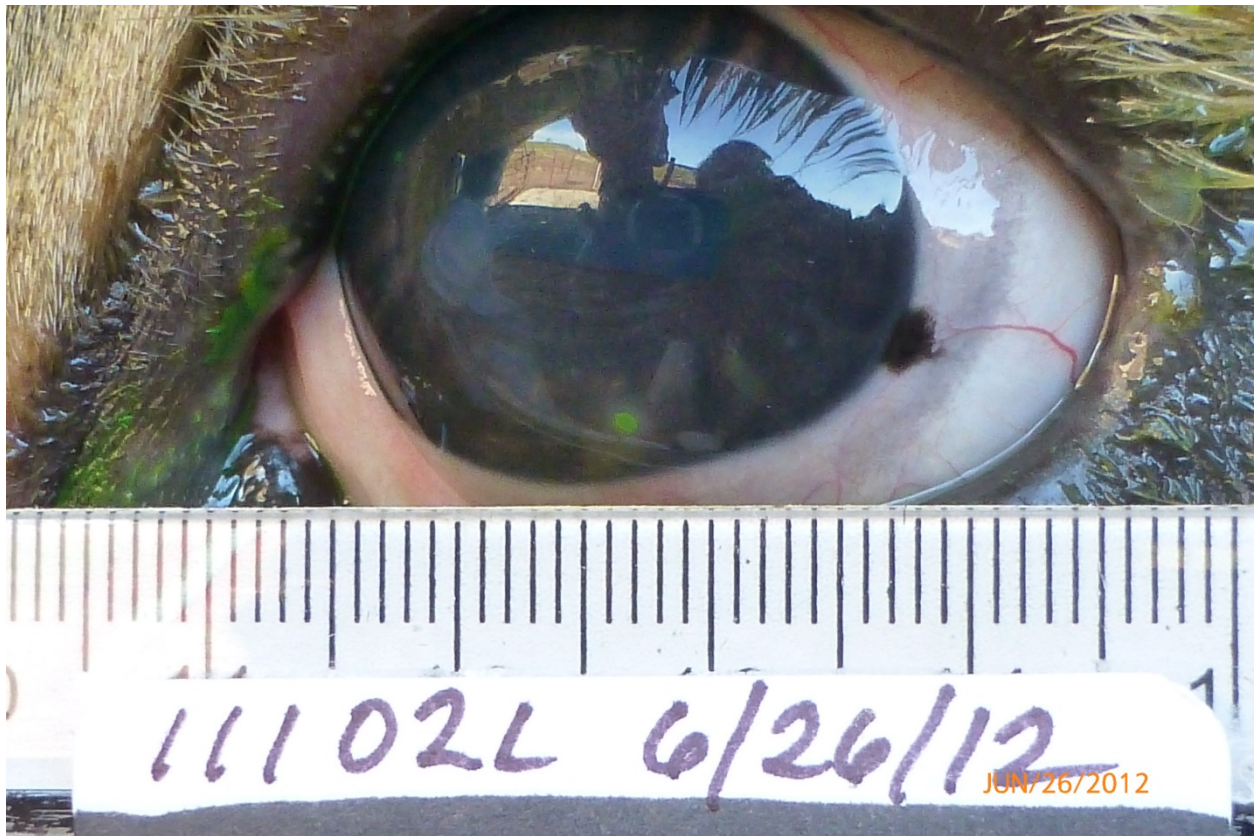

Fig. 5. Close-up view of the right eye of a calf with IBK. Two areas of fluorescein staining are present along with corneal edema and whitish-yellow appearance to stromal layers that indicate infiltration of white blood cells.

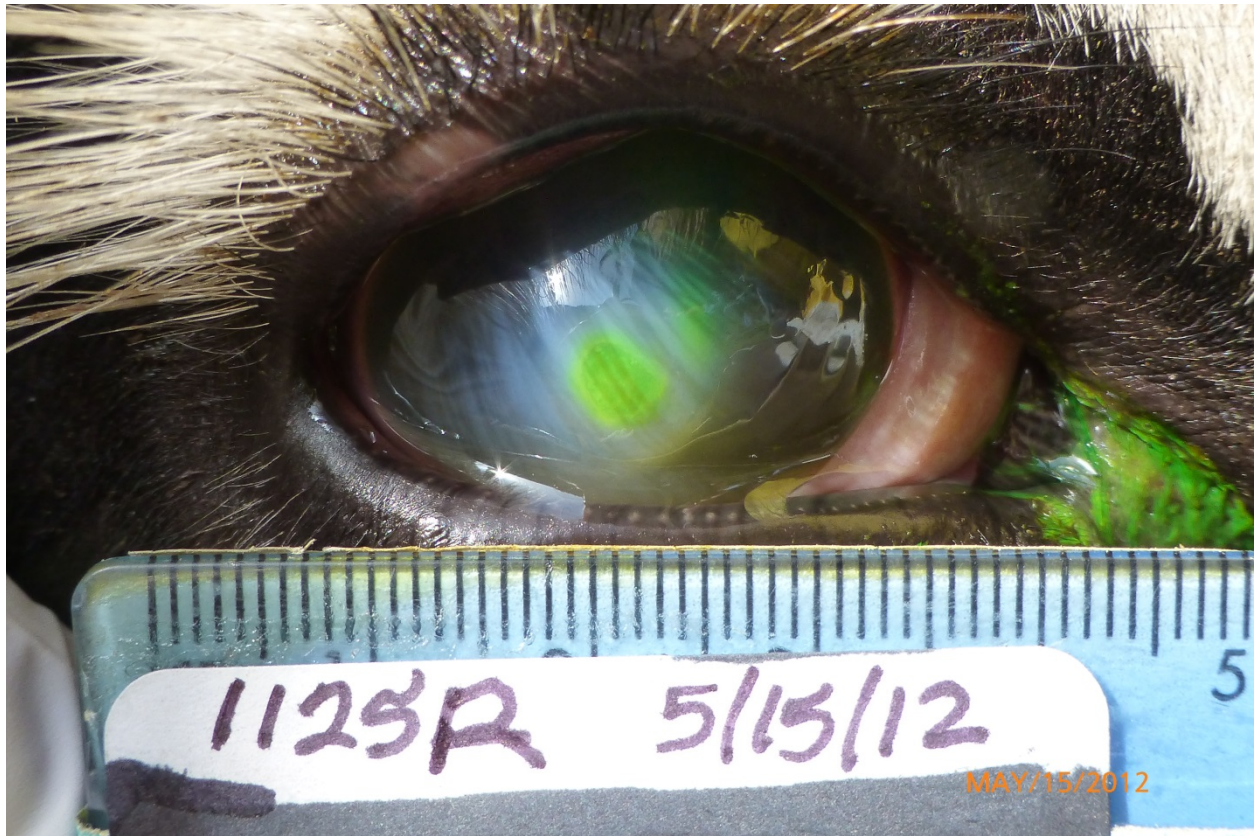


Fig. 6. Same eye as in Fig. 5 one week later. Note the presence of ocular inflammation and ingrowth of blood vessels that indicate that active healing is taking place. The calf in this photo was treated with 40 mg/kg florfenicol subcutaneously shortly after this photo was taken.

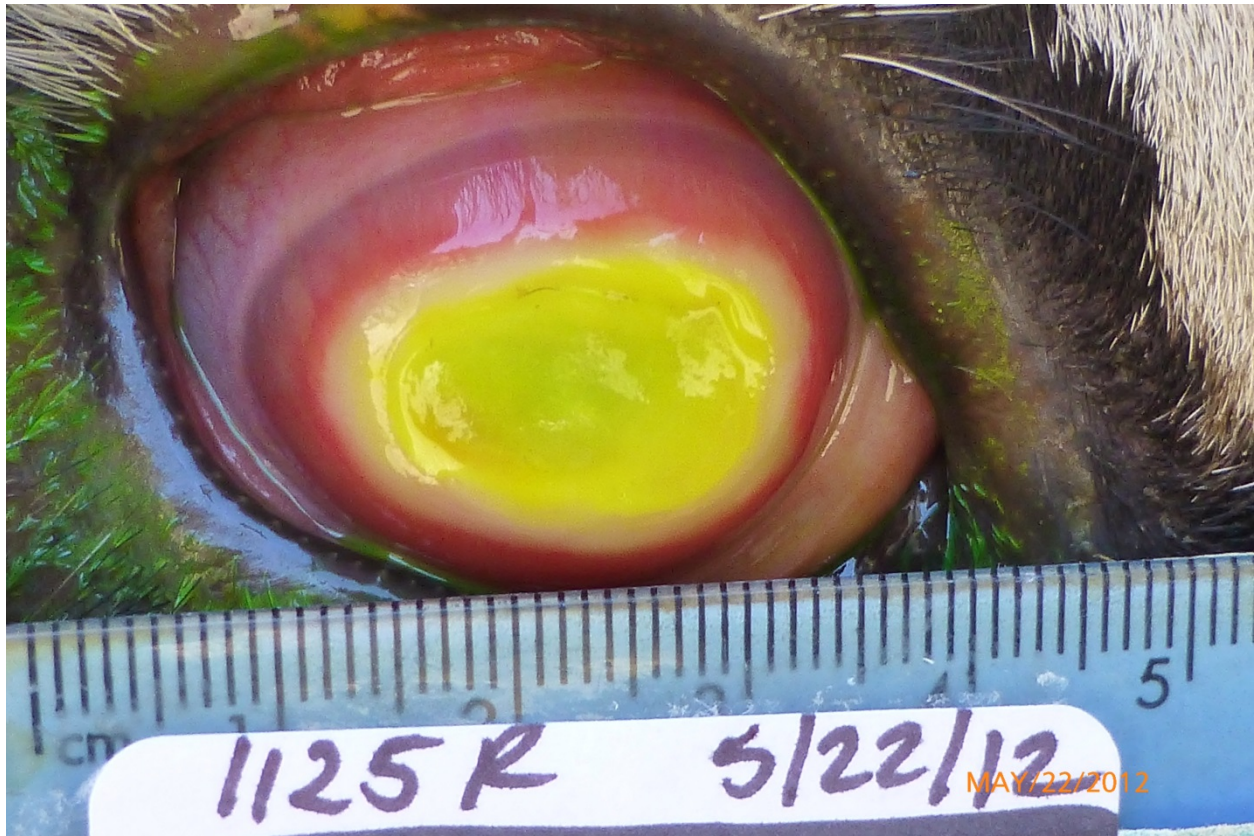


Fig. 7. Same eye as in Fig. 6 one week later. Note that healing is ongoing as evidenced by the continued ingrowth of blood vessels toward the center of the corneal injury.

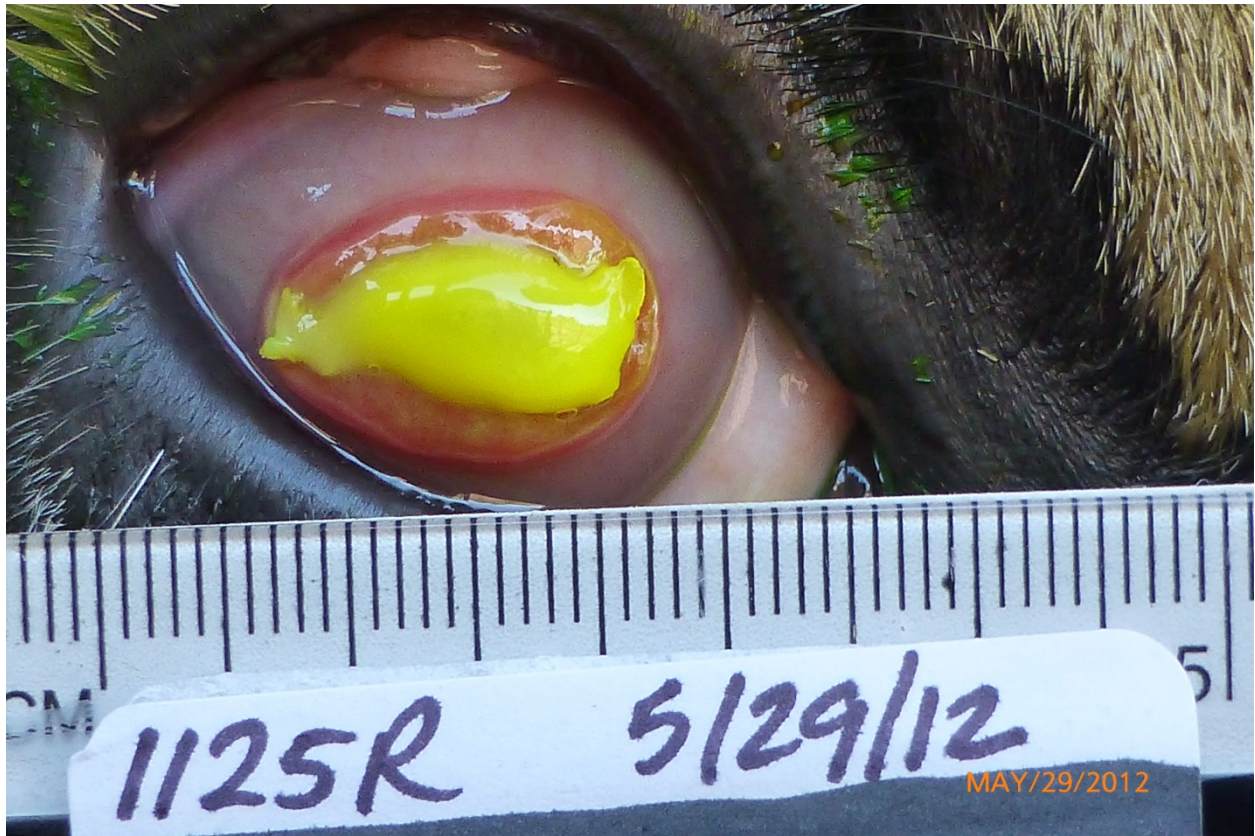

Fig 8. Same eye as in Fig. 7 one week later. Overall the inflammation remains most active at the center of the lesion and is resolving closer to the limbus.

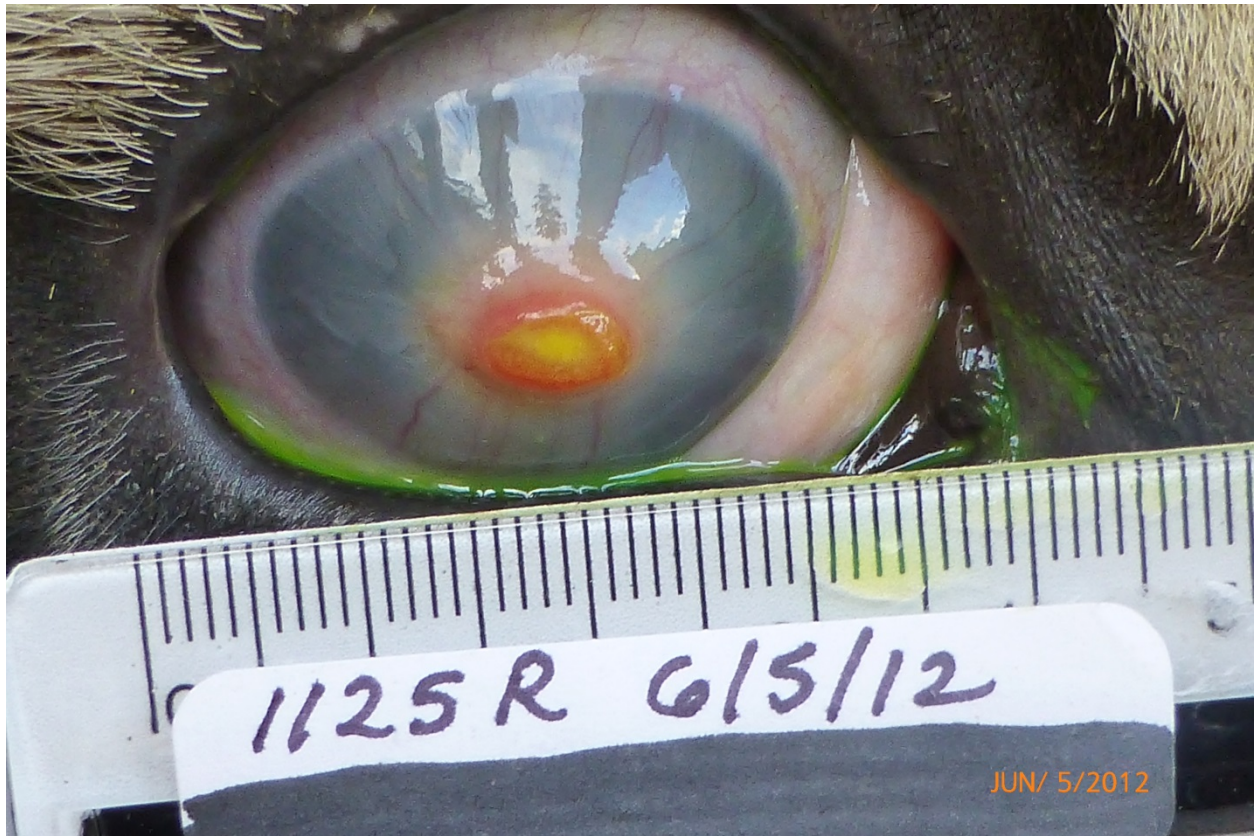

Fig. 9. Same eye as in Fig. 8 one week later. Blood vessels appear to have bridged the site of the original ulcer. At this time the eye, although still cloudy, was much quieter and the calf appeared comfortable.

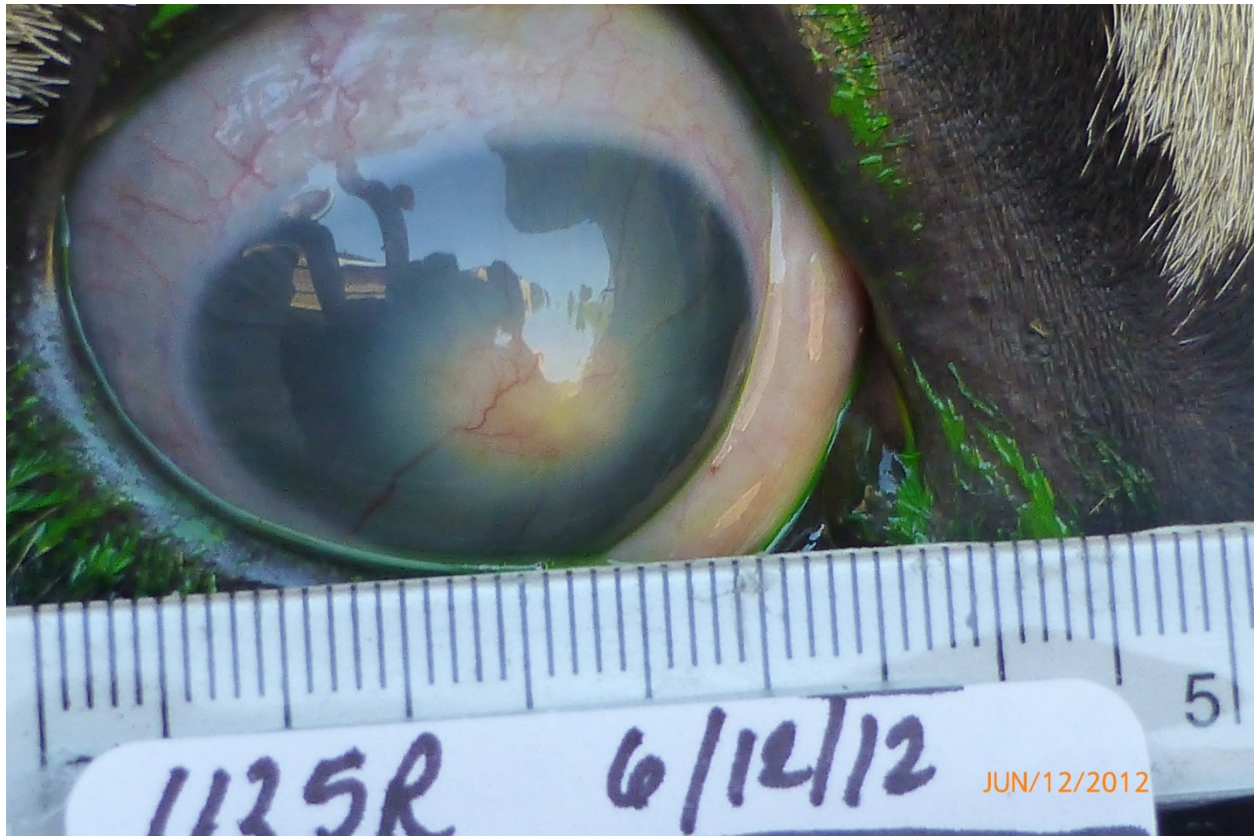


Fig. 10. Progression of corneal healing following perforation in a calf with IBK. The photographs depict a 77 day timeframe. The calf was treated with florfenicol (40 mg/kg SC) on day 0 when the ulcer was first identified. Although the globe healed, the calf was permanently blind in the affected eye.

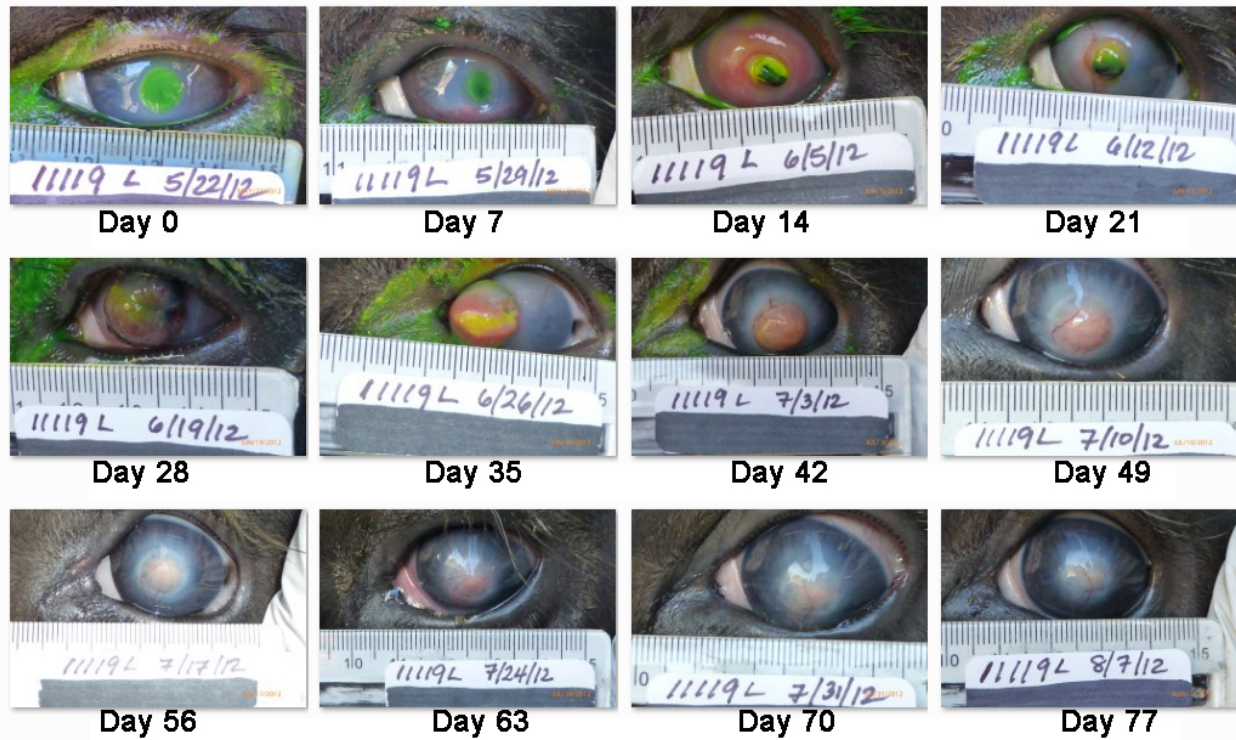


Fig. 11. Eyes of calves with severe ocular inflammation following the development of IBK and likely rupture of the globe. Panels A and B represent 2 different calves with lesions described by producers as ‘popeyes’. Panels C, D, and E represent the calf depicted in panel B during the subsequent 3 weeks at each weekly interval. This calf received florfenicol treatment (40 mg/kg SC) one time on the day that the photo in panel B was taken.

