

UCLA

UCLA Electronic Theses and Dissertations

Title

Effects of a Novel Mini-Implant Assisted RPE in an Early and Late Treatment Group

Permalink

<https://escholarship.org/uc/item/88x5s9xq>

Author

Boersma, Elise

Publication Date

2014

Peer reviewed|Thesis/dissertation

UNIVERSITY OF CALIFORNIA

Los Angeles

Effects of a Novel Mini-Implant Assisted RPE in an
Early and Late Treatment Group

A thesis submitted in partial satisfaction
of the requirements for the degree Master of Science
in Oral Biology

by

Elise Boersma

2014

© Copyright by

Elise Boersma

2014

ABSTRACT OF THE THESIS

Effects of a Novel Mini-Implant Assisted RPE in an
Early and Late Treatment Group

By

Elise Boersma

Master of Science in Oral Biology

University of California, Los Angeles, 2014

Professor Kang Ting, Chair

Objective:

The aim of this clinical pilot study is to see if a novel mini-implant assisted rapid palatal expander (MARPE) has similar dental and skeletal treatment effects in an Early Treatment Group (ETG) and a Late Treatment Group (LTG) through the use of Cone Beam Computed Tomography (CBCT) analysis.

Methods:

Orthodontic patients requiring MARPE were asked to participate in a clinical study. A pilot study consisting of ten patients were grouped into an ETG or LTG according to their Cervical Vertebral Maturation Stage (CVMS). Five patients with CVMS stage 1-4 were placed in the ETG, and 5 patients with CVMS stage 5 were placed in the LTG. CBCTs were taken for initial records (T0), immediately after expansion (T1), and

6 months after expansion was complete (T2). Skeletal versus dental effects, and palatal volume were measured between T0, T1 and T2, and between groups, using Dolphin Imaging and itk-SNAP.

Results:

Similar results were seen between groups for all the skeletal outcomes except at NW, BBW, TDTZ from T1-T0, Basal Bone Width and Buccal bone width at 14mm from T2-T1, and MW, and TDTZ from T2-T0, where these measures showed statistical significance between groups. The ratio of mid-palatal suture opening at M1 and expansion width in the appliance at T1, was 69% in the ETG and 34% in the LTG. There was 6° of dental tipping in the LTG, and 1° of tooth uprighting in the ETG after expansion. Buccal bone width at both 11 and 14 mm decreased during expansion, and then increased during the retention phase in both groups. Palatal volume increased following expansion, with a slight decrease during the retention phase. In the ETG there was 61% skeletal expansion, 10% bone bending and 29% dental tipping, compared to 34% skeletal expansion, 4% bone bending, and 62% dental tipping in the LTG.

Conclusion:

The use of a novel MARPE has overcome the limitations of a traditional tooth-anchored appliance, allowing force to be directed adjacent to the mid-palatal suture, opening up the suture and achieving true skeletal expansion in a late treatment group. This pilot study has shown significant differences in certain measures between the ETG and LTG, however increasing our sample size will determine if there is a true difference between groups.

The thesis of Elise Boersma is approved.

Kiho Lee

Reubin Kim

Sanjay Mallya

Kang Ting, Committee Chair

University of California, Los Angeles

2014

DEDICATION

I would like to dedicate this master's thesis to my family, especially my parents, who have supported me throughout my life as a student, and especially during these past three years as I pursued my dream to become an orthodontist. Dad, thanks for being the role model that every daughter wants and deserves. Your hard work and dedication has inspired me to be the best person I could be, and without your encouragement I wouldn't be where I am today. Mom, your patience and self-less nature were always comforting during my times of stress, and every day I strive to be more like you. I hope one day I can repay you for all the opportunities you've allowed me to experience. I'm truly blessed to have such amazing parents, but also even more blessed to call you both my best friends.

TABLE OF CONTENTS

Introduction.....	1
Literature Review: Background and Significance	2
What is Palatal Expansion.....	2
Suture Histology	3
History of Expansion	3
Skeletal and Dental Effects of Conventional Expansion	4
Bone Anchored Palatal Expansion	7
Cone Beam Computed Tomography	9
Treatment Timing.....	10
Design and Methodology.....	13
Patient Selection and Grouping.....	13
MARPE Design	13
Expansion Protocol.....	14
Stopping Rules.....	15
CBCT	15
CBCT Orientation	16
Measurements	18
Palatal Volume.....	24
Computer Software	26
Statistics	26
Results	27
Discussion.....	32
Conclusion.....	44
Figures.....	48
Tables.....	51
References	56

LIST OF FIGURES

Figure 1: Cervical Vertebral Maturation Stages

Figure 2: Novel MARPE Expander

Figure 3: CBCT Orientation – Coronal, Sagittal, Axial

Figure 4: IOW, ZW, UCA Measurements

Figure 5: Linear Measurements

Figure 6: BBW, ABH Measurements

Figure 7: Buccal and Palatal Cusp Extrusion

Figure 8: Bone Bending and Dental Tipping

Figure 9: Midpalatal Suture Measurements

Figure 10: Defining the Region of Interest for Palatal Volume

Figure 11: Palatal Volume 3D Construction

Figure 12: Correlation of Mid-palatal Suture Opening at M1 and Expansion Screw Width

Figure 13: Correlation of M1/EW to Age

Figure 14: Correlation of M1/EW to CVMS

Figure 15: Correlation of Dental Tipping and Mid-palatal Suture Opening at M1

Figure 16: Correlation of Bone Bending and Mid-palatal Suture Opening at M1

LIST OF TABLES

Table 1: Rapid Palatal Expansion Literature Summary

Table 2: Surgically Assisted Rapid Palatal Expansion Literature Summary

Table 3: Age, CVMS, Expansion Time and Time between CBCT's

Table 4: Expansion Width and Mid-palatal Suture Opening Changes

Table 5: Intraorbital Width and Zygomatic Width Changes

Table 6: Nasal Width, Maxillary Sinus Width, and Nasal Floor Width Changes

Table 7: Basal Bone Width, Alveolar Bone Width, and Interdental Width Changes

Table 8: Bone Bending and Dental Tipping Changes

Table 9: Buccal and Palatal Cusp Extrusion

Table 10: Changes in Buccal Bone Width at 11mm and 14mm

Table 11: Alveolar Bone Height Changes

Table 12: Changes in Upper Incisor Angulation

Table 13: Changes in Palatal Volume

INTRODUCTION

The first reference to the use of orthopedic expansion to correct a transverse discrepancy was in 1860, when E.H. Angell used a jackscrew placed between the maxillary premolars in a 14 year old girl.¹ After two weeks of turning the jackscrew, he noticed the widening of the upper jaw and spacing between the upper incisors, and concluded that he had indeed separated the two halves of the maxillary bone. From then on, many types of expansion devices have been designed and used, and research on the effects of expansion to correct a transverse discrepancy, has been carried out.

The incidence of a maxillary transverse discrepancy ranges between 8 to 18% in the deciduous and mixed dentition, presenting as a unilateral or bilateral crossbite.² When a patient presents with a transverse discrepancy as a young child or early teen, conventional palatal expansion is most often employed. Palatal expansion in a younger age group results in mainly skeletal expansion with opening of the mid-palatal suture, and a small amount of bone bending and dental tipping.^{3 4} Patients presenting after their peak growth and late in their teens or early twenties, however are usually treated with surgically assisted palatal expansion also known as SARPE.² Studies using rapid palatal expansion in older patients have shown skeletal suture opening, however more dentoalveolar effects occur, and usually only successful cases are reported.^{3 4} With the introduction of mini-implants into the orthodontic armamentarium in the 1980's, the orthodontists' ability to correct skeletal and dental discrepancies, without surgical intervention, has greatly improved. The use of mini-implants to assist with palatal expansion has reduced the need for surgically assisted expansion in some clinical cases.

New technology in orthodontics has allowed us to push the envelop in treating more difficult orthodontic cases, and has allowed us to gain more insight into the true effects of orthodontic procedures.

The use of cone beam computed tomograms (CBCT's) in research, allows us to visualize the human skull as a 3D image, and observe treatment effects in three planes of space. CBCTs provide excellent resolution and eliminate the difficulty of identifying structures due to anatomical superimpositions commonly seen in 2D films. With the design of a novel mini-implant assisted rapid palatal expander (MARPE), the aim of this study is to compare the amount of skeletal versus dental effects, and volumetric changes using CBCT analysis, and to determine if MARPE has the same treatment effect, in both an early and late treatment group.

LITERATURE REVIEW: BACKGROUND AND SIGNIFICANCE

WHAT IS PALATAL EXPANSION

The maxilla is one of the main skeletal structures that make up the craniofacial complex. The bones of the craniofacial complex connect with one another through sutures, which are areas of intramembranous growth.⁵ The maxilla is divided in two parts by the mid-palatal suture, into a right and left half.

Sutures are composed of two osteogenic surfaces, with a central area consisting of fibrous tissue, which is mainly collagenous, and where rapid synthesis and turnover occurs.⁶ With age, this fibrous component becomes more dense and thick, and the fiber bundles run transversely across the suture increasing its strength.⁶ Therefore, as we age the mid-palatal suture becomes more difficult to open. And as we complete our peak in pubertal growth, growth starts to slow down and eventually cease in these areas.⁷

During palatal expansion we force the suture open, creating space between the two maxillary bones. Early orthodontic treatment mainly focuses on correction of the transverse dimension, because as we age it becomes more difficult to open the suture.⁶ Difficulty and resistance to expansion not only comes from

the interdigitated fibrous mid-palatal suture, but also from other areas, such as the piriform aperture pillars, the zygomatic buttress, and the pterygoid junctions.^{2 8}

SUTURE HISTOLOGY

Histological research in 1975 by Melson looked at tissue blocks of the maxilla, removed at autopsy, in 33 boys and 27 girls between the age of 0-18. He observed that the suture morphology undergoes 3 stages. From 0 to 10 years of age the suture is y shaped, and is broad and sinuous, between the age of 10 to 13 years, it develops into a squamous suture, and the two palatine bones begin to overlap with some interdigitation. After the age of 13, during the adolescent stage however, the suture became wavy and interdigitation increased. He also found that osteoblastic activity in the midpalatal suture ceased in girls at the age of 15 and at the age of 17 in boys.⁹

In 2001, research from the University of Brussels compared radiological and histological findings of palatal specimens from 10 subjects, ranging in age from 18-38 years. What they found was that if the suture was invisible radiographically, histologically there was inter-digitation, however the percentage of suture obliteration was low, and therefore complete suture fusion was not evident in these older subjects as was previously thought.¹⁰

HISTORY OF EXPANSION

Expansion of the mid-palatal suture was first introduced for correction of a narrow maxilla in the 1860's by E.H, Angell.¹ The purpose of palatal expansion was to correct a narrow maxilla, and to increase the amount of space to relieve crowding in the arch.^{6 11} Research has shown that about 8-23% of children and 10% of adults have a narrow maxilla, which requires some form of widening or expansion.^{4 6}

The concept of rapid palatal expansion came about in the last half of the twentieth century by Andrew Haas.¹² The reason for the introduction of rapid palatal expansion, which involved turning the expansion screw 1-2x per day, was to maximize the skeletal effect causing the mid-palatal suture to open, minimizing tooth tipping and translation of the teeth outside the alveolar bone that surrounds the teeth.⁶ The theory was that rapid expansion would create a greater force that would be rapidly transferred from the tooth to the mid-palatal suture, resulting in a greater suture expansion and less tooth tipping.^{6 12} However, what they found was that after expansion and during the retention phase, the two bony halves of the maxilla relapsed slightly and the teeth were held in their expanded position.⁶

Slow palatal expansion, which involves turning the expansion screw 1-2x per week, results in both skeletal and dental expansion, however the expansion rate is slower and allows the tissues to adapt to the force from expansion. The amount of dental and skeletal expansion at the end of treatment is similar to that seen in the retention phase with rapid palatal expansion, when relapse of the suture opening occurs. Therefore both slow and rapid expansion have similar treatment outcomes.⁶

For patients who are considered too old for conventional expansion, a surgical procedure is performed, called surgically assisted rapid palatal expansion (SARPE). SARPE consists of a LeFort I Osteotomy, where the maxilla is sectioned from the skull base, and then a cut is made along the mid-palatal suture between the two halves of the maxilla. This procedure is invasive, but has been the treatment of choice for adults, due to its ability to achieve expansion of the upper jaw and greater stability, with less dental side effects such as dental tipping that would be expected when using a conventional RPE in an older patient group.

SKELETAL AND DENTAL AFFECTS OF EXPANSION

Past studies have shown that when expanding, the mid-palatal suture expands in a wedge shape, with the greatest increase in the central incisor region and the least in the first molar region.¹³ Not only was there more anterior suture opening, but there was significantly more inferior versus superior opening that occurred with expansion.^{1 7 13 14 15}

Early research on rhesus monkeys showed that expansion resulted in tipping of the buccal segments, with the rotation of the two halves of the maxilla around the mid-palatal suture, and dropping of the nasal and palatal floor. The palatal process, alveolar process and teeth, rotated as a unit and there was no observation of dental tipping.⁷ In 2008, Garrett et al¹⁴ looked at the skeletal effect of rapid palatal expansion using a conventional Hyrax expander and CBCT analysis. CBCT's were taken before, and then 3 months after expansion, to evaluate the amount of skeletal expansion versus dental tipping or bone bending. After 5mm of expansion, they found that at the first molar region there was 38% skeletal expansion, 13% bone bending and 49% orthodontic tipping. They observed that skeletal expansion occurred in a wedge shape with more suture opening in the anterior region and less in the molar region, which is consistent with previous studies. This wedge shape expansion was thought to be due to the restriction from the pterygoid plates, zygomatic process, and circummaxillary sutures.^{14 16} Not only did the mid-palatal suture expand in a wedge shape, but there was greater expansion of skeletal structures inferiorly than superiorly, with the center of rotation being located at the frontonasal suture.¹⁷ It was initially thought that the mid-palatal suture itself was the area of greatest resistance to expansion. Over the years, further research has found that the zygomatic buttress, pterygomaxillary junction, and the pterygoid plates provide the greatest resistance to expansion in the posterior region.^{1 2 16} FEM studies have also confirmed that the maximum stresses observed during RPE are at the frontomaxillary, nasomaxillary and frontonasal sutures.^{18 5} Computed tomography analysis of circummaxillary sutures after RPE showed the greatest increase in width at the intermaxillary suture and internasal suture, followed by

the nasomaxillary suture.¹³ Therefore, during expansion, not only is the midpalatal suture opened, the force from expansion can be displaced to the circummaxillary sutures, resulting in suture opening.

Some of the limitations with tooth anchored or conventional expansion is the limited skeletal expansion, and the dental tipping which can lead to recession and potential dehiscence and fenestrations, by tipping the teeth through the buccal alveolar bone.^{4 6 19 20} Fixation of the appliance to the teeth can lead to unwanted effects such as dental tipping, and buccal cortical plate resorption, in the form of a fenestration or dehiscence, which can eventually lead to gingival recession.²¹ In the evaluation of alveolar bone height and buccal bone width following conventional expansion using CBCT, Baysal et al²⁰ found that buccal alveolar bone height was significantly reduced following expansion however, after 6 months of retention, the change in alveolar bone height wasn't statistically significant. They also found a variation in the incidence of dehiscence, ranging from 2.5% to 55%, with an increasing incidence of dehiscence and decreasing incidence of fenestration after RPE.²⁰ Other studies have reported recession occurring on only 2% of buccal alveolar bone sites which was limited to only .25 to 1mm of bone loss.⁴ However, all these studies involve conventional RPE.

When conventional expansion is used in older patients, there tends to be more mixed results, with evidence of suture opening in some, and minimal suture opening in others. A study looking at expansion in older patients, reported one case of a 16 year old female that showed diastema opening of 0.5mm, however radiographically, there was no evidence of suture opening.¹⁵ A similar study looking at the use of a Haas expander in an older patient group, with subjects 18 years or older, resulted in 6 degrees of dental tipping of the molars, and 8 degrees increase in the palatal angle. They also observed that there was 0.5mm of gingival attachment loss in older females compared to males.⁴ Their conclusion was that RME in adults was clinically successful and safe.

BONE ANCHORED PALATAL EXPANSION

Bone anchored appliances, where mini-implants or implant screws are used to anchor the appliance to the maxillary bones, were first incorporated into the field of orthodontics in the 1990's. The Transpalatal distractor, the Magdenburg palatal distractor, the Dresden distractor, and the Rotterdam palatal distractor, were just a few of the bone anchored appliances being used at that time and are currently still used today.^{2 22} These earlier bone anchored appliances were designed to reduce the dental side effects seen with conventional expansion devices, and maximize the orthopedic effect with suture opening.²¹ Some of these devices however, use a large implant and self tapping bone screws, which requires a surgical procedure to be placed which can be an invasive procedure, resulting in an increased risk of surgical morbidity.

Twelve patients with an average age of 25.3 years, who had a Dresden distractor placed, combined with surgically assisted expansion, showed 8-9.8° of alveolar process tipping and 1.1-2.6° of tipping at the molar region.²³ With the use of surgically assisted expansion, you would expect the resistance to expansion to be reduced, resulting in true skeletal expansion, with no bone bending or dental tipping. However, in this study there was still significant alveolar bone bending and a small amount of dental tipping. When the researchers published their updated findings in 2010, with a total of 18 subjects undergoing surgically assisted RPE with the Dresden Distractor, they reported bone bending and tipping of the two halves of the maxilla but also tooth uprighting.²⁴ If we look at the use of a 4 banded RPE and surgically assisted expansion, there was approximately 1-8° of dental tipping. Therefore, the use of a tooth borne appliance tends to cause more dental tipping, while the bone borne appliance allows for tooth uprighting during expansion with less dental tipping. However, because these studies both look at SARPE we cannot expect to see these results in our study.

With the introduction of mini-implants or temporary anchorage devices (TADs) in the 1980's, the orthodontist's ability to treat more difficult cases without surgical intervention and surgical side effects became a possibility. Mini-implants are small screw like titanium rods, ranging in dimension from 1.3-1.5mm in diameter, and 6-11mm in length, that anchor in the bone with approximately 75% osseointegration.²⁵ The use of mini-implants as a non-invasive means to anchor an appliance to the palate and direct the force to the midpalatal suture became possible, and has since been used to correct transverse discrepancies in an older patient group.

Mini-implant assisted rapid palatal expansion (MARPE) is a new technique in rapid palatal expansion where mini-implants are used to fixate the expansion appliance to the maxillary palatal bones. A force is generated when the expansion screw is turned, which then passes to the mini-implants, and then to the palatal bone, which lies adjacent to the mid-palatal suture. This force thereby acts to break open the interdigitation of the mid-palatal suture between the maxillary palatal bones. There is limited research in this appliance system, however a case study using a banded MARPE on a 20 year old male patient showed correction of a transverse discrepancy with excellent stability after orthodontic treatment.²⁶

A randomized control trial published in 2010 looked at 62 patients needing maxillary expansion.¹⁹ These patients with a mean age of 14, were placed into 3 groups, a traditional hyrax with bands on the U6's and 4's, a bone anchored expander, and a control group. In the bone-anchored group, mini-implants were placed between the U6's and U5's, 6mm from the mid-palatal suture. CBCT's were used to measure and compare the dental and skeletal effects of expansion. What they found was that dental expansion was greater than skeletal expansion for both appliances and that there was more dental tipping and vertical changes at the first molar region. The tooth-anchored expander produced more tooth tipping and dental expansion at the first premolar region, which was most likely due to bands being placed on the premolars.

Overall the conventional expander and the mini-implant expander showed similar results in this age group.¹⁹ We need to ask ourselves what are the effects in an older patient group and what would happen if we eliminated the use of bands on both the premolars or molars? Would the MARPE produce the same skeletal and dental effects in a younger and older patient group?

CONE BEAM COMPUTED TOMOGRAPHY (CBCT)

With the introduction of CBCT, a rendered three dimensional (3D) image is created from stacks of two dimensional slices, allowing us to visualize and diagnose pathology, and treatment plan accordingly.²⁷ Not only can we use CBCTs for diagnosis and treatment planning in orthodontics, but it is also a great tool for evaluating overall treatment effects. The use of a CBCT to analyze treatment effects overcomes the limitations that occur with a 2D cephalometric radiograph, such as errors in projection, landmark identification and measurement errors.^{28 29} Since there are currently no specific cephalometric landmarks in three planes of space, measurements were taken in a 2D sagittal, coronal or axial slice.²⁷

The Newtom 5G (Aperio Services, Verona, Italy) is the current CBCT machine used here at the UCLA School of Dentistry Radiology Department. The Newtom 5G machine employs “Safe Beam” technology”, which means that it automatically adjusts the radiation dosage according to the patient's anatomic density, so that milliampere values fluctuate with a maximum of 15mA. This technology utilizes intermittent bursts of radiation only milliseconds in duration during image acquisition, and not the constant radiation stream typical of many other CBCT imaging machine's, therefore patient exposure to radiation is significantly less.³⁰ The maximum dose of radiation a patient can receive per year is 3.1 milisyverts.³¹ There are approximately 1000 microsyverts in 1 millisyvert. With a Newtom 5G a patient receives 50-100 microsyverts, depending on the size of the patient. This is less radiation than what is received from a CT scan or iCAT CBCT machine. However, with the Newtom's safe beam technology the patient

approximately receives 30-60 microsyverts per scan. This is 4-7 times greater than a panograph, which is prescribed every 6 months in orthodontics, and is comparable to a full mouth series of 24 small dental films of the whole mouth. Due to the CBCT's superior imaging and diagnostic capability, this imaging modality is becoming more popular for initial diagnosis and for evaluating treatment progress in orthodontic patients.³⁰

TREATMENT TIMING

In dentistry, chronological age is not always a good indicator of skeletal age. For orthodontic treatment involving orthopedic correction, a patients' skeletal age can influence the success of orthopedic correction, most specifically in the transverse dimension. Determining a patients' maturational stage gives insight into a patients' growth potential, which will ultimately effect how a patient responds to orthodontic treatment, such as mid-palatal expansion. A way of assessing a patients' skeletal maturity and growth potential is through the shape and concavities of the cervical vertebrae. Based on earlier research in cervical vertebrae and maturational changes, in 1972 Don Lamparski created the cervical vertebral maturation method.³² Since the 1970's, this method has been investigated and further research has revised the cervical vertebral maturation method. Within the past decade this has become the more popular technique to determine a patients stage and potential for growth, with studies confirming it's reliability being similar to the traditional hand wrist method.³³ The new cervical vertebral maturation (CVM) method described by Baccetti, identified five stages of cervical vertebral maturation which can be determined by examining the bodies of the second, third and fourth cervical vertebrae (C2,C3,C4) on a lateral cephalogram.^{12 33}

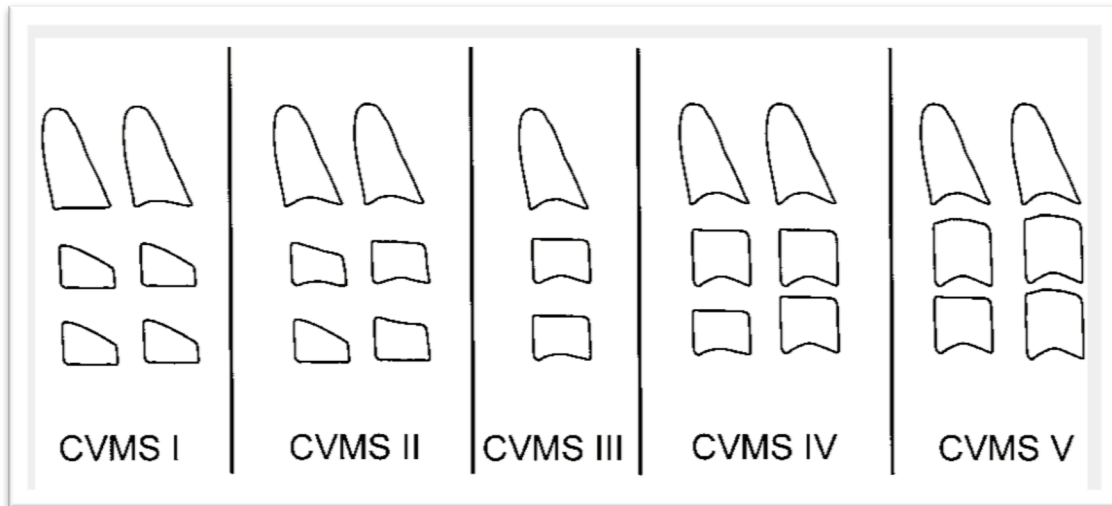


Figure I: Cervical Vertebral Maturation Stages ³²

The stages of vertebral maturation and the correlating stage of craniofacial growth are described below and quoted from the 2002 Baccetti et al. article ³²:

CVMS I: The lower borders of all the three vertebrae are flat, with the possible exception of a concavity at the lower border of C2 in almost half of the cases. The bodies of both C3 and C4 are trapezoid in shape (the superior border of the vertebral body is tapered from posterior to anterior). The peak in mandibular growth will occur not earlier than one year after this stage.

CVMS II: Concavities at the lower borders of both C2 and C3 are present. The bodies of C3 and C4 may be either trapezoid or rectangular horizontal in shape. The peak in mandibular growth will occur within one year after this stage.

CVMS III: Concavities at the lower borders of C2, C3, and C4 now are present. The bodies of both C3 and C4 are rectangular horizontal in shape. The peak in mandibular growth has occurred within one or two years before this stage.

CVMS IV: The concavities at the lower borders of C2, C3, and C4 still are present. At least one of the bodies of C3 and C4 is squared in shape. If not squared, the body of the other cervical vertebra is still rectangular horizontal. The peak in mandibular growth has occurred not later than one year before this stage.

CVMS V: The concavities at the lower borders of C2, C3, and C4 still are evident. At least one of the bodies of C3 and C4 is rectangular vertical in shape. If not rectangular vertical, the body of the other cervical vertebra is squared. The peak in mandibular growth has occurred not later than two years before this stage.

In summary, the CVMS stage 1-2 indicates that the patient hasn't reached their pubertal growth spurt and peak in mandibular growth. When a patient is between CVMS stage 2 and 3, the individual undergoes their peak growth spurt, and at CVMS stage 4, the peak in mandibular growth has occurred around 1 year before this stage. By CVMS stage 5, there has been more than 2 years since their peak pubertal and mandibular growth.³² Despite the differing views on the age of suture closure, it seems that as the patient reaches puberty the suture becomes interlocked and interdigitated, reducing the ability of achieving maxillary skeletal expansion. Those patients past the pubertal growth spurt show more dental than skeletal changes with conventional RPE, thereby questioning if it is at all possible to achieve true skeletal expansion in adults.^{6 3}

DESIGN AND METHODOLOGY

PATIENT SELECTION AND GROUPING

Orthodontic patients from the UCLA Orthodontic graduate clinic, requiring mini-implant assisted RPE(MARPE) were asked to participate in the study (IRB #15-000054). The patients were selected to participate based on the attending faculties' decision to use MARPE, for correction of their transverse discrepancy. Selection criteria included: patients requiring expansion with a MARPE; who had initial diagnostic CBCT's; with no craniofacial anomalies; and whose treatment plan didn't involve extraction of teeth prior to expansion. The patients were fully informed of the nature of the study, the need for an additional CBCT post-expansion, and the use of their CBCT's to evaluate treatment effects. Patient consent, parental permission and or child assent were obtained based on the age of the patient participating.

Those patients who were willing to participate in the study were grouped into an Early Treatment Group (ETG) and Late Treatment Group (LTG) based on their Cervical Vertebral Maturation Stage (CVMS). Patients with CVMS stage 1 to 4 were placed in the Early Treatment Group (ETG), while patients with CVMS stage 5 were placed in the Late Treatment Group (LTG). Patients in the ETG had a mean age of 12.3 ± 1.8 years with a range of 10.2-14.4 years, while those in the LTG had a mean age of 20.4 ± 4.5 years, and ranged from 16 – 26.3 years.

MARPE DESIGN

A novel MARPE was designed with the exclusion of molar and premolar bands, to eliminate the potential dental side effects seen in previous MARPE and conventional expansion appliances. The design consisted of a central expansion screw with an extension arm on either side, extending to the right and left palatal surface of the upper first maxillary molar. At the end of the extension arm there was a C clasp that

encircled the palatal surface of the tooth, and an occlusal rest in the palatal groove, that acted as an occlusal stop. Four circular holes to house the four mini-implants and anchor the appliance to the maxilla were placed anterior and posterior, and on either side of the expansion screw, which also acted as guide holes for mini-implant placement. The location of the mini-implant holes allowed the mini-implants to be placed on the right and left palatine process' of the maxilla, adjacent to the mid-palatal suture, thereby directing the force during expansion to the mid-palatal suture, creating a true skeletal effect.

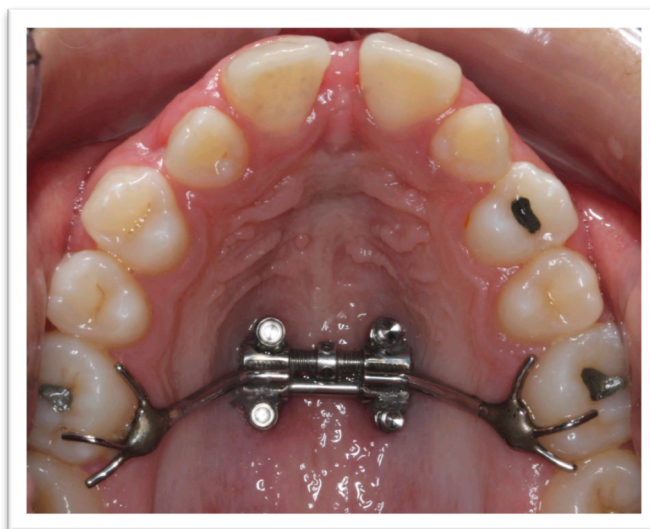

Figure 2: Novel MARPE Expander

EXPANSION PROTOCOL

Patients were instructed to turn the expansion screw one to two times per day until the palatal cusps of the upper first maxillary molar were in contact with the buccal cusp of the lower first mandibular molar, and when the attending faculty decided correction of the transverse discrepancy had been achieved. Following the completion of expansion, the arms of the expander were sectioned and the body of the expansion appliance remained in the mouth to function as a retention device for at least six months.

Removal of the arms would allow for the teeth to upright once expansion was complete. If the mini-implants failed, and the MARPE came loose before the 6 months retention period was complete, it was replaced with a transpalatal bar to maintain stability and prevent relapse.

STOPPING RULES

The study would be stopped and the protocol changed if:

1. More than half of the subjects report severe pain or discomfort from the activation of the appliance.
2. If during expansion, signs of gingival recession resulting in periodontal defects were evident due to excessive tipping of the teeth
3. If during use of the appliances it was determined that the design of the appliance needed to change, due to excessive dental tipping and side effects, or discomfort to the patient.
4. If the turning frequency of the expander needs to be increased or decreased to minimize discomfort or minimize dental side effects

CONE BEAM COMPUTED TOMOGRAPHY

CBCT's with a field of view of 18x16cm, an average scan time of 18 seconds, and an approximate dose of 50uSv to 100uSv, were taken with the patient in a supine position using the Newtom 5G (QR Systems, Italy) at the UCLA School of Dentistry Radiology Department. Images were converted to a DICOM (digital imaging and communications in medicine) format by using the NewTom software to a voxel size of 0.3mm. A 3D reconstructed image and sagittal, axial and coronal volumetric slices were used for landmark identification and measurements. CBCT scans were obtained from patients participating in a prospective clinical trial comparing a novel MARPE and conventional maxillary expansion treatment (IRB# 12-000054). The first CBCT was used for diagnostic purposes and is standard of care. The second CBCT

was non-standard of care and Medical Radiation Safety Committee (MRSC) approval was granted. This CBCT was taken after expansion was complete, to measure the skeletal versus dental effects seen with a novel MARPE appliance. The third CBCT was taken 6 months after expansion to measure stability and relapse following expansion, and is standard of care at UCLA Section of Orthodontics to evaluate orthodontic treatment progress.

CBCT ORIENTATION

The DICOM images were uploaded into Dolphin Imaging 11.5 Software (Dolphin Imaging). Once uploaded, each image was orientated into the appropriate x,y,z plane of space using a horizontal reference line. In the coronal view the horizontal line was drawn from the right and left Z point, which is the location of the frontozygomatic suture located on the lateral orbital rim. In the sagittal view, the horizontal line was drawn from Porion (the most superior surface of the external acoustic meatus) and Orbitale (the most inferior surface of the orbital rim). In the axial plane, with a view of the skull from below, the horizontal line was drawn from the right and left zygomaticotemporal suture. Once orientation of the CBCT was complete the reconstructed image was saved in this orientation for further analysis.

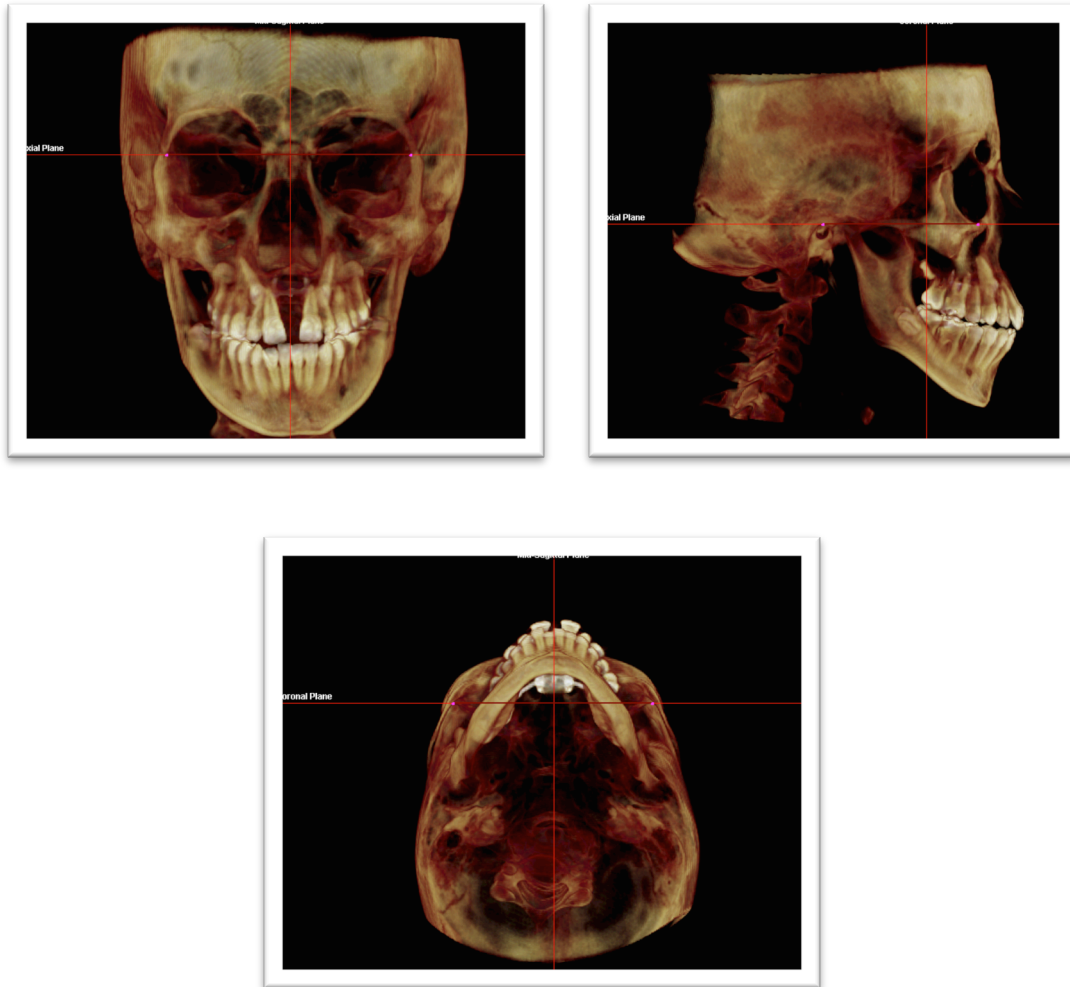


Figure 3: CBCT Orientation – Coronal, Sagittal, Axial

Two main slices were used to measure treatment effects; a coronal slice through the upper first maxillary molar, and an axial slice to measure mid-palatal suture opening. For measurements taken at the first molar region, the coronal image was first orientated so that the coronal slice was taken between the distal buccal roots of the first maxillary molars. Due to the variation in bone thickness of the mesial buccal root of the first maxillary molar it was decided to use the distal buccal root as the main area of reference. If the distal buccal roots were not orientated in the same plane, the image was rotated so that the middle of each distal buccal root was located on this coronal view. For angular measurements of the palatal roots

and palatal bone, the coronal slice bisected the middle of the palatal roots of the first maxillary molars. Orientation in the axial plane was adjusted to achieve this view in the coronal slice.

MEASUREMENTS

The sagittal, axial, and coronal volumetric slices as well as the 3D reconstructed image were used for landmark identification and to record the following measurements. Linear and angular measurements were made to the nearest 0.1mm and 0.1 degree. From a coronal slice taken directly between the distal buccal roots of the upper first maxillary molar. The following parameters were measured:

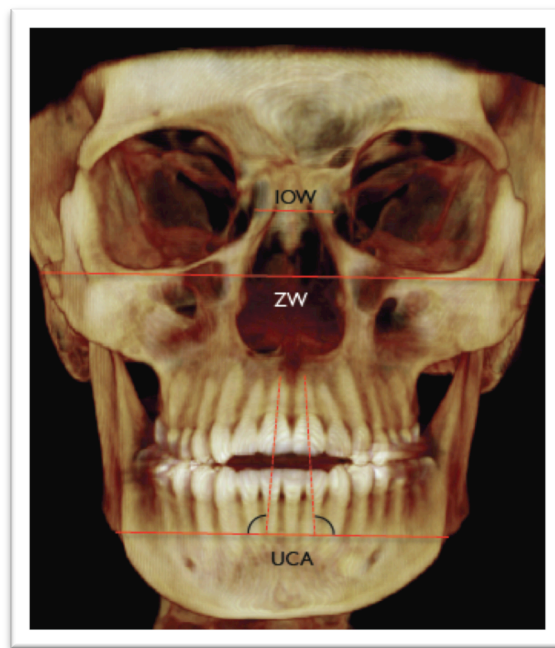


Figure 4: IOW, ZW, UCA Measurements

Inner Orbital Width (IOW)= the distance between the most concave point of the medial surface of the orbital rim from the left and right orbital rim using the 3D reconstructed image.

Zygomatic Width (ZW)= the distance from the most convex point of the zygomatic bone using the 3D reconstructed view.

Upper Central Incisor Angulation (UCA)= a reference line drawn from the right and left antegonial notch of the mandible, is the angle formed from a line running parallel to this reference line and a line running from the mid-point of the incisal edge through the apex of the central incisor using the 3D reconstructed view.

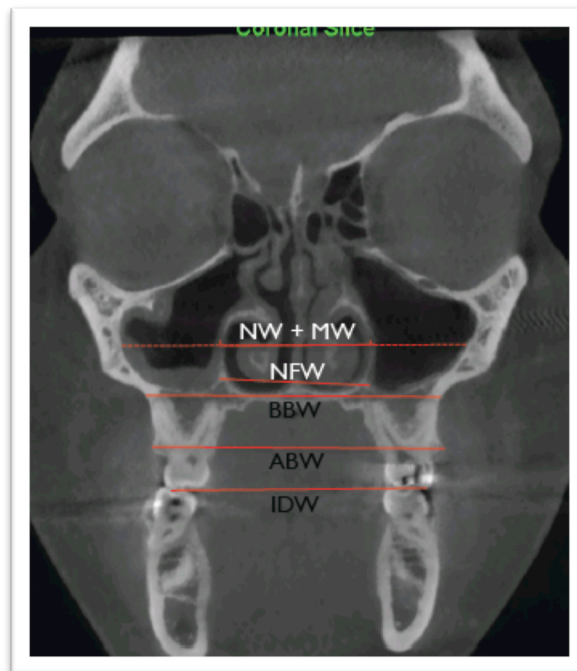


Figure 5: Linear Measurements

Nasal Width (NW)= the distance between the widest transverse portion of the nasal aperture.

Maxillary Sinus Width (MSW)= the distance between the widest transverse distance of the L and R maxillary sinus using the nasal width (NW) line as the reference line.

Nasal Floor Width (NFW)= the distance between the widest transverse portion of the nasal floor at the most inferior border of the nasal aperture.

Basal Bone Width (BBW)= the distance between the most concave region or point on the basal bone region at the first maxillary molar region formed by the intersection of the superior lateral border of the maxilla and the zygomatic buttress.

Alveolar Bone Width (ABW)= the distance between the most convex point on the alveolar bone located at the upper first maxillary molar from left to right.

Interdental Width (IDW)= the distance between the Distal Buccal cusp tip on the upper right to left maxillary first molar.

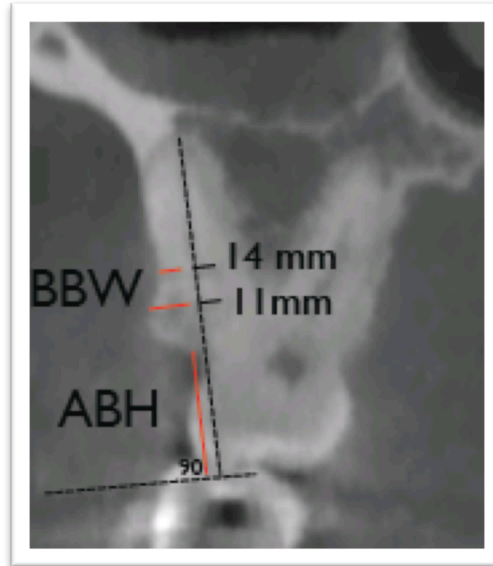


Figure 6: BBW, ABH Measurements

Buccal Bone Width (BBW)= is the amount of buccal bone measured in millimeters along the distal buccal root of the upper first maxillary molar. A line was drawn from the DB cusp tip of the U6 to the apex of the Distal Buccal root. A 90 degree angle was then drawn along this line and extended laterally. This laterally extended line acts as a reference plane when measuring the buccal bone. Buccal bone width was measured at 11mm and then 14mm from the Distal Buccal cusp tip on both the right and left side.

Alveolar Bone Height (ABH)= is the distance from the reference line to the height of alveolar bone. The reference line being a line that runs perpendicular to a line that runs from the distal buccal cusp tip through the distal buccal root apex of the first maxillary molar.

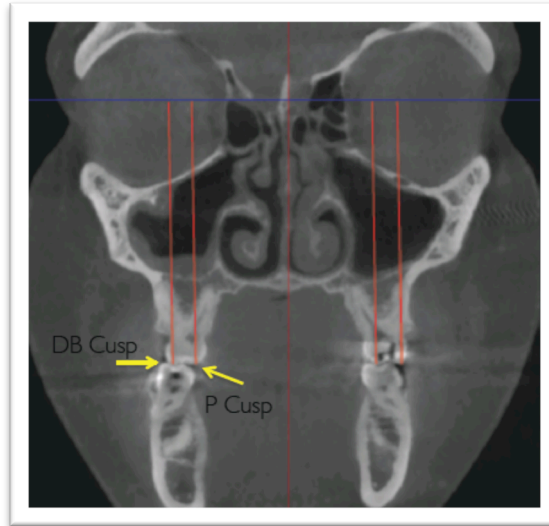


Figure 7: Buccal and Palatal Cusp Extrusion

Extrusion= the distance from the distal buccal and palatal cusps of the first maxillary molar to a line that connects the right and left Z points (zygomaticofrontal suture). It measures the amount of dental extrusion of the upper first maxillary molars that can result from dental tipping or bone bending.

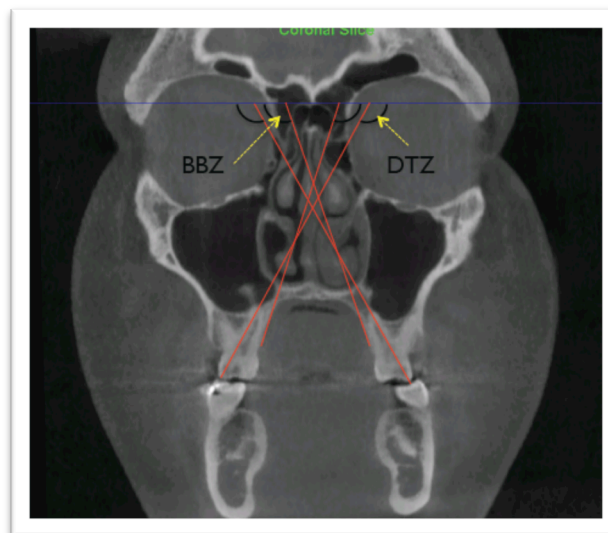


Figure 8: Bone Bending and Dental Tipping

Dental Tipping= using a horizontal line running along the middle of the floor of the nasal cavity and along the Z point reference line, an angle was formed from the distal buccal cusp tip through the apex of the palatal root to the reference line. This measurement was taken on the right and left side and combined as total dental tipping.

Palatal Bone Bending= using a horizontal line running along the middle of the floor of the nasal cavity and along the Z point reference line, an angle was formed from a best fit line running along the lateral surface of the palatal processes of the maxilla to the reference line. This measurement was taken on the right and left palatal surfaces and combined as total bone bending.

The following linear measurements were taken using an axial slice:

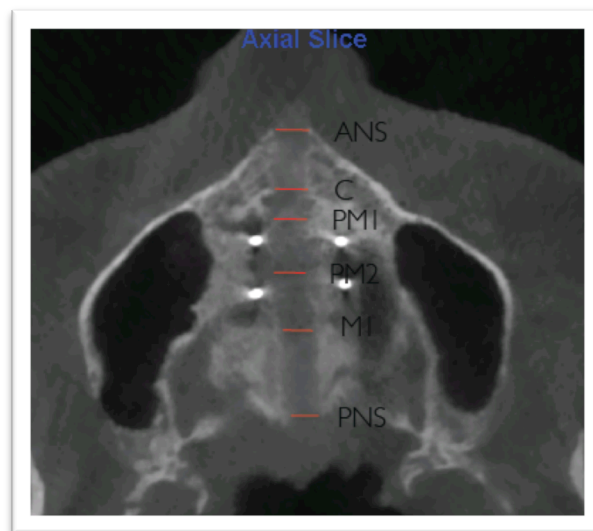


Figure 9: Midpalatal Suture Measurements

Midpalatal Suture Width= is the distance from the outer cortical surface of the midpalatal suture at the width of the anterior nasal spine(ANS), canine(C), 1st premolar (PM1), second premolar (PM2), first molar (M1) and the posterior nasal spine(PNS) using an axial slice.

The expansion appliance itself was measured from the left and right side of the inner surface of the expansion appliance using a Boley guage recorded to the nearest tenth of a millimeter.

PALATAL VOLUME

Palatal volume was calculated through the use of a freeware 3D segmentation software, itk-SNAP.³⁴ The DICOM file was uploaded into itk-SNAP and the area of interest, was highlighted and sectioned from the larger image. The volume of the palate was defined inferiorly by a line extending parallel to the CEJ of the upper central incisor, the posterior border was defined by a line running down from the most posterior point of the posterior nasal spine (PNS), the anterior border was defined by the cortical border of the anterior part of the palatal alveolar bone, and the superior border was the outer cortical border of the roof of the palate.

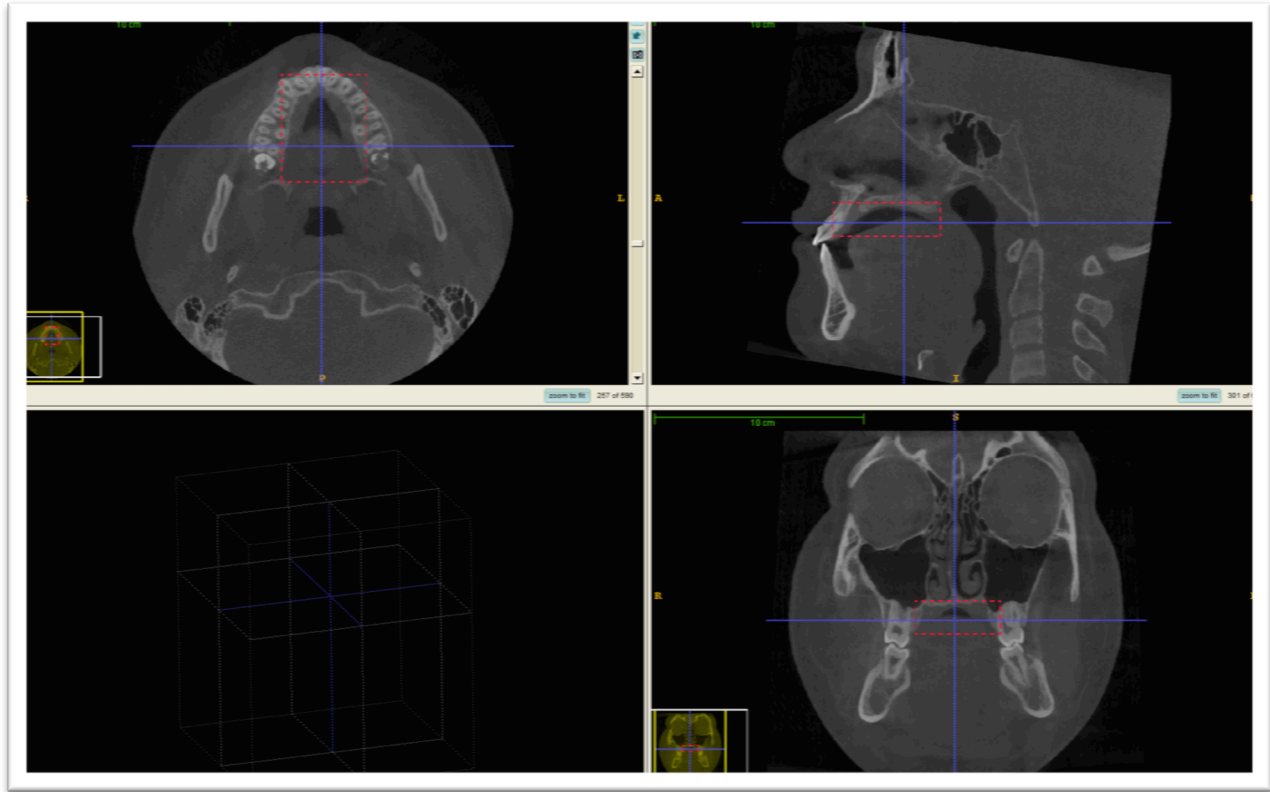


Figure 10: Defining the Region of Interest for Palatal Volume

Once the area of interest was defined, automatic segmentation using image edges with the ability to change edge contrast, were used to calculate the palatal volume. Refinement of the palatal volume was needed to remove areas that had extended beyond the threshold intensity into the nasal cavity or through the opening of the midpalatal suture. Refinement was completed using the paintbrush tool to extract those areas that were not of interest.

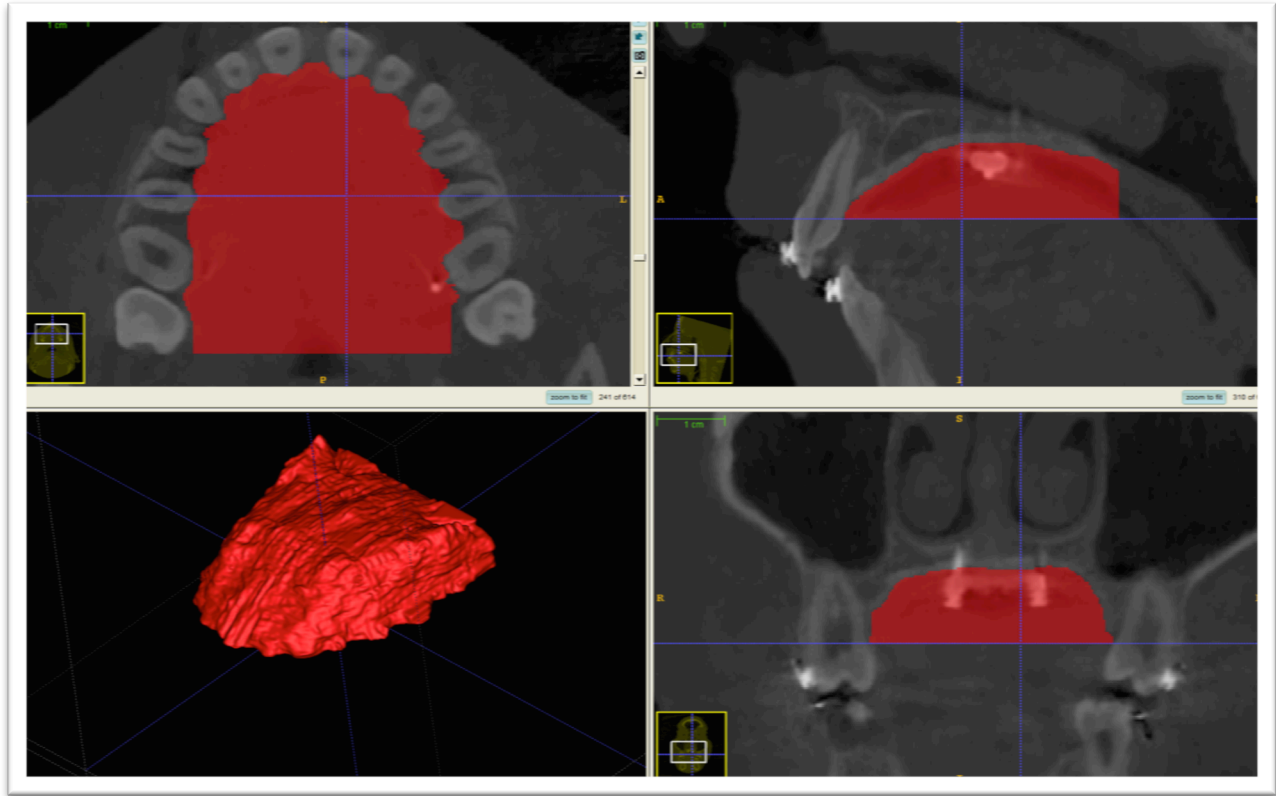


Figure 11: Palatal Volume 3D Construction

COMPUTER SOFTWARE

All angular and linear measurements were measured on CBCT's 3D rendered image, and on a coronal, or axial view using Dolphin Imaging. Volumetric calculations were performed using itk-SNAP freeware.

STATISTICS

Comparisons between T1-T0, T2 -T1, T2 -T0 were made using the t-Test. Due to the small sample size in T2, ANOVA between T0,T1, and T2 was not calculated. Measurements were taken and recorded by two examiners, and recorded twice with no less than 48 hours between measurement recordings.

Reliability of measurements within and between raters was evaluated in two ways. First by computing the

coefficient of variation (CV), and the second way by computing the intra class correlation coefficient (ICC). A CV has perfect reliability when it is close to 0. At this point the measurements are said to be the same between raters and within raters. An ICC close to 100% would show excellent reliability between and or within raters within patients. Linear regression analysis using Pearson and Spearman correlation were used for each group between T1 and T0 to see if there was an association among variables. The significance level of $\alpha=0.05$ was used for all statistical analyses.

RESULTS

Intra-rater and inter-rater reliability was measured, and the coefficient of variation for 13 of the 23 measures was <5%, with only one of the measures being as high as 16.6%. Therefore, the variability due to measurement error is <5% in most cases which is excellent reliability, with one measure being at 16%. Almost all measures have an intra class correlation coefficient of at least 80%, indicating that the measurement methods were reliable and reproducible between patients, and between and/or within raters, and within patients. An ICC near 100% means excellent reliability and in this study reliability of 80% is good to excellent for most measures.

As part of a pilot study, 12 subjects consented to participate in the MARPE study group, however one subject was lost to follow-up, and in one subject expansion failed to open the mid-palatal suture. Of the 10 subjects remaining, 5 were grouped into an ETG and 5 in a LTG based on their CVMS stage. In the ETG subjects, CVMS stage ranged from 3-4, with the subjects being within their growth peak or no more than one year past their peak in growth. In the LTG, all subjects were in CVMS stage 5, and therefore they were more than 2 years beyond their peak in growth. In the ETG, 4 of the subjects were female and one was male with an average age of 12.3 +/- 1.9 years. In the LTG, 3 of the subjects were female and 2 were male,

with an average age of 20.4 +/- 4.5 years. The time between initial CBCT (T0) and post-expansion CBCT (T1) was 5 months in the ETG, and 5.3 months in the LTG, however the amount of time each subject was in expansion was 1.24 +/- 0.8 months in the ETG, and 0.93 +/- 0.17 months in the LTG. Since the interval between T1-T0 didn't exceed more than 6 months, growth as a variable was eliminated. Only 3 subjects in each group had the final 6 month CBCT's taken. All 6 month CBCT's were taken after 6 months except in one patient in the LTG, where it was taken 12 months after expansion was complete. (Table 1)

Once it was decided that expansion was complete, the expander was measured to see how much expansion had occurred in the expansion screw. In the ETG there was an average of 6.15 ± 0.5 mm of expansion in the expander, and 7.65 ± 0.27 mm in the LTG. The difference in the amount of expansion between the ETG and LTG showed statistical significance, with a p-value of 0.0292.

When looking at the amount of mid-palatal suture opening after expansion at anterior nasal spine (ANS), canine (C), first pre-molar (P1), second pre-molar (P2), first molar (M1) and posterior nasal spine (PNS), there was greater expansion at ANS and less expansion at PNS for both groups, however there was more mid-palatal suture opening in the ETG than the LTG. The difference between the increase in mid-palatal suture opening between the ETG and LTG was statistically significant at all regions except the first molar region. (Table 2) When the ratio of mid-palatal suture opening at M1 and expansion width in the appliance was calculated at T1, the M1/EW ratio in the ETG was 0.69 or 69% and 0.34 or 34% in the LTG.

When looking at intraorbital width (IOW) and zygomatic width (ZW) from T1-T0 and T2-T1, there was a small increase for both in the ETG and LTG. The intraorbital width increased 0.78 ± 0.19 mm in the ETG, and 0.35 ± 0.14 mm in the LTG from T1-T0, but there was no change in the LTG, and only a 0.12 ± 0.06 mm increase in the ETG from T2-T1. The zygomatic width increased 0.46 ± 0.1 mm in the ETG, and 0.35 ± 0.19 mm in the LTG from T1-T0. From T2-T1, there was an increase in the ETG of 0.28 ± 0.10

mm, and 0.01 ± 0.26 mm in the LTG. No statistical significance was found in the difference between these measures and between these time points. (Table 3)

The nasal width (NW), maxillary width (MW) and nasal floor width (NFW) all increased after expansion from T1-T0, in both the early and late treatment group. From T2-T1, the NW and MW increased slightly, however there was a decrease in the NFW in the ETG. In the LTG, there was a slight decrease in NW, MW, and NFW from T2-T1. There was a statistically significant difference between the ETG and LTG in NW from T1-T0, and in maxillary sinus width from T2-T0. (Table 4)

Basal Bone width (BBW) increased 4.11 ± 0.25 mm in the ETG, and 2.4 ± 0.71 mm in the LTG after expansion, and showed statistical significance with a p-value of 0.0520. From T2-T1, the BBW decreased 0.6 ± 0.25 mm in the ETG, and increased 0.23 ± 0.7 mm in the LTG. There was statistical significance with a p-value of 0.0330 for BBW between the ETG and LTG. (Table 5)

Alveolar Bone width (ABW) increased 4.79 ± 0.61 mm in the ETG, and 2.91 ± 1.02 mm in the LTG from T1-T0. From T2-T1, there was 0.52 ± 0.5 mm increase in ABW in the ETG, and 0.73 ± 0.29 mm increase in the LTG. Interdental width (IDW) increased 6.79 ± 0.17 mm in the ETG, and 7.70 ± 1.38 mm in the LTG after expansion, however there was no statistical significance between groups. In both the ETG and LTG the interdental width decreased from T2-T1. (Table 6)

Bone bending (BBZ) and dental tipping (TDTZ) were measured from the frontozygomatic suture line, to see if these measures had an affect on the increase in arch width. Bone bending occurs as part of palatal expansion due to the resistance from the zygomatic buttress, however dental tipping is an unwanted side effect of palatal expansion. In the ETG there was $0.20^\circ \pm 4.14^\circ$ of bone bending from T1-T0, while in the LTG there was $0.16^\circ \pm 2.25^\circ$ of bone uprighting, with no statistical difference between treatment groups. From T2-T1, there was $2.07^\circ \pm 1.83^\circ$ of bony uprighting in the ETG, and $2.73^\circ \pm 2.15^\circ$ of bone bending in the LTG, with no statistical significance between the two groups. Dental tipping was measured in the ETG

and LTG after expansion. In the ETG, from T1-T0 there was molar uprighting of $1.18^\circ \pm 1.83^\circ$, and in the LTG, molar tipping of $6.76^\circ \pm 2.12^\circ$, showing statistical significance with a p-value of 0.0220. From T2-T1 both groups showed molar uprighting, with $1.12^\circ \pm 4.04^\circ$ in the ETG, and $2.44^\circ \pm 2.31^\circ$ in the LTG. (Table 7)

Expansion can also result in absolute or relative extrusion of the upper molars. If bone bending or dental tipping occurs, the distance from the cusp tips to the reference line can increase or decrease. In the ETG, the buccal cusp extruded 0.12 ± 0.33 mm after expansion. In the LTG, there was 1.36 ± 1.57 mm of intrusion, which could be due to the dental tipping causing the distance between the FZ reference line and the DB cusp tip to decrease. From T2-T1, 0.44 ± 0.35 mm of distal buccal cusp extrusion occurred in the ETG, and 0.75 ± 1.03 mm of extrusion in the LTG.

Measuring the distance to the palatal cusp, there was 0.45 ± 0.29 mm of extrusion in the ETG after expansion, and 0.27 ± 0.26 mm of extrusion from T2-T1, with a total extrusion of 0.75 ± 0.48 mm. In the LTG there was 0.8 ± 0.27 mm of palatal cusp extrusion after expansion, and 0.29 ± 0.88 mm intrusion from T2-T1, with a total amount of extrusion from T2-T0 of 0.41 ± 1.19 mm. However, there was no statistical significance in buccal and palatal cusp extrusion between treatment groups. (Table 8)

The maxillary central incisor angulation was measured to see if there was a change in angulation as a result of midpalatal suture opening. In the ETG, after expansion, the upper central incisors uprighted and diverged 4.54° , and between T2-T1, they relapsed and converged 2.13° . Therefore, there was a total uprighting of 1.76° from T2-T0. In the LTG, the upper central incisors uprighted 2.38° between T1-T0, and between T2-T1, converged 0.81° . There was a total uprighting of 1.17° in the LTG and 0.81° in the ETG from T2-T0, which is similar for both groups. (Table 9)

Buccal bone width at 11mm and 14mm from the distal buccal cusp, and alveolar bone height were measured after expansion, and 6 months following expansion. In both the ETG and LTG there was a decrease in alveolar bone width at the 11mm reference point after expansion. In the ETG, there was 0.16 ± 0.09 mm of bone loss from T1-T0, and 0.60 ± 0.23 mm in the LTG. From T2-T1, bone loss continued with a decrease of 0.28 ± 0.17 mm in the ETG, however in the LTG, there was bone deposition of 0.10 ± 0.14 mm. There was no statistical significance between the two treatment groups for BBW at 11mm. The results were similar for BBW at 14mm, with the ETG and LTG both showing a small amount of bone loss after expansion. From T2-T1, the ETG continued to have bone loss while there was deposition of bone in the LTG. Alveolar bone height increased in both the ETG and LTG after expansion, but then decreased from T2-T1 returning to near its original height. (Table 10)

Initial palatal volume at T0 showed statistical significance between the ETG and LTG with a p-value of 0.0321. Palatal volume from T1-T0 increased 3458.6 ± 2222.0 mm³ in the ETG, and decreased 1928.0 ± 2791.0 mm³ in the LTG. Between T2-T1, the palatal volume decreased 809.9 ± 361.5 mm³ in the ETG, and decreased 626.4 ± 3486.3 mm³ in the LTG. The total volume change from T0 to T2, showed an overall increase of 1408.3 ± 3168.4 mm³ in the ETG, and a decrease of 2126.0 ± 3460.9 mm³ in the LTG. There was no significance between groups for palatal volume measures from T1-T0, T2-T1, and T2-T0. (Table 11)

The correlation between mid-palatal suture opening at M1 and expansion screw width of the appliance was tested after expansion at T1. In the ETG, as the width in the expander increased, the amount of suture opening at M1 stayed the same, with the average amount of expansion at M1 being 4mm. In the LTG, as expansion screw width increased there was an increase in mid-palatal suture opening at M1. Pearson correlation showed no statistical significance between these variable at T1. (See Fig 12) Using Pearson correlation coefficient, there was a weak negative correlation between patient age and M1/EW

ratio, however there was no statistical significance. (See Fig 13) When looking at MI/EW and CVMS, there was a strong negative correlation with statistical significance (Pears. corr. = -0.78, $p=0.0165$). (See Fig 14) The ratio of MI/EW decreases as the patient reaches the end of their facial and skeletal growth.

When looking at the correlation between bone bending and mid-palatal suture opening at MI after expansion, as mid-palatal suture width increased at MI, there was more bone bending in the LTG, while in the ETG there was more bone uprighting, however there was no statistical significance. (See Fig 15) The correlation between true dental tipping and mid-palatal suture opening at MI showed that, as mid-palatal suture width increased at MI there was a decrease in dental tipping with teeth uprighting in the LTG. In the ETG, as MI increased, dental tipping increased after expansion. There is however no statistical significance when looking at the relationship of bone bending and suture opening between groups. (See Fig 16)

Since data was collected on a small sample size for both the ETG and LTG, this pilot study was conducted to determine the sample size needed for future statistical significance. To confirm the observed mean differences or correlations with 80% power, and $p<0.05$ as level of significance, a sample size of 29 is needed for most measures, however the correlations require a larger sample size of up to 58, in particular the correlation of dental tipping and mid-palatal suture opening at MI. Because of the small difference in means between certain skeletal measures, such as bone bending, a very large sample size would be needed, however even with a smaller sample size we could still show clinically important mean differences or correlations.

DISCUSSION

To our knowledge, this pilot study is the first attempt to assess the role of skeletal maturity in an early and late treatment group with a bone-anchored appliance, immediately after expansion and then 6 months following expansion, using CBCT analysis.

Of the ten subjects that were part of this pilot study, all of the subjects in the ETG and LTG had fixed standard edgewise appliances placed once expansion was complete, using an 022 slot system, except for two subject in the LTG that had braces placed before expansion was complete. One of these subjects only had brackets placed on their upper central incisors. Engagement of a rectangular arch wire can have an effect on the dental tipping measurements, however in these 2 subjects only a round wire was used from T1-T0, ruling out any effect on dental tipping measurements. Between T2-T1, the remaining 8 patients had standard edgewise appliances placed on the U and L dentition. In the 6 patients who had reached and completed their 6 month post expansion CBCT, the maximum wire size that was used to level and align was a 16x22SS or 16x22NiTi wire. Only 2 of the subjects in the ETG had a 16x22SS or 16x22NiTi placed from T2-T1. The use of a 16x22 rectangular wire in a 022 slot would have 21.9° of play, and therefore this wire wouldn't have much of an effect on the tipping measurements of the upper maxillary first molars, but we would still consider that a possible treatment effect could have resulted from the use of braces during this time period.⁶

In the LTG, 2 subjects had initial failure of TADs, which required placement of new TADs. Three of the subjects in the LTG also required placement of two MARPE appliances. The initial arch width was so small that the expansion screw exceeded its limits before the transverse discrepancy could be corrected, and therefore a new appliance was needed to continue correction of the transverse discrepancy. In between the first and second MARPE, an essix retainer covering the palatal mucosa was used to hold the

transverse expansion gained, and a new MARPE was placed within 2 weeks of removing the first MARPE. Studies have shown that considerable skeletal relapse at the mid-palatal suture occurs after RPE and teeth are held in the expanded position with the conventional tooth-borne expander.⁶ Therefore, once the first MARPE was removed we would expect a relapse in the mid-palatal suture, and so in these subjects, the amount of expansion achieved was measured in the final MARPE expander.

Using a novel MARPE, we see a mix of results when looking at the skeletal outcomes from T1-T0, T2-T1, and T2-T0. There was a small increase in the intraorbital and zygomatic width after expansion in both the ETG and LTG, which confirms with previous studies that show that palatal expansion has an effect on areas that are farther away from the mid-palatal suture region.³ An increase occurred in both the ETG and LTG, showing that even as a patient passes skeletal maturity, treatment effects can occur at regional sites. However, there are mixed results with conventional RPE, with some studies showing no effect at regional sites in a later treatment group, while other studies showing an effect.³ With the use of a bone-anchored appliance, the force is located more superior which therefore could contribute to this effect we have seen within and between groups.

From T1-T0, NW, MW, NFW, BBW, ABW and IDW all increased, with a greater increase in the more inferior structures, confirming the wedge shape opening in the superior inferior direction, seen in both conventional RPE and bone-anchored RPE studies.^{1 7 13 14 15 17 19} There was a statistically significant difference in NW and BBW between the ETG and LTG ,with the ETG showing a greater increase in both the NW and BBW, which is consistent with previous studies using conventional RPE in an early and late treatment group.^{3 14} This could be due to the resistance that can occur with expansion in a more skeletally mature subject.

Between T2-T1 there was a decrease in NW, MW, NFW and IDW in the LTG, whereas in the ETG there was only a decrease in NFW, BBW, and IDW. The decrease in these measurements after 6 months

of retention most likely is due to a slight relapse of the skeletal and dental structures, which is commonly seen with studies using conventional RPE.³⁵ Even though a force directed close to the mid-palatal suture is achieved with MARPE, resistance from adjacent skeletal structure can affect skeletal opening, and could also possibly affect the relapse potential even when the MARPE is retained during the 6 month retention period.

Once expansion was complete, opening of the mid-palatal suture occurred in a V shape, with more opening in the anterior region at ANS, and less in the PNS region, and more opening inferiorly than superiorly in both the ETG and LTG. This is consistent with previous studies on tooth-borne and bone-borne expansion appliances.^{1 7 13 14 15 17 19} The difference in the amount of expansion width of the appliance between groups showed statistical significance, with more activation of the expansion appliance in the LTG compared to the ETG, however the amount of suture opening was greater in the ETG than the LTG. The difference in the mid-palatal suture opening between the ETG and LTG was statistically significant at all regions except the first molar region. Previous studies have shown that screw expansion and mid-palatal suture opening are not a 1:1 relationship.³⁶ This is not unusual to see since it takes several turns in the expansion device before suture opening occurs, and even more so in an older patient, due to the force needed to open the interdigitated mid-palatal suture and overcome the resistance from surrounding skeletal structures. This may also be a reason why two appliances were needed in three of the subjects in the LTG.

Since the expansion protocol was based on the individual patients treatment needs, the ratio of mid-palatal suture opening at MI to screw expansion width was calculated. When looking at the ratio of mid-palatal suture opening at MI and expansion width in the appliance after expansion, the mid-palatal suture opening is 69% of the total screw expansion in the ETG, and 34% in the LTG.

When comparing the amount of bone bending between an ETG and LTG, there was no statistical difference seen from T1-T0, T2-T1, and from T2-T0. During expansion, there was an overall increase in bone bending in the ETG, while there was bone uprighting in the LTG, however there was high variability of results within each group.

In the ETG, from T1-T0, two patients had 5-10° of bone uprighting, and three patients had 1-4° of bone bending. In the LTG, 2 patients had 3-8° of bone uprighting, and three patients had 1-4° of bone bending. After 6 months of retention, from T2-T1, we see bony uprighting of 2° in the ETG and bone bending of 2.7° in the LTG. When we look within each group, from T2-T1, 1 patient had 2° of bone uprighting, and 2 patients had no change in the ETG. In the LTG, from T2-T1, 1 patient had no change, and in two subjects there was 1- 8° of bone bending. In one of these two subjects the initial bone bending returned to its original value after 6 months of retention. Despite there being no statistical significance from T2-T1, we see an unexpected result between groups, most likely due to the small sample size from T2-T1. From T1-T0 there was a combination of both bone bending and bone uprighting in both groups, and from T2-T1, there was either no change, or there was bone uprighting and bone bending that occurred in both groups with no statistical difference. Current research has looked at bone bending with bone-anchored appliances and surgically assisted expansion but because a surgical procedure was involved we cannot compare these results to our study. A previous study using conventional expansion, measured bone bending from an angle formed by both sides of the palatal shelves, and reported 4.75 degrees of bone bending following expansion in a younger group.¹⁴ Another study looking at conventional RPE in a younger group showed 5.6 degrees of bone bending when measuring the angle to the palatal floor.³⁷ Even though conventional appliances were used in both these studies, bone bending was still evident in an early treatment group.

Dental tipping is independent of bone bending, so when calculating dental tipping we subtracted the amount of bone bending from dental tipping to get the true amount of dental tipping. This has also been used in other studies when measuring dental tipping with expansion.³⁸ When looking at dental tipping in our study, the results show a statistically significant difference in the amount of dental tipping between groups from T1-T0 and from T2-T0. In the ETG, there was 1.18° of dental uprighting while in the LTG there was 6.76° of dental tipping after expansion. The greater amount of dental tipping in the LTG could be due to the resistance to expansion that can occur with age. From T2-T1, we see both dental uprighting in both the ETG and LTG with no statistical significance. However, from T2-T0 there was an overall 4.3° of uprighting in the ETG, and 2° of dental tipping in the LTG. Therefore, we see more dental tipping in the LTG than in the ETG after expansion, with even more uprighting following 6 months of retention in the ETG, and also uprighting in the LTG.

When we look more carefully within each group, 3 subjects had dental tipping of 1-3°, while 2 subjects had dental uprighting, ranging from 1-6° in the ETG after expansion. From T1-T2, 2 subjects had dental tipping of 1-3° and 1 subject had 1° of dental uprighting which could be due to the bonding of brackets on all subjects after expansion was complete. In the LTG, 4 subjects had 6-13° of dental tipping, and 1 patient had no tipping from T1-T0. From T2-T1, one patient had 1-2° of dental tipping while 2 patients had 3-6° of dental uprighting. Therefore, even though results show a statistical significance in dental tipping between groups from T1-T0, and from T2-T0 there are a mix of results within each group. Dental uprighting after expansion and after retention are not commonly seen in conventional expansion, however a study has shown both dental tipping and dental uprighting in a younger group after conventional expansion.³⁷ Dental uprighting isn't commonly seen because, with conventional expansion, the teeth are held into position by the bands and therefore they are not free to upright during or after expansion. A study comparing bone-anchored to tooth-anchored appliances in a young age group reported dental tipping after expansion. They found 8 degrees of dental tipping in the bone-anchored group, and 9 degrees in the

tooth anchored group, with no statistical significance between groups. They also found uprighting of teeth after 6 months of retention, and again after 12 months of retention, with 1-2 degrees of uprighting at both time periods and within both groups.¹⁹ This relapse in dental tipping seen during the retention phase allowed for a reduction in the absolute dental tipping that occurred after expansion treatment, and should be viewed as a positive outcome during the retention phase.^{19 38}

When teeth are tipped there can be an affect on the buccal alveolar bone and alveolar bone height, with resorption of alveolar bone, resulting in recession and attachment loss, and possible dehiscence.²⁰ At the start of treatment one of the subjects in the LTG had bilateral dehiscence on the first maxillary molar distal buccal root and this remained at T1 and T2.

The results show that buccal bone width decreased at the 11mm and 14mm region after expansion, from T1-T0. This decrease in BBW could be caused by a small amount of force placed on the teeth from the extension arms of the appliance and the resulting dental movement. This force can push the tooth towards the buccal alveolar bone resulting in a decrease in bone width. However, there was no significant difference in BBW between the ETG and LTG. From T2-T1, the ETG showed a decrease in BBW at both 11 and 14mm, whereas the LTG showed an increased in bone width at 11 and 14mm, with statistical significance between groups at the 14mm region. This continuing decrease in bone width in the ETG could be a result of the orthodontic appliances placed and possible effect on the root position of the upper first maxillary molars. In the ETG it was previously noted that there was more dental uprighting, and with tooth uprighting the distance between the root and the buccal alveolar bone can decrease, which could have an affect in the ETG. From T2-T1, the LTG showed an increase in BBW at 11 and 14mm, with a significant difference between groups at 14mm. In the LTG we previously mentioned that after expansion there was significant dental tipping. This dental tipping could result in bony changes at the buccal alveolar region resulting in bone remodeling once the expansion force dissipated. This bony remodeling has been

seen in biopsies taken from patients following expansion.³⁹ The significant difference seen between groups at 14mm from T2-T1, could be affected by the small number of subjects who completed CBCTs at T2. Studies have reported recession occurring on only 2% of buccal alveolar bone sites which was limited to only .25 to 1mm of bone loss, however this was seen in conventional expansion and in an early treatment group.⁴ Buccal cortical bone width was measured in an axial slice using CBCT after conventional expansion in a young treatment group. After expansion they found a decrease in bone thickness in both the mesial and distal roots of the first molar, and there was statistical significance for the middle, apical and furcation levels.²⁰ Our results are similar to those seen with conventional expansion, with bone decreasing after expansion and then increasing during retention in the first molar region.⁴⁰

Alveolar bone height increased in both the ETG and LTG. We would expect to see a decrease in ABH but instead saw an increase. If teeth are being tipped, the distance between the height of alveolar crestal bone and the reference line will decrease, resulting in a false positive. Therefore, one of the limitations of this study is with the measurement of ABH. From T2-T1, we see in both the ETG and LTG that the numbers return to their original value, again confirming the previous notion that dental tipping has affected alveolar bone height, which then returns to normal 6 months after expansion once teeth have uprighted. These findings are similar to those seen in conventional RPE where ABH was reduced after expansion and then became non significant after a 6 month retention period. In this study ABH was measured from the cusp tip to the height of buccal alveolar bone crest.²⁰

Upper incisor angulation showed 4.54° of uprighting in the ETG and 2.38° of uprighting in the LTG after expansion. Following expansion, from T2-T1, the upper incisors tipped mesially, however there was still a total of 1.76° of uprighting in the ETG, and 1.17° of uprighting in the LTG. This is consistent with previous studies that have shown that during expansion the opening of the midpalatal suture creates a

diastema with divergence of the upper central incisors, allowing for uprighting of the anterior teeth. During the retention phase the central incisor crowns move mesially due to the recoil from the stretched transeptal fibers.¹⁹

Tooth anchored appliances have shown to cause dental tipping resulting in palatal cusp extrusion. Extrusion of the palatal cusp can result in bite opening and thereby effect the vertical dimension of the patient. Previous studies with conventional and bone anchored RPE have shown that dental tipping caused by expansion resulted in significant extrusion of the molar compared to controls.¹⁹ Despite 2mm of molar extrusion, they found no significant increase in the vertical position of the mandible, and they concluded that extrusion may be do to the tipping of the tooth rather than true dental extrusion.¹⁹ Using the zygomaticofrontal sutures and creating a reference line, we can measure the amount of extrusion of the P and DB cusp after expansion from T1-T0, and from T2-T1. Our results show no significant difference between the groups, however in the ETG there was a small amount of extrusion from T1-T0 in both the buccal and palatal cusp. In the LTG there was a reduction in the B cusp measurement, while the palatal cusp extruded more than in the ETG. With bone bending and dental tipping we would expect the distance between the DB cusp tip and reference line to decrease, with a subsequent increase in the P cusp tip. With tooth uprighting and bone uprighting however, the buccal cusp would extrude and the palatal cusp would intrude or stay in the same position. Even though our results show no significant difference in bone bending and dental tipping between groups, within the groups there is both tooth uprighting and tipping, and bone uprighting and bending that occurs, which therefore has an effect on these measurements. From T2-T1 there was again a slight increase in both the DB and P cusp extrusion in the ETG, and both the DB cusp and P cusp decreased in the LTG. Since only one patient had a round wire placed with the standard edgewise appliance we can rule out the effect of orthodontics on palatal extrusion form T1-T0. From T2-T1 both the buccal and palatal cusp extruded in the ETG and LTG, however in the ETG extrusion

did not return the teeth back to their original position. This extrusion could be due to the uprighting and relapse of bone bending and dental tipping during retention or could be due to the use of standard edgewise appliance from T2-T1, which could cause extrusion during leveling and aligning. From these findings we can conclude that MARPE produces bone uprighting and tooth uprighting in an ETG resulting in molar extrusion, while bone bending and dental tipping result in a relative intrusion of the buccal cusps.

A systematic review looking at effects of conventional RPE found that mid-palatal suture opening in the posterior region ranged from 22-53%, when the age of the patient ranged from 8-14 years.⁴¹ Using conventional Haas RPE, and comparing between a patient group >18 years and another group <18 years, there was 18% skeletal correction in patients older than 18, and 56% skeletal correction in patients less than 18 years of age, however in this study only dental casts were measured to determine this outcome, and growth was not ruled out in this study.⁴

Maxillary expansion using a conventional Hyrax in an early treatment group with a mean age of 14 years reported 38% of skeletal expansion, 13% bone bending, and 49% dental tipping at M1. Since there are a mix of treatment results in bone bending and dental tipping in both the ETG and LTG in our study, we decided to use suture opening at M1, ABW and IDW to calculate the amount of skeletal expansion, bone bending and dental tipping after expansion, which has been how other studies have measured this relationship.

In the ETG there was 61% skeletal expansion, 10% bone bending and 29% dental tipping, compared to 34% skeletal expansion, 4% bone bending, and 62% dental tipping in the LTG. We can see a large difference between outcomes in the ETG and LTG, with more dental tipping in the LTG to correct the transverse discrepancy. Compared to the use of a conventional expander, which showed 18% skeletal correction in patients older than 18, MARPE was almost twice as effective at achieving skeletal correction in an older treatment group. When older patients underwent SARPE with conventional expansion,

Zemann et al. found 15.3% apical molar expansion, while Goldenberg et al. found 28.28% palatal width expansion.^{8 42} Therefore, the use of a novel MARPE in a LTG resulted in a greater amount of skeletal expansion compared to SARPE in an older patient group.

Due to the lack of a control group for our study the findings for younger patients undergoing conventional rapid palatal expansion and older patients undergoing surgically assisted expansion have been listed and summarized in a table format below.^{43 37 44 45 46 47 14 48 49 50 8 42}

Table I: Rapid Palatal Expansion Literature Summary

RPE					
Author	Timepoint	Sample Size	Amount of Expansion	Age	Results
Weissheimer et al. (2011)	iCAT T1=initial T2= post expansion	N=33 Haas n=18 Hyrax n= 15	8mm	10.7 years	Hyrax IDW= increased 7.9mm BBW= increased 3.10mm Suture width= increased 3.14mm (39.2%) Dental Tipping = 6.19-6.8 ° Haas IDW= increased 7.7mm BBW= increased 2.19mm Suture width=increased 2.62mm(32.7%) Dental Tipping= 6.14-8.25°
Kartalian et al. (2010)	Newtom 3G	N=	Overcorrection with P cusp of U6 occluding with B cusp of L6's	12.8 years	Bond bending= 5.6° IDW=5.35 mm Tooth uprighting= 0.81°
Ballanti et al. (2010)	CT T0=initial T1= post expansion T2=6 months retention	N=17 Butterfly expander	7mm	11.2 years	IDW= increased 2.54mm Posterior Nasal width= increased 1.01mm Posterior suture width= increased 0.84-0.92mm
Christie et al. (2010)	iCAT T1= initial T2=post expansion	N=24 Bonded Haas	Expanded until transverse corrected	9.9 years	BBW= increased 3.33mm(40.65%) Midpalatal suture width=increased 4.33mm(52.82%) Dental Tipping= increased 5.6-6.22°
Ballanti et al. (2009)	CT T0=initial T1=post expansions T2=6 months retention	N=17 Butterfly expander	7mm	11.2 years	T1 IDW= 2.7mm Intermolar Apex width=3.6mm BBW= decreased 0.2-0.4mm T2 0.7mm of bone apposition palatally on U6's
Lione et al. (2008)	CT	N=17	7mm	11.2 years	Posterior suture width=1.15mm
Garrett et al. (2008)	CBCT Newtom 3G T0=initial T1=post expansion	N=30 Hyrax	-	13.8years	Skeletal Expansion at M1=38% Alveolar bone bending at M1=13% Dental Tipping at M1=49%

Table 2: Surgically Assisted Rapid Palatal Expansion Literature Summary

SARPE					
Author	Analysis & Timepoint	Sample size	Amount of expansion	Age	Results
Prado et al. (2014)	3D Dental Casts T0=initial T1=4months after expansion T2=10 months after expansion	N=30 Retention=15 Non-retention=15	Until crossbite corrected	Retention-25.3 years Non-retention=26.3 years	T1 IDW=increased 8.61mm Palatal height= decreased 0.79mm T2 IDW=relapsed 1.04mm (2.35%) Palatal height= decreased 0.18mm
Gurgel et al. (2013)	PA Ceph T1=initial T2=after expansion T3=120 days after expansion	N=21 Hyrax expander	-	25.4 years	T2 Nasal cavity width=decreased 0.5mm Jugular process width=increased 4.25mm Intermolar width=increased 4.40mm Dental tipping=increased 2.07-2.88° T3 Intermolar width=decreased 1.82mm Jugular process width=decreased 0.2mm Molars uprighted=0.86°
Gauthier et al. (2011)	iCAT T0=initial T1=6 month after expansion	N=14 Bonded Hyrax	9.82mm	23 years	Buccal alveolar bone thickness=decreased on mesial 2.4-3.3mm Palatal alveolar bone thickness=increased 0.2-1.4mm Buccal Alveolar crest level=decreased on mesial of U6's 2.4-3.3mm, on canines 2.5-2.8mm
Zemann et al. (2009)	CT scan T1=initial T2=post expansion	N=18 Haas	overexpanded	26 years	IDW= increased 13.3% Dental tipping=1-8° Apical molar expansion=15.3%
Goldenberg et al. (2008)	CT scan T1=initial T2=6 months after expansion	N=15 Hyrax	2.5mm overcorrection	24.47 years	NFW=11.52% Palatal width=28.28% Inferior palatal alveolar bone width=19.1% Appliance opening>suture opening Suture opening/appliance opening was greatest anteriorly and inferiorly at 50%

Palatal volume was calculated to see if there was an increase in volume after expansion, which is to be expected, and if that increase in volume maintained itself 6 months after expansion was complete.

Despite there being a statistically significant difference between the initial palatal volumes in the ETG and LTG, there was no statistical significance from T1-T0, and from T2-T0 between groups.

This initial difference in palatal volume could be due to the grouping of the patients into an ETG and LTG, with those in the ETG still having potential for growth, while the majority of growth is complete in the LTG. This difference could also be due to the individual patients themselves within the ETG and LTG. The smaller initial palatal volume for the subjects in the ETG could be due to the narrow maxilla's and

smaller transverse dimensions within that group, thereby resulting in a smaller measurement and a statistical difference between groups.

There are many skeletal and dental factors that can affect the palatal volume and the change in volume after expansion and subsequently following retention. Previous studies have shown that after expansion the upper incisor moved posterior by 1 mm in most cases with some patients exhibiting proclination.¹⁵ The movement of the upper anterior teeth in a posterior direction could result in a reduction in the palatal volume after expansion. Palatal volume increases not only from the opening of the mid-palatal suture, but also from dental tipping and bone bending in the posterior regions.

From T1-T0, there was an increase in PV in the ETG, but an overall decrease in the LTG, which was not expected. In two of the subjects in the LTG, PV decreased after expansion while in the other three subjects there was an increase in palatal volume. In one of the subjects there was proclination of the upper anteriors after expansion, which would therefore change the inferior border of the region of interest. If the central incisor proclines, the line running from the CEJ of the central incisor will move more superior, resulting in a decrease in palatal volume for that subject. In the second subject, there was more dental tipping in the molar region compared to suture opening. The dental tipping could have resulted in changes in the palatal alveolar surface of the posterior region, with the palatal alveolar bone moving more medially, resulting in a reduction in palatal volume. In the ETG there was an overall increase in palatal volume after expansion, however there was one subject who had a decrease in palatal volume in this treatment group. It was noted that the upper canines had been blocked out at initial presentation, and with expansion, space was created which allowed the canines to come into the arch resulting in a decrease in palatal volume. A previous study looked at the change in palatal volume between a control group and a young growing group who underwent RPE. Palatal volume was measured using CBCT and the same reference lines as our study. They found a 10.8% change in palatal volume in the control group, and 21.7% change in the RPE group, with an 11% increase in palatal volume for the RPE group. There was statistical significance between

groups for the percentage volume change, but no significance for the absolute palatal volume change between groups.⁵¹ When looking at the percentage change in volume in the ETG, if we eliminate the subject who showed a decrease in volume, there is a 29.7% increase in PV between T1-T0 in the ETG. In the LTG, two of the subjects had a decrease in PV which was previously discussed so if we eliminate those two subjects, the remaining three subjects showed an increase in PV with an overall increase of 9.8% from T1-T0.

From T2-T1, there was an overall decrease in PV in both the ETG and LTG, however the decrease in palatal volume was less than the increase after expansion. All three subjects in the ETG had a decrease in PV with an average decrease of 4.6% following expansion. In the LTG, two subjects had an increase in PV from T2-T1, while only one subject had a decrease. In the two subjects who showed an increase in PV after retention, orthodontic movements such as molar inclination, arch alignment, and relieving crowding by proclination of teeth could have influenced this measure, and resulted in an increase between this time point. In the one subject who showed a decrease in PV from T2-T1, this subject had extractions of the upper second premolars following expansion, which would therefore effect palatal volume.

There have been no studies on the change in palatal volume after 6 months of retention, however two dimensional studies looking at stability after expansion have shown that relapse of the skeletal structures does occur with 70% of expansion being maintained for both a tooth borne and bone borne appliance at 12 months retention in a young treatment group. There also showed no significant difference in relapse between appliance types.¹⁹

Even though there was no statistical significance in the correlation of MI and EW between groups, both groups showed an increase in mid-palatal suture opening at MI as the expansion screw width increased. The negative correlation seen in patient age and MI/EW ratio is consistent with previous studies, which show that as a patient ages suture opening at the mid-palatal suture decreases. This is

confirmed when looking at CVMS and MI/EW correlation, which had a statistically significant negative correlation. However, mid-palatal suture opening was achieved in both groups.

As mid-palatal suture width increased at MI, there was more bone bending in the LTG, while in the ETG there was more bone uprighting. Even though there was no statistical significance between groups there was a huge range in results after expansion in both groups, which was previously discussed and could have affected this correlation. The correlation between true dental tipping and mid-palatal suture opening at MI showed that, as mid-palatal suture width increased at MI there was a decrease in dental tipping with teeth uprighting in the LTG. Whereas in the ETG, as MI increased, dental tipping increased after expansion, however there was no statistical significance. Again for the both the ETG and LTG there was a range of results within each group with uprighting and dental tipping occurring in each group, therefore there was no pattern or trends seen between or within groups.

CONCLUSION

The introduction of a novel MARPE appliance, without attachment of the appliance to the teeth, to correct a transverse discrepancy in an early and late treatment group has resulted in successful results. We expected that the MARPE would produce similar treatment results in both an ETG and LTG, with greater skeletal outcomes such as suture opening and bone bending, and less dental tipping, which is commonly seen with conventional expansion in a late treatment group.

For both the ETG and LTG, opening of the mid-palatal suture occurred in a V shape, with more opening in the anterior region at ANS, and less in the PNS region, and more opening inferiorly than superiorly. Similar results were seen between groups for all the skeletal outcomes except at NW, BBW, TDTZ from T1-T0, Basal Bone Width and Buccal bone width at 14mm from T2-T1, and MW, and TDTZ from T2-T0, where these measured showed statistical significance between groups.

The ratio of mid-palatal suture opening at M1 and expansion width in the appliance at T1, was 69% in the ETG and 34% in the LTG, with the LTG needing more width in the expander to achieve a similar opening in the mid-palatal suture. Both bone bending and dental tipping were evident in both the ETG and LTG with a wide range of results, with some subjects experiencing bone uprighting and tooth uprighting. After expansion there was 6 degrees of dental tipping in the LTG, and 1 degree of dental uprighting in the ETG, with both groups showing uprighting in the retention phase. Buccal bone width at both 11 and 14 mm reference points decreased during expansion, and then increased during the retention phase in both the ETG and LTG. Majority of the subjects in both the ETG and LTG showed an increase in palatal volume following expansion with a slight decrease during retention from T2-T1, showing stability of palatal volume changes 6 months after expansion. When looking at the amount of skeletal correction versus bone bending and dental tipping achieved with a MARPE and between groups, in the ETG there was 61% skeletal expansion, 10% bone bending and 29% dental tipping, compared to 34% skeletal expansion, 4% bone bending, and 62% dental tipping in the LTG.

The use of a novel bone-anchored RPE has overcome the limitations of a traditional tooth-anchored appliance, allowing force to be directed adjacent to the mid-palatal suture, opening up the suture and achieving skeletal treatment results in a late treatment group. Despite this being a pilot study, the results have shown differences between the ETG and LTG and therefore we will accept the null hypothesis, that there is a difference between an early and late treatment group when using MARPE. However, increasing the sample size in both groups will determine if there is a true significant difference between groups.

FIGURES

Figure 12: Correlation of Mid-palatal Suture Opening at M1 and Expansion Screw Width

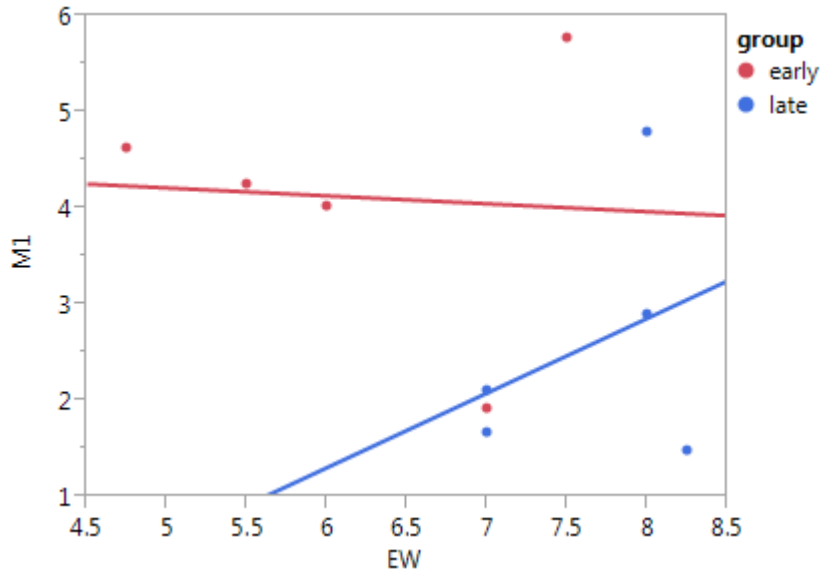


Figure 13: Correlation of M1/EW to Age

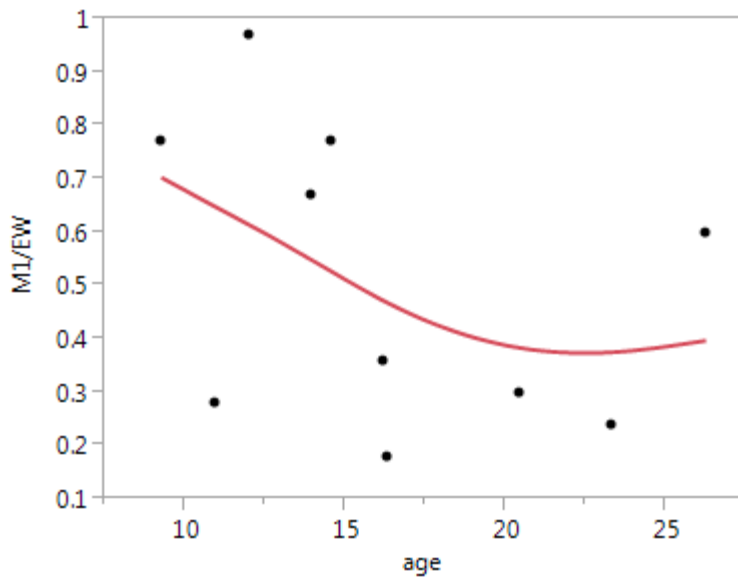


Figure 14: Correlation of MI/EW to CVMS

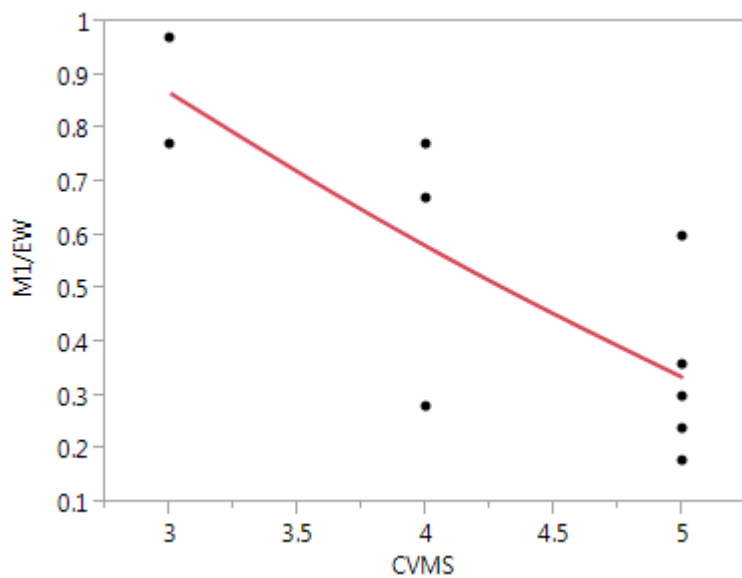


Figure 15: Correlation of Dental Tipping and Mid-palatal Suture Opening at M1

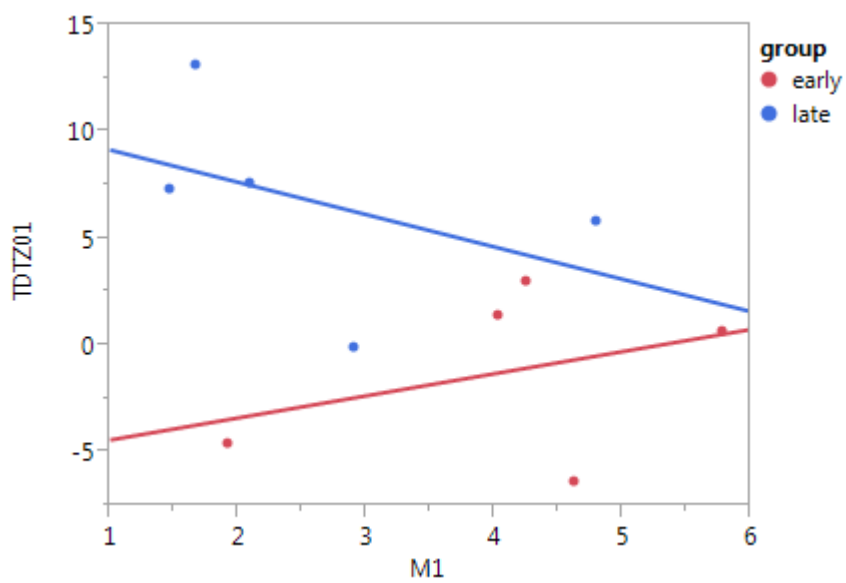
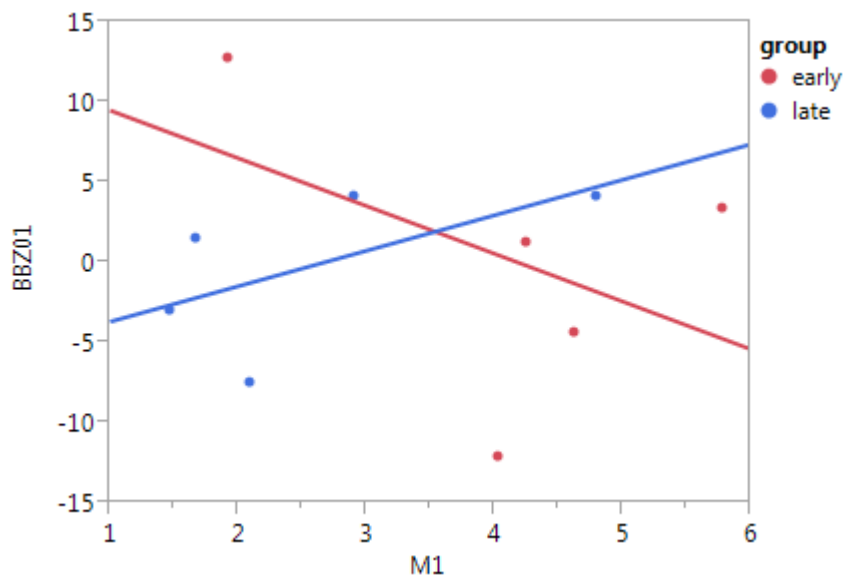


Figure 16: Correlation of Bone Bending and Mid-palatal Suture Opening at M1



TABLES

Table 3: Age, CVMS, Expansion Time and Time Between CBCT's

	ETG			LTG		
	n	Mean \pm s.d.	Range	n	Mean \pm s.d.	Range
Age (y)	5 (1 M, 4 F)	12.3 \pm 1.8	10.2 -14.4	5 (2M, 3 F)	20.4 \pm 4.5	16-26.3
CVMS	5	3.6 \pm 0.5	3-4	5	5 \pm 0	5
Expansion time (mths)	5	1.2 \pm 0.4	0.9 – 1.8	5	0.9 \pm 0.2	0.7-1.2
Time between T1-T0 (mths)	5	5 \pm 1.4	3-6	5	5.3 \pm 1.9	2.5-8
Time between T2-T1 (mths)	3	6	0	3	7.8 \pm 3.6	6-12

Table 4: Expansion Width and Mid-palatal Suture Opening Changes

	Early Treatment Group			Late Treatment Group			P-Value
	n	mean	s.d.	n	mean	s.d.	
EW	5	6.15	0.5	5	7.65	0.27	0.0292
ANS	5	4.69	0.53	5	2.84	0.48	0.0321
Canine	5	4.32	0.56	5	2.72	0.57	0.0818
PI	5	4.41	0.53	5	2.77	0.56	0.0675
P2	5	4.31	0.49	5	2.58	0.61	0.0581
MI	5	4.12	0.63	5	2.59	0.6	0.1167
PNS	5	3.8	0.66	5	2.09	0.55	0.0818

Table 5: Intraorbital Width and Zygomatic Width Changes

	Time	Early Treatment Group			Late Treatment Group			P-Value
		n	mean	s.d.	n	mean	s.d.	
IOW	T0	5	16.24	±0.62	5	15.95	±1.16	0.8279
	T1-T0	5	0.78	±0.19	5	0.35	±0.14	0.1088
	T2-T0	3	0.8	±0.26	3	0.35	±0.29	0.3134
	T2-T1	3	0.12	±0.06	3	0	±0.43	0.7860
ZW	T0	5	125.62	±4.88	5	124.47	±3.02	0.8456
	T1-T0	5	0.46	±0.1	5	0.35	±0.19	0.6088
	T2-T0	3	0.76	±0.16	3	0.33	±0.18	0.1424
	T2-T1	3	0.28	±0.1	3	0.01	±0.26	0.3778

Table 6: Nasal Width, Maxillary Sinus Width, and Nasal Floor Width Changes

	Time	Early Treatment Group			Late Treatment Group			P-Value
		n	mean	s.d.	n	mean	s.d.	
NW	T0	5	29.50	±0.59	5	33.04	±0.72	0.0052
	T1-T0	5	3.69	±0.51	5	1.64	±0.55	0.0259
	T2-T0	3	3.58	±0.06	3	2.12	±1.15	0.2756
	T2-T1	3	0.47	±0.66	3	-0.07	±0.37	0.5152
MW	T0	5	72.37	±4.99	5	73.56	±2.56	0.8372
	T1-T0	5	2.85	±0.27	5	1.89	±0.50	0.1302
	T2-T0	3	4.45	±0.86	3	1.57	±1.01	0.0963
	T2-T1	3	1.6	±1.21	3	-0.63	±0.44	0.1599
NFW	T0	5	26.73	±1.14	5	28.43	±1.68	0.4259
	T1-T0	5	3.54	±0.29	5	2.55	±0.57	0.1581
	T2-T0	3	2.83	±0.43	3	2.72	±1.24	0.9382
	T2-T1	3	-0.43	±0.2	3	-0.57	±0.67	0.8414

Table 7: Basal Bone Width, Alveolar Bone Width, and Interdental Width Changes

	Time	Early Treatment Group			Late Treatment Group			P-Value
		n	mean	s.d.	n	mean	s.d.	
BBW	T0	5	59.51	±2.26	5	60.35	2.13	0.7934
	T1-T0	5	4.11	±0.25	5	2.40	0.71	0.0520
	T2-T0	3	3.18	±0.14	3	3.25	1.10	0.9548
	T2-T1	3	-0.60	±0.25	3	0.23	0.07	0.0330
ABW	T0	5	58.36	±1.98	5	60.18	1.56	0.4893
	T1-T0	5	4.79	±0.61	5	2.91	1.02	0.1545
	T2-T0	3	4.88	±0.44	3	4.58	1.26	0.8380
	T2-T1	3	0.52	±0.50	3	0.73	0.29	0.7345
IDW	T0	5	52.76	±1.96	5	54.84	1.00	0.3729
	T1-T0	5	6.79	±0.17	5	7.70	1.38	0.5344
	T2-T0	3	6.10	±1.7	3	7.85	1.38	0.4683
	T2-T1	3	-0.53	±1.61	3	-0.84	1.14	0.8805

Table 8: Bone Bending and Dental Tipping Changes

	Time	Early Treatment Group			Late Treatment Group			P-Value
		n	mean	s.d.	n	mean	s.d.	
Bone Bending	T0	5	108.87	±2.86	5	107.17	±4.51	0.7584
	T1-T0	5	0.20	±4.14	5	-0.16	±2.25	0.9414
	T2-T0	3	-3.29	±5.64	3	2.98	±1.74	0.3483
	T2-T1	3	-2.07	±1.83	3	2.73	±2.15	0.1652
Dental Tipping	T0	5	15.44	±1.66	5	15.15	±2.52	0.9278
	T1-T0	5	-1.18	±1.83	5	6.76	±2.12	0.0220
	T2-T0	3	-4.31	±1.96	3	2.00	±1.77	0.0751
	T2-T1	3	-1.12	±4.04	3	-2.44	±2.31	0.7898

Table 9: Buccal and Palatal Cusp Extrusion

Extrusion	Time	Early Treatment Group			Late Treatment Group			P-Value
		n	mean	s.d.	n	mean	s.d.	
B cusp	T0	5	67.20	2.56	5	71.71	2.26	0.2240
	T1-T0	5	0.12	0.33	5	-1.36	1.57	0.3835
	T2-T0	3	0.55	0.63	3	-0.51	1.58	0.5680
	T2-T1	3	0.44	0.35	3	-0.75	1.03	0.3326
P cusp	T0	5	68.02	2.78	5	72.72	2.09	0.2141
	T1-T0	5	0.45	0.29	5	0.80	0.27	0.3899
	T2-T0	3	0.75	0.48	3	0.41	1.19	0.8040
	T2-T1	3	0.27	0.26	3	-0.29	0.88	0.5771

Table 10: Changes in Buccal Bone Width at 11mm and 14mm

Buccal Bone Loss	Time	Early Treatment Group			Late Treatment Group			P-Value
		n	mean	s.d.	n	mean	s.d.	
BBW 11	T0	5	2.50	0.36	5	1.88	0.27	0.2049
	T1-T0	5	-0.16	0.09	5	-0.60	0.23	0.1102
	T2-T0	3	-0.45	0.28	3	-0.33	0.34	0.8038
	T2-T1	3	-0.28	0.17	3	0.10	0.14	0.1578
BBW 14	T0	5	2.58	0.44	5	1.28	0.41	0.0633
	T1-T0	5	-0.08	0.15	5	-0.15	0.13	0.7310
	T2-T0	3	-0.74	0.28	3	-0.14	0.14	0.1274
	T2-T1	3	-0.70	0.05	3	0.11	0.34	0.0746

Table 11: Alveolar Bone Height Changes

Alveolar Bone Height	Time	Early Treatment Group			Late Treatment Group			P-Value
		n	mean	s.d.	n	mean	s.d.	
ABH	T0	5	8.22	0.15	5	8.66	0.35	0.2861
	T1-T0	5	-0.17	0.21	5	-0.28	0.17	0.6970
	T2-T0	3	-0.02	0.26	3	-0.01	0.15	0.9692
	T2-T1	3	0.21	0.11	3	0.20	0.22	0.9618

Table 12: Changes in Upper Incisor Angulation

Incisor Tipping	Time	Early Treatment Group			Late Treatment Group			P-Value
		n	mean	s.d.	n	mean	s.d.	
UIA	T0	5	94.94	±2.38	5	91.20	±1.77	0.2439
	T1-T0	5	-4.53	±0.97	5	-2.38	±1.10	0.1806
	T2-T0	3	-1.76	±0.77	3	-1.17	±1.35	0.7218
	T2-T1	3	2.13	±1.13	3	0.81	±1.66	0.5463

Table 13: Changes in Palatal Volume

Palatal Volume	Time	Early Treatment Group			Late Treatment Group			P-Value
		n	mean	s.d.	n	mean	s.d.	
PV	T0	5	13229.5	±2181.8	5	19981.6	±1866.6	0.0466
	T1-T0	5	3458.6	±2222.0	5	-1928.0	±2791.0	0.1695
	T2-T0	3	1408.3	±3168.4	3	-2126.0	±3460.9	0.4932
	T2-T1	3	-809.9	±361.5	3	-626.4	±3486.3	0.9608

REFERENCES

1. Haas AJ. Rapid Expansion Of the Maxillary Dental Arch And Nasal Cavity By Opening The Midpalatal Suture. *Angle Orthod.* 1961;31(2):73–90.
2. Suri L, Taneja P. Surgically assisted rapid palatal expansion: A literature review. *Am J Orthod Dentofac Orthop.* 2008;133:290–302. doi:10.1016/j.ajodo.2007.01.021.
3. Baccetti T, Franchi L, Cameron CG, McNamara J a. Treatment timing for rapid maxillary expansion. *Angle Orthod.* 2001;71(5):343–350.
4. Handelman CS, Wang L, BeGole E a, Haas a J. Nonsurgical rapid maxillary expansion in adults: report on 47 cases using the Haas expander. *Angle Orthod.* 2000;70(2):129–44. doi:10.1043/0003-3219(2000)070<0129:NRMEIA>2.0.CO;2.
5. Gautam P, Valiathan A, Adhikari R. Stress and displacement patterns in the craniofacial skeleton with rapid maxillary expansion: a finite element method study. *Am J Orthod Dentofacial Orthop.* 2007;132(1):5.e1–11. doi:10.1016/j.ajodo.2006.09.044.
6. Proffit, W., Fields, H.W., Sarver D. *Contemporary Orthodontics*. Fourth.; 2007:282–290.
7. Starnbach, H., Bayne, D., Cleall, J., Subtelny JD. Facioskeletal And Dental Changes Resulting From Rapid Maxillary Expansion. *Angle Orthod.* 1966;36(2):152–164.
8. Zemann W, Schanbacher M, Feichtinger M, Linecker A, Kärcher H. Dentoalveolar changes after surgically assisted maxillary expansion: a three-dimensional evaluation. *Oral Surgery, Oral Med Oral Pathol Oral Radiol Endodontology.* 2009;107:36–42. doi:10.1016/j.tripleo.2008.05.044.
9. Melsen B. Palatal growth studied on human autopsy material. *Am J Orthod.* 1975;68(1):42–54. doi:10.1016/0002-9416(75)90158-X.
10. Wehrbein H, Yildizhan F. The mid-palatal suture in young adults. A radiological-histological investigation. *Eur J Orthod.* 2001;23(2):105–14. Available at: <http://www.ncbi.nlm.nih.gov/pubmed/11398548>.
11. Adkins MD, Nanda RS, Currier GF. Arch perimeter changes on rapid palatal expansion. *Am J Orthod Dentofacial Orthop.* 1990;97(3):194–9. Available at: <http://www.ncbi.nlm.nih.gov/pubmed/2178393>.
12. Graber V. *Orthodontics Current Principles and Techniques*. Fifth.; 2011.

13. Ghoneima A, Abdel-Fattah E, Hartsfield J, El-Bedwehi A, Kamel A, Kula K. Effects of rapid maxillary expansion on the cranial and circummaxillary sutures. *Am J Orthod Dentofacial Orthop*. 2011;140(4):510–9. doi:10.1016/j.ajodo.2010.10.024.
14. Garrett BJ, Caruso JM, Rungcharassaeng K, Farrage JR, Kim JS, Taylor GD. Skeletal effects to the maxilla after rapid maxillary expansion assessed with cone-beam computed tomography. *Am J Orthod Dentofac Orthop*. 2008;134(1):8.e1–8.e11. doi:10.1016/j.ajodo.2007.11.024.
15. Wertz R a. Skeletal and dental changes accompanying rapid midpalatal suture opening. *Am J Orthod*. 1970;58(1):41–66.
16. Cross DL, McDonald JP. Effect of rapid maxillary expansion on skeletal, dental, and nasal structures: a postero-anterior cephalometric study. *Eur J Orthod*. 2000;22(5):519–28. Available at: <http://www.ncbi.nlm.nih.gov/pubmed/11105408>.
17. Braun S, Bottrel JA, Lee K, Lunazzi JJ. ORIGINAL ARTICLE The biomechanics of rapid maxillary sutural expansion. *Am J Orthod Dentofac Orthop*. 2000;118:257–261.
18. Provatidis C, Georgiopoulos B, Kotinas a, McDonald JP. On the FEM modeling of craniofacial changes during rapid maxillary expansion. *Med Eng Phys*. 2007;29(5):566–79. doi:10.1016/j.medengphy.2006.03.007.
19. Lagravère MO, Carey J, Heo G, Toogood RW, Major PW. Transverse, vertical, and anteroposterior changes from bone-anchored maxillary expansion vs traditional rapid maxillary expansion: a randomized clinical trial. *Am J Orthod Dentofacial Orthop*. 2010;137(3):304.e1–12; discussion 304–5. doi:10.1016/j.ajodo.2009.09.016.
20. Baysal A, Uysal T, Veli I, Ozer T, Karadede I, Hekimoglu S. Evaluation of alveolar bone loss following rapid maxillary expansion using cone-beam computed tomography. *Korean J Orthod*. 2013;43(2):83–95. Available at: <http://www.pubmedcentral.nih.gov/articlerender.fcgi?artid=3650217&tool=pmcentrez&rendertype=abstract>.
21. Harzer W, Reusser L, Hansen L, Richter R, Nagel T, Tausche E. Minimally invasive rapid palatal expansion with an implant-supported hyrax screw. *Biomed Tech (Berl)*. 2010;55(1):39–45. doi:10.1515/BMT.2010.002.
22. Tausche E, Hansen L, Hietschold V, Lagravère MO, Harzer W. Three-dimensional evaluation of surgically assisted implant bone-borne rapid maxillary expansion: a pilot study. *Am J Orthod Dentofacial Orthop*. 2007;131(4 Suppl):S92–9. doi:10.1016/j.ajodo.2006.07.021.
23. Hansen L, Tausche E, Hietschold V, Hotan T, Lagravère M, Harzer W. Skeletally-anchored rapid maxillary expansion using the Dresden Distractor. *J Orofac Orthop*. 2007;68(2):148–58. doi:10.1007/s00056-007-0643-z.

24. Harzer W, Reusser L, Hansen L, Richter R, Nagel T, Tausche E. *Minimally invasive rapid palatal expansion with an implant-supported hyrax screw.*; 2010:39–45. doi:10.1515/bmt.2010.002.
25. Vande Vannet B, Sabzevar MM, Wehrbein H, Asscherickx K. Osseointegration of miniscrews: a histomorphometric evaluation. *Eur J Orthod.* 2007;29:437–442. doi:10.1093/ejo/cjm078.
26. Lee KJ, Park YC, Park JY, Hwang WS. Miniscrew-assisted nonsurgical palatal expansion before orthognathic surgery for a patient with severe mandibular prognathism. *Am J Orthod Dentofac Orthop.* 2010;137:830–839. doi:10.1016/j.ajodo.2007.10.065.
27. Grauer D, Cevitanes LSH, Proffit WR. Working with DICOM craniofacial images. *Am J Orthod Dentofacial Orthop.* 2009;136(3):460–70. doi:10.1016/j.ajodo.2009.04.016.
28. Lagravère MO, Heo G, Major PW, Frcd C, Flores-mir C, Orth C. rapid maxillary expansion treatment. 2006;137(January).
29. Lagravère MO, Gordon JM, Guedes IH, et al. Reliability of traditional cephalometric landmarks as seen in three-dimensional analysis in maxillary expansion treatments. *Angle Orthod.* 2009;79(6):1047–1056. doi:10.2319/010509-10.1.
30. Newtom Cone Beam 3D Imaging: What's Next. <http://www.newtom.it/en/products/newtom-5g/#block-moreinfo>. 2014:1–10.
31. Lin EC. Radiation risk from medical imaging. *Mayo Clin Proc.* 2010;85(12):1142–6; quiz 1146. doi:10.4065/mcp.2010.0260.
32. Baccetti T, Franchi L, McNamara J a. An improved version of the cervical vertebral maturation (CVM) method for the assessment of mandibular growth. *Angle Orthod.* 2002;72(4):316–23. doi:10.1043/0003-3219(2002)072<0316:AIVOTC>2.0.CO;2.
33. Baccetti T, Franchi L, McNamara J a. The Cervical Vertebral Maturation (CVM) Method for the Assessment of Optimal Treatment Timing in Dentofacial Orthopedics. *Semin Orthod.* 2005;11(3):119–129. doi:10.1053/j.sodo.2005.04.005.
34. Yushkevich PA, Piven J, Hazlett HC, et al. User-guided 3D active contour segmentation of anatomical structures: Significantly improved efficiency and reliability. *Neuroimage.* 2006;31(3):1116–1128.
35. Vanarsdall RL. Transverse dimension and long-term stability. *Semin Orthod.* 1999;5:171–180. doi:10.1016/S1073-8746(99)80008-5.
36. Bazargani F, Feldmann I, Bondemark L. Three-dimensional analysis of effects of rapid maxillary expansion on facial sutures and bones. *Angle Orthod.* 2013;83(6):1074–82. doi:10.2319/020413-103.1.

37. Kartalian A, Gohl E, Adamian M, Enciso R. Cone-beam computerized tomography evaluation of the maxillary dentoskeletal complex after rapid palatal expansion. *Am J Orthod Dentofacial Orthop.* 2010;138(4):486–92. doi:10.1016/j.ajodo.2008.10.025.
38. Lagravère MO, Gamble J, Major PW, Heo G. Transverse dental changes after tooth-borne and bone-borne maxillary expansion. *Int Orthod.* 2013;11:21–34. doi:10.1016/j.ortho.2012.12.003.
39. Williams MO, Murphy NC. Beyond the Ligament: A Whole-Bone Periodontal View of Dentofacial Orthopedics and Falsification of Universal Alveolar Immutability. *Semin Orthod.* 2008;14(4):246–259. doi:10.1053/j.sodo.2008.07.003.
40. Akyalcin S, Schaefer JS, English JD, Stephens CR, Winkelmann S. A cone-beam computed tomography evaluation of buccal bone thickness following maxillary expansion. *Imaging Sci Dent.* 2013;43(2):85–90. Available at: <http://www.pubmedcentral.nih.gov/articlerender.fcgi?artid=3691378&tool=pmcentrez&rendertype=abstract>.
41. Bazargani F, Feldmann I, Bondemark L. Three-dimensional analysis of effects of rapid maxillary expansion on facial sutures and bones. *Angle Orthod.* 2013;83(6):1074–82. doi:10.2319/020413-103.1.
42. Goldenberg DC, Goldenberg FC, Alonso N, et al. Hyrax appliance opening and pattern of skeletal maxillary expansion after surgically assisted rapid palatal expansion: a computed tomography evaluation. *Oral Surg Oral Med Oral Pathol Oral Radiol Endod.* 2008;106(6):812–9. doi:10.1016/j.tripleo.2008.02.034.
43. Article O. Immediate effects of rapid maxillary expansion with Haas-type and hyrax-type expanders: A randomized clinical trial. :366–376. doi:10.1016/j.ajodo.2010.07.025.
44. Ballanti F, Lione R, Baccetti T, Franchi L, Cozza P. Treatment and posttreatment skeletal effects of rapid maxillary expansion investigated with low-dose computed tomography in growing subjects. *Am J Orthod Dentofacial Orthop.* 2010;138(3):311–7. doi:10.1016/j.ajodo.2008.10.022.
45. Christie KF, Boucher N, Chung C. Effects of bonded rapid palatal expansion on the transverse dimensions of the maxilla: A cone-beam computed tomography study. *Am J Orthod Dentofac Orthop.* 137(4):S79–S85. doi:10.1016/j.ajodo.2008.11.024.
46. Ballanti F, Lione R, Fanucci E, Franchi L, Baccetti T, Cozza P. Immediate and post-retention effects of rapid maxillary expansion investigated by computed tomography in growing patients. *Angle Orthod.* 2009;79(1):24–9. doi:10.2319/012008-35.1.
47. Lione R, Ballanti F, Franchi L, Baccetti T, Cozza P. Treatment and posttreatment skeletal effects of rapid maxillary expansion studied with low-dose computed tomography in

- growing subjects. *Am J Orthod Dentofacial Orthop.* 2008;134(3):389–92.
doi:10.1016/j.ajodo.2008.05.011.
48. Prado GPR, Furtado F, Aloise AC, Biló JPR, Masako Ferreira L, Pereira MD. Stability of surgically assisted rapid palatal expansion with and without retention analyzed by 3-dimensional imaging. *Am J Orthod Dentofacial Orthop.* 2014;145(5):610–616.
doi:10.1016/j.ajodo.2013.12.026.
 49. Gurgel J a, Tiago CM, Normando D. Transverse changes after surgically assisted rapid palatal expansion. *Int J Oral Maxillofac Surg.* 2014;43(3):316–22.
doi:10.1016/j.ijom.2013.10.001.
 50. Gauthier C, Voyer R, Paquette M, Rompré P, Papadakis A. Periodontal effects of surgically assisted rapid palatal expansion evaluated clinically and with cone-beam computerized tomography: 6-month preliminary results. *Am J Orthod Dentofacial Orthop.* 2011;139(4 Suppl):S117–28. doi:10.1016/j.ajodo.2010.06.022.
 51. Gohl E, Nguyen M, Enciso R. Three-dimensional computed tomography comparison of the maxillary palatal vault between patients with rapid palatal expansion and orthodontically treated controls. *Am J Orthod Dentofac Orthop.* 2010;138:477–485.
doi:10.1016/j.ajodo.2008.12.025.