

UCLA

UCLA Previously Published Works

Title

Intravascular ultrasound cross-sectional arterial imaging before and after balloon angioplasty in vitro.

Permalink

<https://escholarship.org/uc/item/811133n0>

Author

TOBIS, JM

Publication Date

1989

Copyright Information

This work is made available under the terms of a Creative Commons Attribution License, available at <https://creativecommons.org/licenses/by/4.0/>

Peer reviewed

Intravascular Ultrasound Cross-Sectional Arterial Imaging Before and After Balloon Angioplasty In Vitro

Jonathan M. Tobis, MD, John A. Mallery, MD, Jim Gessert, PhD, Jim Griffith, PhD, Don Mahon, MD, Matthew Bessen, MD, Masahito Moriuchi, MD, Lachlan McLeay, MD, Michael McRae, MD, and Walter L. Henry, MD

A prototype ultrasound imaging catheter was evaluated in vitro using 17 human atherosclerotic artery segments before and after balloon dilatation angioplasty. The catheter was 1.2 mm in diameter and incorporated a single 20-MHz ultrasound transducer to obtain cross-sectional images of the arterial lumen. In 15 of the 17 (88%) arteries, high quality images were obtained, which demonstrated clear demarcation between the lumen and the endothelium, the atheroma plaque, the muscular media, and the adventitia. Qualitative characteristics of plaque disruption, dissection, and residual flaps were readily visible. In addition, quantitative information about cross-sectional lumen area was obtained before and after balloon dilatation. The mean cross-sectional lumen area increased from 8.7 to 15.1 mm² ($p < 0.01$) following balloon dilatation. The lumen area measured from the ultrasound images following dilatation correlated closely with the area measured from histologic sections ($r = 0.88$). The results from this study indicate that a small-diameter ultrasound imaging catheter can be developed that will provide high-resolution qualitative and quantitative information during peripheral and coronary angioplasty. (*Circulation* 1989;80:873-882)

A wide variety of therapeutic procedures have been developed to intervene in patients with coronary artery disease. Whether the intervention is intended to increase lumen size by dilating the artery or to decrease atheroma mass by laser ablation, mechanical atherectomy, or by lowering serum cholesterol, it will be important to quantify atherosclerotic plaque volume before and after treatment. Current diagnostic methods include angiography, which provides an assessment of the narrowing of the lumen due to the atheroma, and intravascular angioscopy, which reveals information about the appearance and topography of the luminal surface.^{1,2} However, neither of these methods allows assessment of the size, location, and composition of the atheroma. Ultrasound is an imaging modality that potentially would provide this information.³ Until now, ultrasound imaging of coronary arteries has been limited because of diffi-

culty in visualizing the coronary tree with a transcatheter approach.⁴⁻⁶ Recent work has shown that it is feasible to image arteries in cross section using a catheter-mounted ultrasound transducer that generates arterial images from inside the artery lumen.⁷⁻⁹ The purpose of this study was twofold: first, to assess the ability of a newly developed intravascular ultrasound catheter to generate cross-

See p 1091

sectional images of human atherosclerotic artery segments in vitro; and second, to visualize the effects of balloon dilatation, as well as measure the luminal cross-sectional area before and after balloon dilatation.

Methods

A prototype ultrasound imaging catheter (Intertherapy Inc., Costa Mesa, California) was used in this study. A single 20-MHz ultrasound transducer was located in the distal end of a 1.2-mm diameter catheter. The transducer was oriented so that the ultrasound energy was transmitted against a mirror and deflected perpendicular to the long axis of the catheter (Figure 1). The reason for choosing this mirror design is that it permits imaging an artery with a diameter as small as the diameter of the catheter shaft (1.2 mm). A cross-sectional image

From the University of California-Irvine, Divisions of Cardiology and Pathology, Irvine Medical Center, Irvine, California.

Presented in part at the American Heart Association 61st Scientific Sessions, Washington, DC, November 1988.

Address for reprints: Jonathan M. Tobis, MD, Division of Cardiology, University of California, Irvine Medical Center, P.O. Box 14091, Orange, CA 92613-4091.

Received February 15, 1989; revision accepted June 13, 1989.




FIGURE 1. Left panel: *Prototype ultrasound imaging catheter transducer and mirror are shown along with schematic representation of tip of rigid prototype device (right panel). Single 20-MHz ultrasound transducer is located at distal end of catheter so that ultrasound energy is transmitted against mirror that deflects soundwaves perpendicular to long axis of catheter.*

was obtained by manually rotating the transducer 360° to generate an image of the artery wall. As the catheter was rotated, the cross-sectional image appeared to be painted on the video monitor. The images were both recorded on paper with a Sony

video image transcriber (model UP811) and archived onto a computer disk. To ensure correct alignment, a mounting platform was developed, through which the catheter could be secured and rotated manually by moving a gear (Figure 2).




FIGURE 2. *Mounting apparatus and recording equipment. Imaging catheter has been placed through mounting apparatus to hold it in place. Distal end of transducer is passed through artery segment that is emersed in a beaker of saline. As catheter was rotated, cross-sectional image was generated on video monitor (upper left-hand corner).*

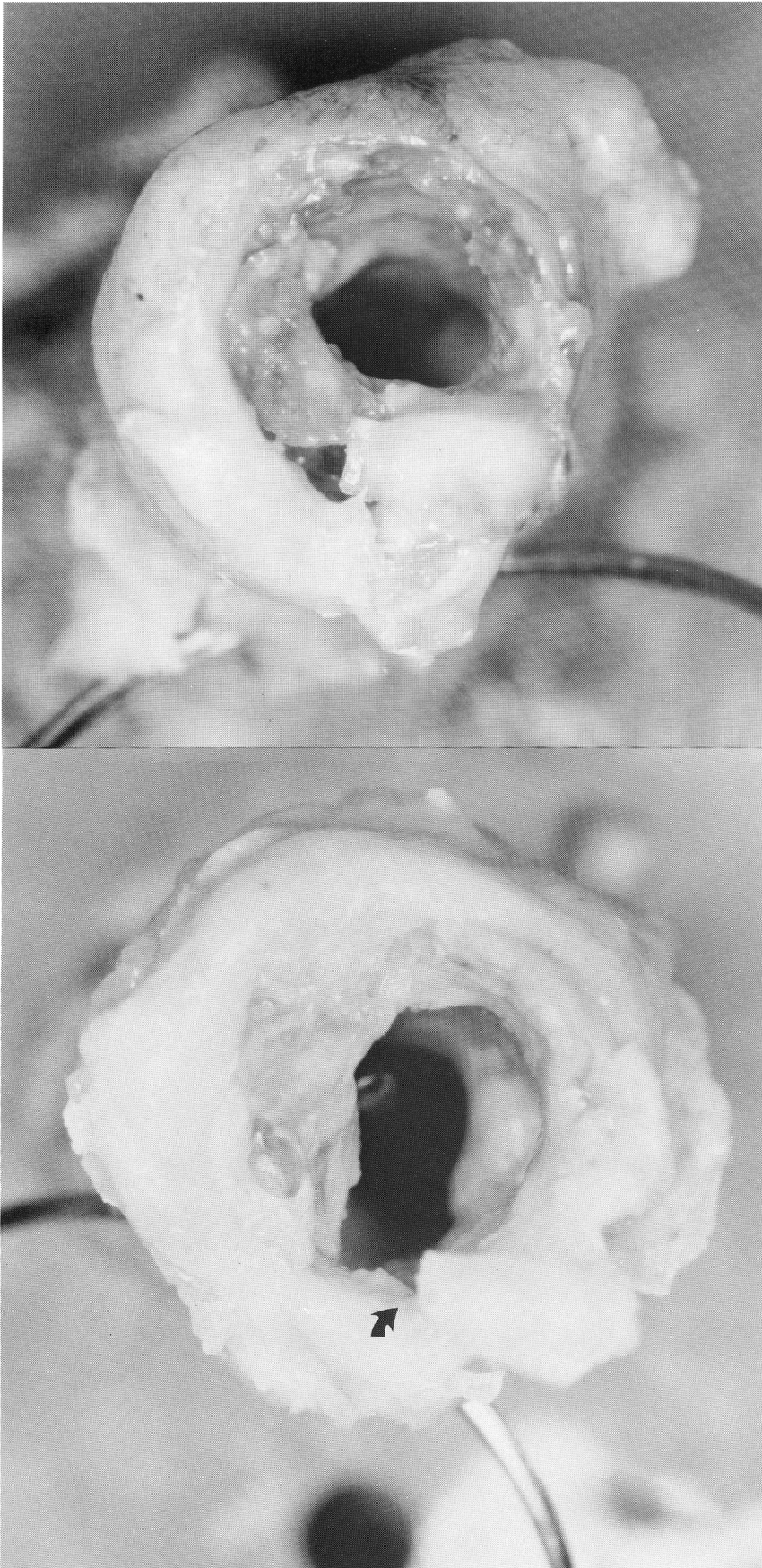

FIGURE 3. Top: Photograph shows an artery segment on end with surgical needle passed perpendicular to wall of artery. Surgical needle was visualized with ultrasound device to establish reference plane so that ultrasound images and histologic sections could be correlated. Bottom: Same arterial segment after balloon dilatation. There is a tear in plaque along inferior wall with separation of torn ends (arrow).

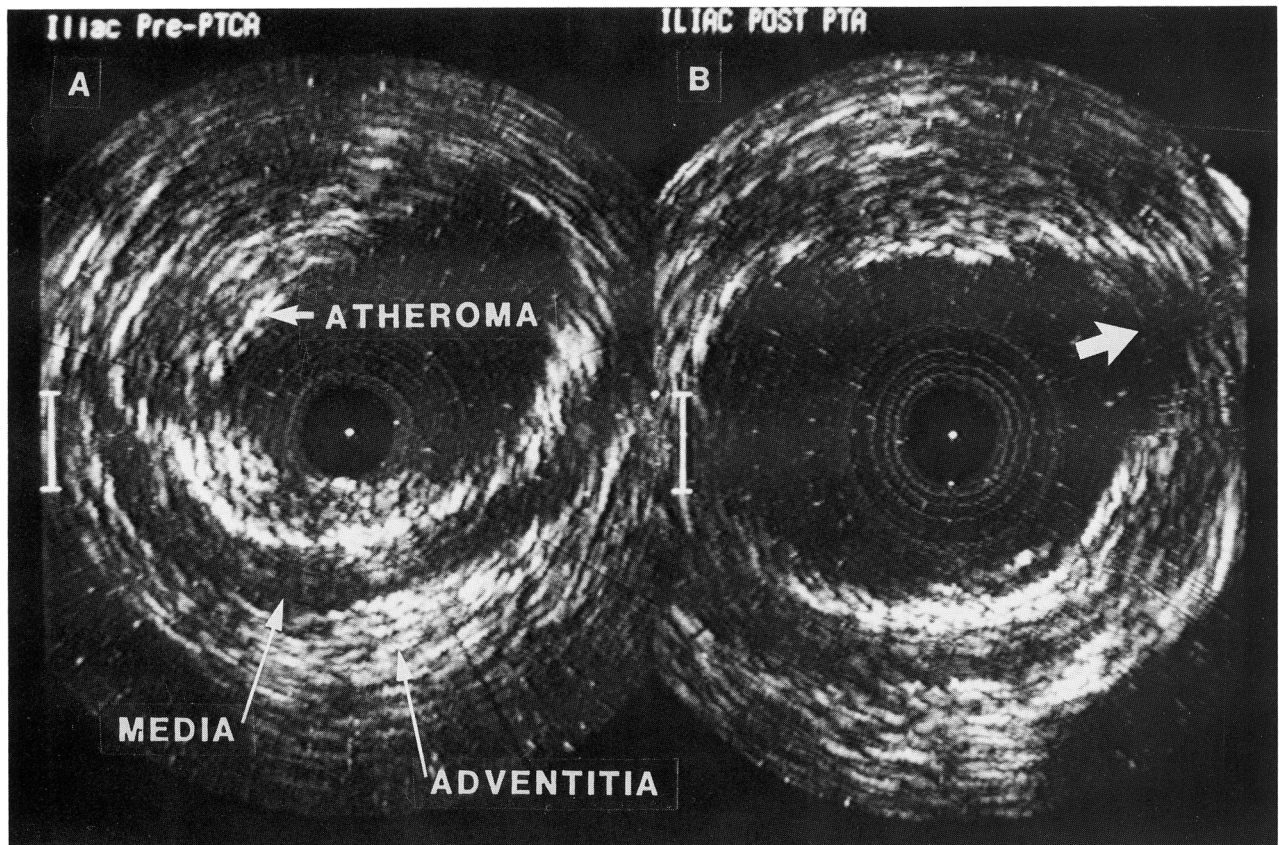


FIGURE 4. Photograph from computer monitor shows pair of ultrasound images from artery before dilatation (on left) and after dilatation (on right). Image was obtained 2.5 mm below reference line of needle. Artery was only moderately diseased. Central black area is where transducer is located. Echo-free lumen is clearly delineated from fibrous atheroma plaque, which has high echo reflectance. Muscular media has low echogenicity and surrounding adventitia shows high echo reflectance. After balloon dilatation, artery cross-sectional area is increased and there is a minor tear in plaque (arrow).

Human atherosclerotic arteries were obtained at autopsy or after lower extremity amputation. Arteries were obtained from the coronary, iliac, femoral, and tibial systems. A variety of arteries were used to assess the ability of the catheter to image a wide range of lumen and atheroma dimensions. Each artery was cut into 2-cm long segments. The artery segments were mounted on end on a plastic platform using a quick-drying glue. The tip of the ultrasound catheter and the mounted artery segment were placed in a small beaker of saline. Care was taken to wash all air bubbles from the artery segment and catheter tip. The short artery sections were firm enough to permit the catheter to remain coaxial with the long axis of the artery. This alignment assisted in obtaining optimal images. If the long axis of the catheter is more than 15° off the long axis of the artery, then there will be dropout of the reflected ultrasound.

Seventeen artery sections were imaged at 1-mm intervals along the length of the artery segment before dilatation by adjusting a calibrated screw attached to the transducer mount. To obtain correct alignment and reference with the histologic sec-

tions, a surgical needle that could be visualized with the ultrasound device was passed perpendicular to the long axis of the artery and used as a reference (Figure 3). After initial imaging, the artery segment was removed from the plastic mount and dilated with an appropriately sized coronary or peripheral artery balloon. The balloon diameter was chosen so that the inflated diameter of the balloon was 1.0 to 1.3 times the diameter of the artery. After dilatation, the artery sections were remounted onto the plastic base with glue and replaced within the beaker of saline. Care was taken to align the artery in an orientation similar to the one used to obtain the initial images. A second set of ultrasound images were then acquired at 1-mm increments, at the same levels as were imaged prior to dilatation.

After the study of each artery was completed, the computer images were restored from the disk. Measurements were made of the cross-sectional area of the lumen predilatation and postdilatation along the length of the artery, and compared by a paired *t* test. Histologic sections were prepared from the arterial segments. The arteries were placed in formalin for 1 to 7 days. They were decalcified using

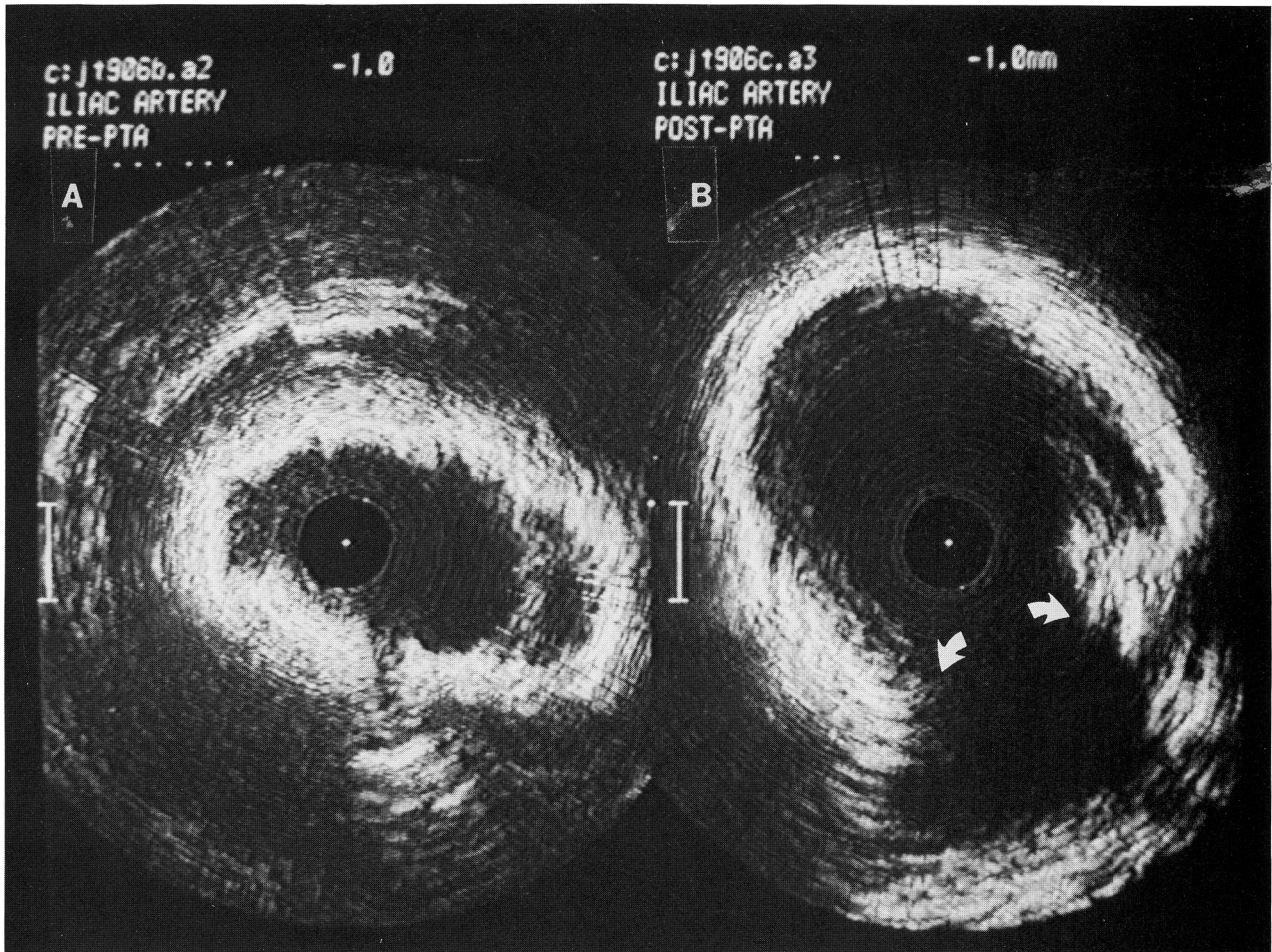


FIGURE 5. Pair of ultrasound images obtained from arterial segment shown in Figure 3. On left is artery before balloon dilatation and on right is image after angioplasty. In ultrasound image prior to balloon angioplasty, although outline of internal lumen is well demarcated, extensive fibrosis and calcification present within plaque strongly reflected ultrasound waves and prevented visualization of much of media and adventitia layers. After balloon dilatation, lumen has increased substantially in area, primarily due to separation of torn ends of plaque (arrows).

RDO solution of hydrochloric acid (Apex Corp) for 1 hour. The arteries were marked with india ink at the level where the reference needle had been placed. They were imbedded in paraffin blocks and cut into 6- μ m-thick segments at intervals of 1 mm. The sections were stained with hematoxylin and eosin. Quantitative measurements were made from photographs of the histologic sections using a calibrated digitized pad (Kurta pad and Cadd software by Generic). The histologic cross-sectional measurements were compared by linear regression analysis to the postdilatation ultrasound image measurements.

To address the problem of arterial shrinkage induced by formalin fixation, five separate artery segments were imaged by the ultrasound catheter before and after fixation in formalin at 4 and 7 days. Each artery was imaged at the level of the reference needle and at 1 and 2 mm above and below the needle. The 25 cross-sectional measurements before fixation were compared to the ultrasound measurements after fixation by a paired *t* test.

Results

Of the 17 artery segments studied, two arteries could not be imaged adequately by the intravascular ultrasound catheter due to technical imperfections in an early prototype model. In two other arteries, the histologic sections were inadequate for analysis due to damage during fixation. A representative ultrasound image pair, before and after balloon dilatation, is demonstrated in Figure 4 from an artery section that was only moderately diseased. In all 15 of the specimens in which adequate images were obtained, the echo-free lumen was clearly delineated. Of the 15 arteries, the fibrous plaque was seen as a region of high echo reflectance, as was the adventitia, whereas the muscular media was seen as a region of low echogenicity. In four arteries, extensive fibrosis and calcification present within the plaque strongly reflected the ultrasound waves and prevented visualization of large regions of the media and adventitial layers (Figure 5).

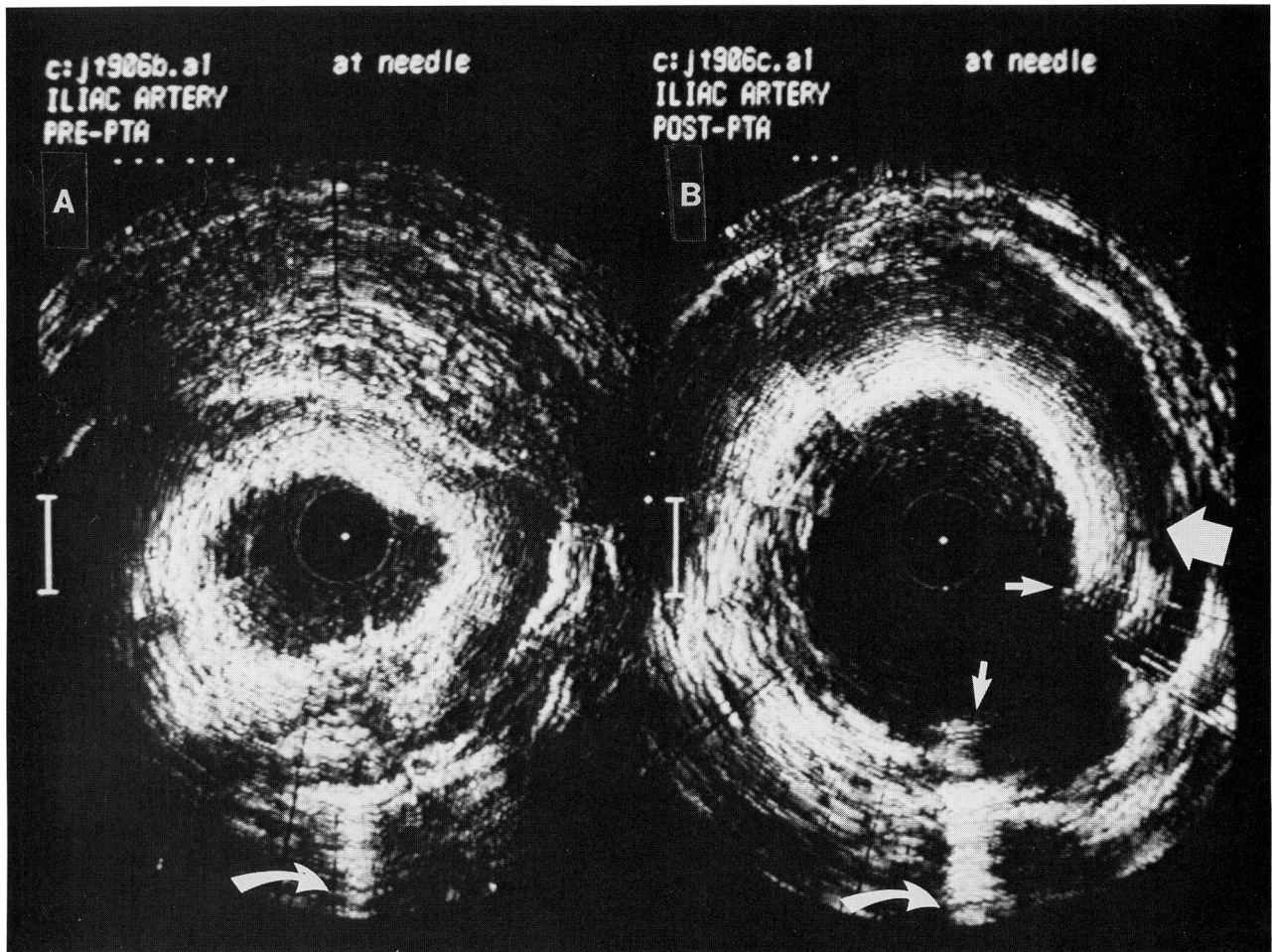


FIGURE 6. Composite photograph demonstrates ultrasound images from another severely diseased artery before (A) and after (B) dilatation. Needle artifact is seen in inferior aspect of images (curved arrow). Lumen is enlarged with fracture at densely calcified plaque and separation of torn ends (arrows). Moreover, there is new lucency (thick arrow) that may represent dissection with separation of intimal plaque from media.

The ultrasound and histologic images were analyzed for evidence of plaque tears and dissection postdilatation. The criterion for making a diagnosis of plaque tear was the observation of a fracture of the intimal plaque with separation of the torn ends as shown in the postdilatation image in Figure 6. There also appears to be a new lucency caused by separation of the intimal plaque from the media. The corresponding histologic cross-section from the artery segment visualized in Figure 6 is shown in Figure 7. A fracture of the intimal plaque with separation of the torn ends, as well as separation of the plaque from the media, are seen. In most arteries studied, balloon dilatation created a tear through the plaque, which typically was located through the thinnest region of the atheroma or at the junction of the plaque and normal artery wall. The tear also produced a dissection plane between the plaque and the internal elastic membrane. The artery was stretched in this region, which resulted in enlargement of the internal lumen. In several

instances, the ultrasound images also visualized the presence of an intimal flap (Figure 8).

The number of tears in the arterial plaque seen by ultrasound and by histology following balloon dilatation is shown in Figure 9. The ultrasound images accurately predicted the histologic presence or absence of tears in 11 of the 13 artery segments in which matched ultrasound and histologic sections were available.

To determine the accuracy of the intravascular ultrasound measurement of lumen area, the lumen cross-sectional area obtained by ultrasound was compared with measurements obtained from the histology sections at multiple sites along the length of each artery segment. Images were obtained at the level of the reference needles, as well as 1 and 2 mm above and below the needle. The number of measurement pairs available for each artery varied between three and five. Figure 10 demonstrates the correlation of cross-sectional area obtained with the intravascular ultrasound catheter to those obtained

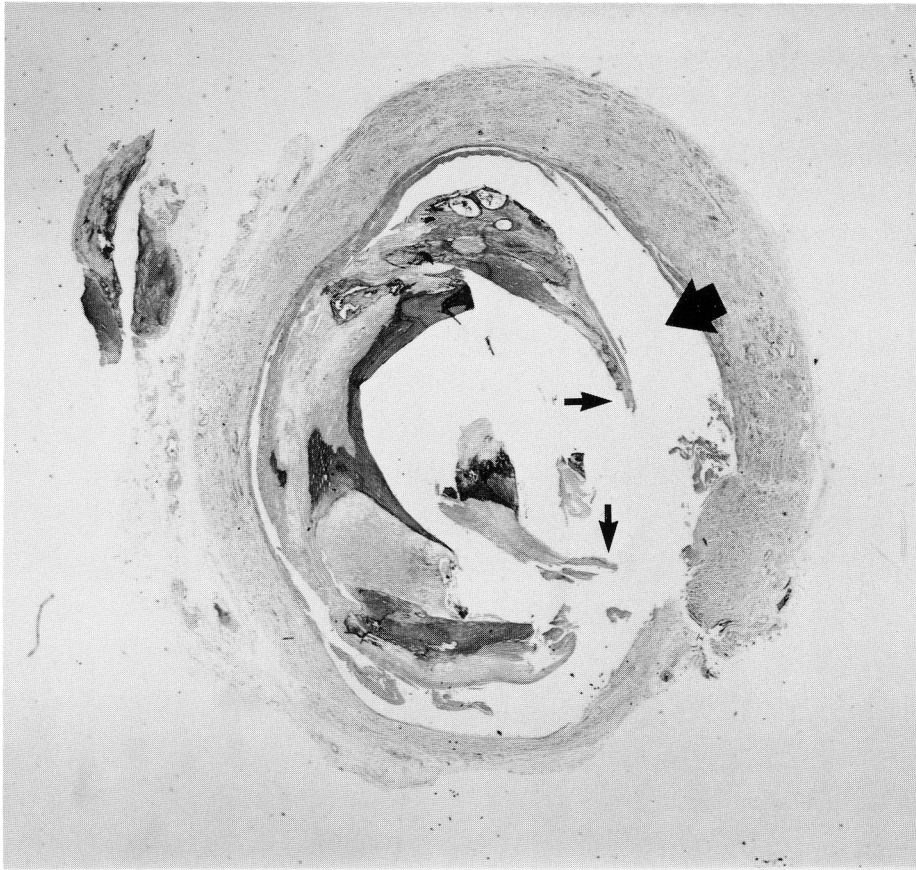


FIGURE 7. *Histologic section was obtained from same artery as ultrasound images from Figure 6 at level of needle in artery. Disruption of intimal plaque with separation of torn ends of plaque wall is seen (arrows). In addition, there is separation of plaque from medial wall (thick arrow). In this instance, ultrasound image has correctly predicted position and extent of dissection as seen on histology.*

from histology for 39 paired postdilatation sections. The correlation coefficient was 0.88 and the standard error of the estimate was 3.2 mm^2 . The measurements were related by the equation: Lumen area (ultrasound) = $(0.94 \times \text{lumen area [histology]}) + 0.52 \text{ mm}^2$.

Ultrasound cross-sectional areas were compared before and after balloon dilatation to assess the magnitude of the increase in lumen area produced by balloon dilatation. In each of the 15 artery segments in which adequate ultrasound images were obtained, the cross-section that showed the greatest percent change in lumen area following dilatation was determined. The maximal luminal area increased on average from 8.7 to 15.1 mm^2 ($p < 0.01$) following dilatation (Figure 11).

In the five artery segments that were measured by ultrasound before and after formalin fixation, the mean cross-sectional area was 29.9 ± 16.5 before and $28.7 \pm 15.5 \text{ mm}^2$ after immersion in formalin for 4 days. This only represents a 4% change in measured lumen area attributable to the formalin fixation process, however, it did achieve statistical significance ($p < 0.05$). After fixation in formalin for 7 days, the mean cross-sectional lumen area did not change ($28.7 \pm 15.4 \text{ mm}^2$) from the measurement at 4 days.

Discussion

A method of assessing the degree to which an atheroma plaque has been disrupted by interven-

tional methods during percutaneous procedures would be very beneficial. An intravascular ultrasound catheter, such as the one described in this report, would provide quantitative information about the distribution and quality of the atheroma prior to and following a balloon dilatation procedure.¹⁰ In addition, the ultrasound transducer could be configured within an angioplasty balloon to visualize the arterial wall in cross section during the dilatation. Visualization of the atheroma and arterial wall also would be beneficial in helping to characterize the type of tissue within the plaque that potentially suggests which of several alternative therapies would be most effective.

In this study, a 1.2-mm diameter prototype intravascular ultrasound imaging catheter was used to visualize isolated human atherosclerotic artery segments and measure their cross-sectional area before and after balloon dilatation. The laboratory conditions under which the images were obtained were tightly controlled, which facilitated the acquisition of high quality pictures. Under these conditions, the inner boundary of both the atherosclerotic intima and the normal wall (i.e., the arterial lumen) was well visualized in 15 of 17 arteries studied. In arteries with moderate disease, the intimal plaque, echo-lucent muscular media, and echo-reflective adventitia were well visualized both before and after balloon angioplasty. In more severely diseased

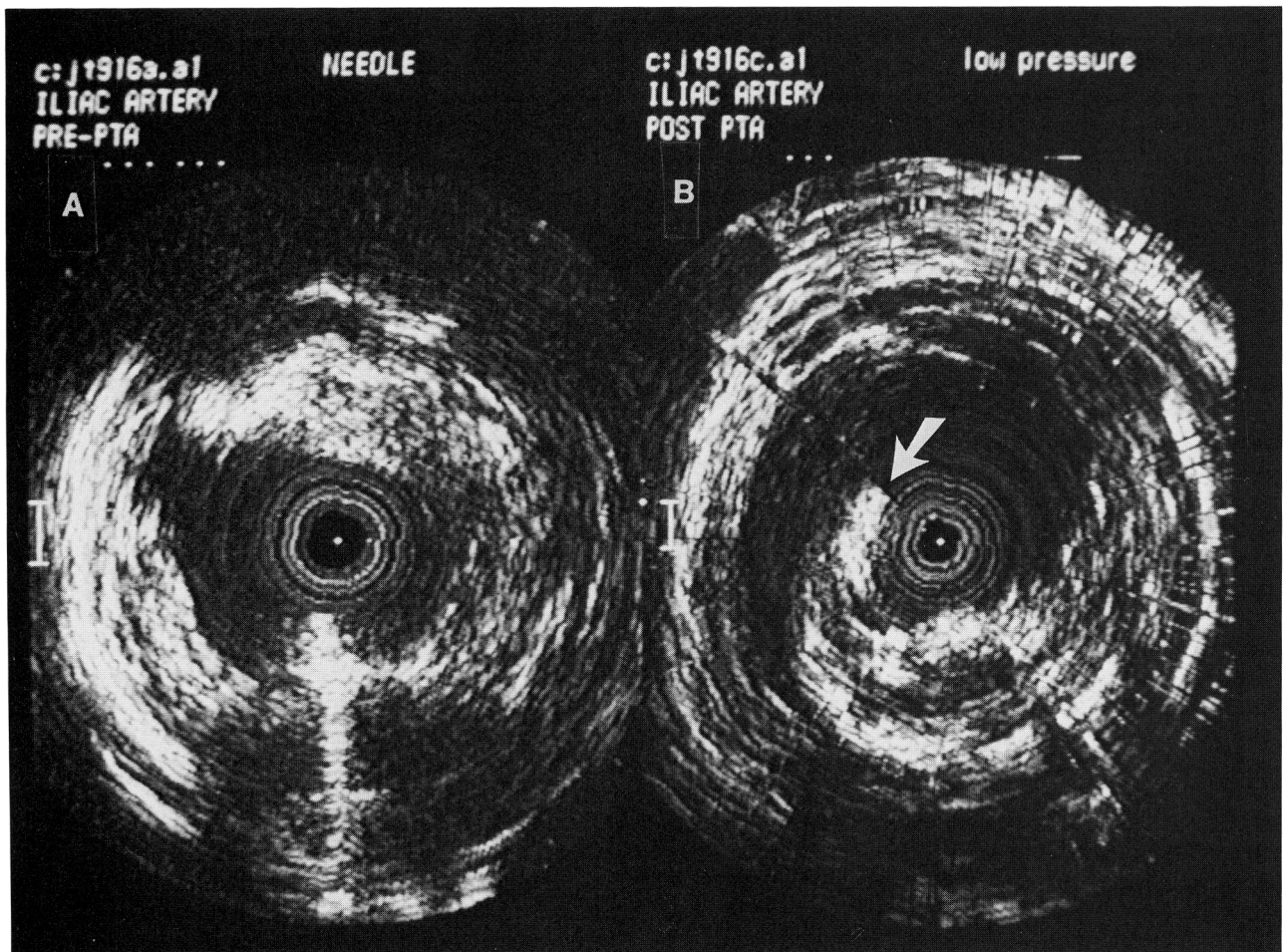


FIGURE 8. In composite photograph of ultrasound images from another artery before (A) and after (B) balloon dilatation, not only was arterial plaque torn, but intimal flap is seen to protrude into lumen (arrow).

arteries, areas of dense fibrous and calcified tissue prevented visualization of the media and adventitia. In these arteries, the extremely intense echo reflections often produced a loss of echo signal from regions outside the fibrocalcified layer. Even in these heavily diseased arteries, however, luminal area was readily visible for quantitative analysis both before and following the balloon intervention.

The lateral resolution of the 20-MHz ultrasound transducer is 0.35 mm.^{11,12} In addition to the high

		ARTERIAL TEARS OBSERVED	
		HISTOLOGY +	HISTOLOGY -
ULTRA SOUND	+	10	0
	-	2	1

FIGURE 9. Presence of tear in arterial plaque as seen by ultrasound or by histology after balloon dilatation is demonstrated in chart. Criterion for making diagnosis of tear was observation of fracture of intimal plaque with separation of torn ends. Ultrasound images accurately predicted histologic presence or absence of tears in 11 of 13 cases.

ULTRASOUND IMAGING CATHETER HISTOLOGIC CORRELATION

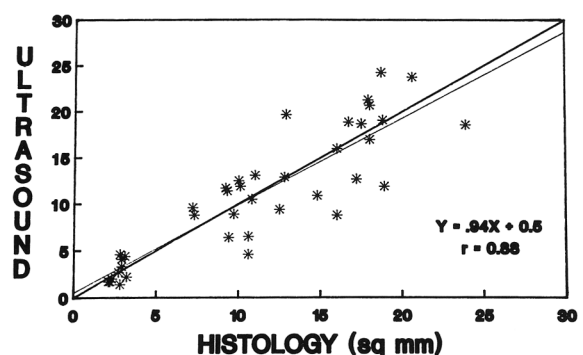


FIGURE 10. To determine accuracy of measurements of lumen area, ultrasound lumen cross-sectional area was compared with measurements obtained from histologic sections at multiple sites along length of each artery segment. Correlation coefficient was 0.88 for measurements of cross-sectional area obtained with intravascular ultrasound catheter (y axis), as compared with measurements from histology (x axis).

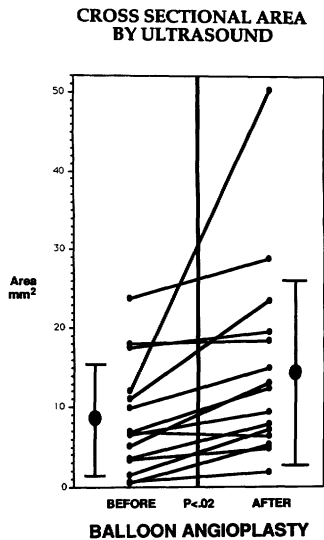


FIGURE 11. Maximal change in cross-sectional area, as measured by ultrasound catheter, for each of 15 arteries is plotted. Maximal luminal area increased on average from 8.7 to 15.1 mm² after dilatation.

spatial resolution, several groups have reported on the ability of ultrasound devices to delineate the high echo reflectance of atherosclerotic plaque and adventitia from the echolucent media.^{13,14} The difference in the ability of high frequency ultrasound to distinguish these tissue characteristics is believed to be a function of the greater reflection of sound-waves from the collagen content of fibrous tissue compared with that of smooth muscle cells in the media. These studies also demonstrated by histologic correlation that areas of calcification reflect most of the ultrasound energy and prevent penetration beyond the area of calcium. On the ultrasound image, this is recognized by echo "drop out" or shadowing beyond an area of bright reflectance.

In most artery segments that underwent balloon dilatation, a longitudinal tear through the thinnest region of the plaque or along the lateral boundary of the plaque and the arterial wall was visualized by intravascular ultrasound. These observations are similar to previously reported histologic studies.¹⁵ The presence or absence of a torn plaque and separation of a portion of the plaque from the internal elastic membrane was visualized correctly with the ultrasound catheter in 11 of the 13 artery segments. The discordance in two arteries may be due to the inability of the ultrasound image to distinguish a tear when it is pressed up against the arterial wall, or the tears may have been artifactually produced by the histologic preparation. It is well known that histologic preparation may create artificial clefts or tears. The criterion that was used to distinguish artifacts was if the tear on the histologic section appeared to be caused by the blade as it swept across the section and pulled any area of residual calcium with it.

The correlation of the cross-sectional lumen area between the ultrasound images and the histologic sections was close ($r=0.88$). The SEE was 3.2 mm² around the linear regression line. There are several sources of error in trying to compare the area by ultrasound with histologic sections. The histologic preparation may produce artifactual compression and distortion, especially after balloon angioplasty when the integrity of the arterial wall may be compromised. In addition, fixation in formalin may produce shrinkage of the tissue. Our ultrasound images that were performed before and after formalin fixation demonstrated a 4% difference between the two measurements, which may account for some of the variation in measurements of area between the ultrasound and histologic sections. For these reasons, it is possible to speculate that ultrasound calculations in vivo may be a more accurate determination of the true size of anatomic structures than are measurements derived after histologic preparation.

The quality of the ultrasound images was maximized by fixing the transducer in a rigid mount and coaxially aligning the catheter and the artery in a stationary bath environment. The purpose of this study was to demonstrate that the ultrasound catheter has the potential of visualizing and quantifying the effect of balloon dilatation with an intravascular device. For optimal studies in patients, the intravascular catheter must be flexible, atraumatic, and rotate by a mechanical drive with real-time image display. Although there may be numerous technical difficulties when transferring this methodology to living patients, the results from this study are encouraging and suggest that ultrasound energy can be configured with a small catheter to intravascularly interrogate and quantify human atherosclerosis.

References

1. Vlodaver Z, Frech R, Van Tassel RA, Edwards JE: Correlation of the antemortem coronary arteriogram and the postmortem specimen. *Circulation* 1973;47:162-169
2. Eusterman JH, Achor RWP, Kincaid OW, Brown AL Jr: Atherosclerotic disease of the coronary arteries: A pathologic-radiologic correlative study. *Circulation* 1962;26:1288-1295
3. Yao JS, Flinn WR, Bergan JJ: Noninvasive vascular diagnostic testing: Techniques and clinical applications. *Prog Cardiovasc Dis* 1984;26:459-494
4. Hiratzka LF, McPherson DD, Lamberth WC, Brandt B, Armstrong ML, Schröder E, Hunt M, Kieso R, Megan MD, Tompkins PK, Marcus ML, Kerber RE: Intraoperative evaluation of coronary artery bypass graft anastomoses with high-frequency epicardial echocardiography: Experimental validation and initial patient studies. *Circulation* 1986; 73:1199-1205
5. Sahn DJ, Barratt-Boyes BG, Graham K, Kerr A, Roche A, Hill D, Brandt PW, Copeland JG, Mammanna R, Temkin LP, Glenn W: Ultrasound imaging of the coronary arteries in open-chested humans: Evaluation of coronary atherosclerotic lesions during cardiac surgery. *Circulation* 1982; 66:1033-1044
6. McPherson DD, Hiratzka LF, Lamberth WC, Brandt B, Hunt M, Kieso RA, Marcus ML, Kerber RE: Delineation of the extent of coronary atherosclerosis by high-frequency

- epicardial echocardiography. *N Engl J Med* 1987; 316:304-309.
7. Mallery JA, Griffith J, Gessert J, Morcos NC, Tobis JM, Henry WL: Intravascular ultrasound imaging catheter assessment of normal and atherosclerotic artery wall thickness (abstract). *J Am Coll Cardiol* 1988;11:22A
 8. Yock PG, Johnson EL, David DT: Intravascular ultrasound: Development and clinical potential. *Am J Cardiac Imaging* 1988;2:185-193
 9. Mallery JA, Gregory K, Morcos NC, Griffith J, Henry WL: Evaluation of an ultrasound balloon dilatation imaging catheter. *Circulation* 1987;76:IV-371
 10. Bom N, Slager CJ, Van Egmond FC, Lancee CT, Serruys PW: Intra-arterial ultrasonic imaging for recanalization by spark erosion. *Ultrasound Med Biol* 1988;14:257-261
 11. Gessert JM, Krinke C, Mallery J, Zalesky P: Display consideration for intravascular ultrasonic imaging. Society of Photo-Optical Instrumentation Engineers, Proceedings of OE Laser Technical Program 1989; Vol 1068-30
 12. Griffith J, Maciel M, Zalesky P: Factors influencing ultrasound echoes from arterial walls. Society of Photo-Optical Instrumentation Engineers, Proceedings of Microsensors and Catheter-Based Imaging Technology, 1988;904:100-102
 13. Bartorelli AL, Potkin BN, Almagor Y, Gessert JC, Roberts WC, Leon MB: Intravascular ultrasound imaging of atherosclerotic coronary arteries: An in vitro validation study. *J Am Coll Cardiol* 1989;13(2):4A
 14. Pandian N, Kreis A, O'Donnell T, Sacharoff A, Boleza E, Caro R: Intraluminal two-dimensional ultrasound angioscopic quantitation of arterial stenosis: Comparison with external high-frequency ultrasound imaging and anatomy. *J Am Coll Cardiol* 1989;13(2):5A
 15. Lyon RT, Zarins CK, Lu C-T, Yang C-F, Glagov S: Vessel, plaque, and lumen morphology after transluminal balloon angioplasty: Quantitative study in distended human arteries. *Arteriosclerosis* 1987;7:306-314
-
- KEY WORDS • atherosclerosis • balloon dilatation • ultrasonic diagnosis