

# UC Irvine

## UC Irvine Previously Published Works

### Title

Structural and Functional Alterations at Pre-Epileptic Stage Are Closely Associated with Epileptogenesis in Pilocarpine-induced Epilepsy Model

### Permalink

<https://escholarship.org/uc/item/7wh8j98v>

### Journal

EXPERIMENTAL NEUROBIOLOGY, 26(5)

### ISSN

1226-2560

### Authors

Kim, Hani

Choi, Yunsook

Joung, Hye-Young

et al.

### Publication Date

2017

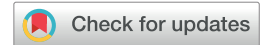### DOI

10.5607/en.2017.26.5.287

### Copyright Information

This work is made available under the terms of a Creative Commons Attribution License, available at <https://creativecommons.org/licenses/by/4.0/>

Peer reviewed



# Structural and Functional Alterations at Pre-Epileptic Stage Are Closely Associated with Epileptogenesis in Pilocarpine-induced Epilepsy Model

Hani Kim<sup>1†</sup>, Yunsook Choi<sup>1,2†</sup>, Hye-Young Joung<sup>1,2†</sup>, Yun Seo Choi<sup>1,2</sup>, Hyeon Jin Kim<sup>1,2</sup>,  
Yohan Joo<sup>4</sup>, Jin-Hwan Oh<sup>4</sup>, Hoo Jae Hann<sup>3</sup>, Zang-Hee Cho<sup>4</sup> and Hyang Woon Lee<sup>1,2\*</sup>

*Departments of <sup>1</sup>Neurology, <sup>2</sup>Medical Science, and <sup>3</sup>Anatomy, Ewha Womans University School of Medicine and Ewha Medical Research Institute, Seoul, Korea, <sup>4</sup>Neuroscience Research Institute, Gachon University, Incheon, Korea*

Pilocarpine-induced rat epilepsy model is an established animal model that mimics medial temporal lobe epilepsy in humans. The purpose of this study was to investigate neuroimaging abnormalities in various stages of epileptogenesis and to correlate them with seizure severity in pilocarpine-induced rat epilepsy model. Fifty male Sprague-Dawley rats were subject to continuous video and electroencephalographic monitoring after inducing status epilepticus (SE) and seizure severity was estimated by frequency and total durations of class 3 to 5 spontaneous recurrent seizures (SRS) by modified Racine's classification. The 7.0 Tesla magnetic resonance imaging (MRI) with high resolution flurodeoxyglucose positron emission tomography (FDG-PET) was performed at 3 hours, 1, 3, 7 days and 4 weeks after the initial insult. The initial SRS was observed  $9.7 \pm 1.3$  days after the pilocarpine injection. MRI revealed an abnormal T2 signal change with swelling in both hippocampi and amygdala in acute (day 1 after injection) and latent phases (days 3 and 7), in association with PET hypometabolism in these areas. Interestingly, the mean frequency of class 3 to 5 SRS was positively correlated with abnormal T2 signals in hippocampal area at 3 days. SRS duration became longer with more decreased glucose metabolism in both hippocampi and amygdala at 7 days after pilocarpine injection. This study indicates that development and severity of SRS at chronic phase could be closely related with structural and functional changes in hippocampus during the latent period, a pre-epileptic stage.

**Key words:** Temporal lobe epilepsy, Pilocarpine, Epileptogenesis, MRI, FDG-PET

## INTRODUCTION

Pilocarpine-induced rat epilepsy model is one of the established

animal models mimicking human temporal lobe epilepsy (TLE) [1, 2]. The systemic administration of pilocarpine in rats leads to subsequent abnormalities that share similar pathological findings in human medial TLE. Unlike human clinical studies, animal models allow scientists to assess the acute, latent, and chronic epileptogenic stages [3].

Magnetic resonance imaging (MRI) is the most important technology for initial neuroimaging investigation to detect possible causes of epilepsy and precise seizure localization [4, 5], while other functional neuroimaging methods such as positron emis-

Received July 28, 2017, Revised September 22, 2017,  
Accepted October 5, 2017

\*To whom correspondence should be addressed.

TEL: 82-2-2650-2673, FAX: 82-2-2650-5959

e-mail: leeh@ewha.ac.kr

†These are co-first authors.

sion tomography (PET) and/or single photon emission computed tomography (SPECT) are useful to find additional information for seizure localization [3, 6].

The relationship of these aberrations to the development of epilepsy (i.e. epileptogenesis), progression of chronic epilepsy, and the underlying pathophysiological mechanisms are not completely understood. To date, only a few clinical studies could answer some of the detailed pathophysiologic mechanism during early stage of epileptogenesis and/or pre-epileptic states [3, 7, 8]. Although recent neuroimaging studies including 18-fluorodeoxyglucose PET (<sup>18</sup>FDG-PET) revealed the glucose hypometabolism in rat hippocampus at different time points after pilocarpine administration in relation to cellular alterations evaluated by immunohistochemistry, the actual contribution of these changes for developing epilepsy needs to be elucidated [9]. Especially, the importance of time points in neuroimaging alterations for contributing epileptogenesis are still unknown. Therefore, the investigation of relationship between neuroimaging changes at various time points and the seizure severities in a chronic epilepsy model would be helpful to answer some of these important questions underlying the process of epileptogenesis. The critical time points for epileptogenesis after the initial insult are very important clinically since these periods could be the critical time windows for protective or antiepileptogenic treatment to prevent developing seizures.

In this study, we investigated the relationship between epileptogenic process and neuroimaging abnormalities at various time points in pilocarpine-induced rat epilepsy model. We also performed MRI combined with PET to investigate morphologic and functional brain changes in relation to development of seizures in various stages of the epileptogenesis. We hypothesized that quantitative changes in either structural or functional neuroimaging tests at certain time points after the initial insult (i.e. pilocarpine injection) are correlated with the severities of seizures measured by the frequency and the duration of SRS.

## MATERIALS AND METHODS

### Animals

Twenty-nine adult (7 weeks old) male Sprague-Dawley rats (Orient Animal Cor., Gyeonggi-do, Korea) weighting 280~300 g were used for this study: 14 animals for video-EEG recording and 15 animals for MRI and FDG-PET images. All animals were handled daily for at least 7 days prior to the experiments. The animals had free access to food and water *ad libitum* and they were maintained on a 12 h light-dark cycle (light on from 08:00~20:00 h) under controlled temperature (20~25°C). All experiments were approved by the Institutional Animal Care and Use Committee (IACUC) of

the Ewha Womans University School Medicine.

### EEG surgery and video-EEG recording

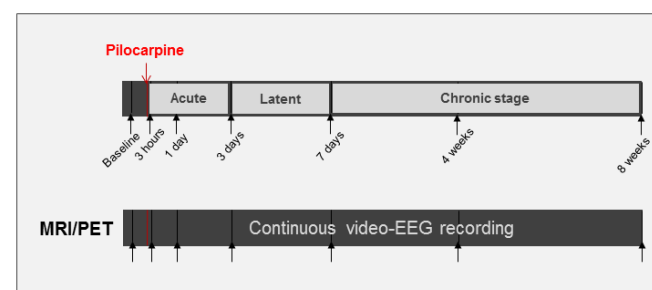
For EEG recordings, steel cortical screw electrodes were placed over the cortex unilaterally as describe in stereotaxic atlas of Paxino and Watson. Under ketamine anesthesia, rats were chronically implanted with the head mount. Two stainless steel screws were implanted through the head mount into four predrilled holes of the skull, and the device was secured with dental cement. After surgery, each rat was allowed 7 days in an individual transparent barrel for recovery.

### Induction of status epilepticus

Animals were injected with pilocarpine hydrochloride (300~380 mg/kg intraperitoneally, Sigma-Aldrich) after 30 min of methylscopolamine injection to induce SE similar to previous studies [1, 2, 10, 11]. Diazepam was administrated 8.6 mg/kg (Sigma-Aldrich) depending on the seizure severity after 120 min of initial SE. Animal that did not ad SE after pilocarpine injection were additionally injected with pilocarpine (110 mg/kg). The schematic design of this study was summarized in Fig. 1.

### Monitoring of behavioral symptoms for determining SE and spontaneous seizures

For seizure recordings, the rats were placed individually in custom-made 15×40×25 cm Acryl cages, and performed continuous video-EEG recording systems (Twin 7.0, Grass-Telefactor, West Warwick, RI, USA) after the pilocarpine injection where each channel was sampled rate of 200Hz and filtered using digital high-and low-pass filters at cutoff frequencies of 0.1 Hz and 70 Hz, respectively. All animals developed SE after the pilocarpine injection, and developed spontaneous recurrent seizures (SRS) approximately 1~2 weeks after the initial SE. The severity of SE and



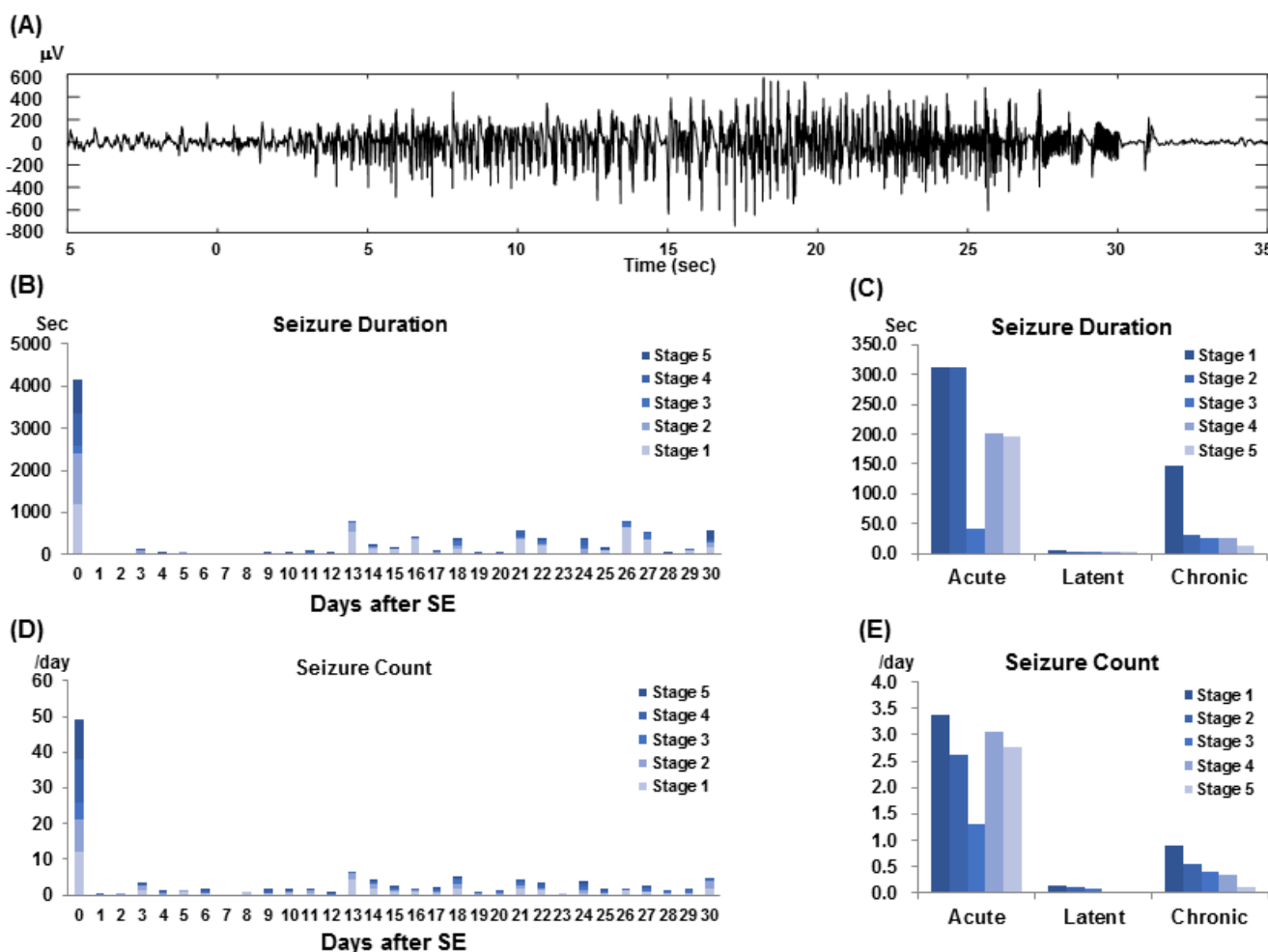
**Fig. 1.** Schematic summary of study design. MRI in 16 and FDG-PET in 25 animals were performed at 7 time points; normal condition (baseline), acute phase (3 hours, 1 day after the initial insult), latent phase (3 days and 7 days), and chronic phase (4 and 8 weeks). Continuous video recording was performed in all animals for neuroimaging studies.

SRS were rated as class 1 to 5 by modified Racine classification [12], but only class 3 to 5 SRS were counted for the duration and frequency to assess seizure severity. Racine's criteria is as follows: stage 1, stereotype mouth movement, eye blinking and/or mild facial clonus; stage 2, head nodding and/or sever facial clonus; stage 3, myoclonic jerks in the forelimbs; stage 4, clonic convulsions in the forelimbs with rearing; and stage 5, generalized clonic convulsions associated with loss balance. After all SRS had been reviewed by both reviewers independently, a final consensus was reached for each SRS through discussion of those in which their reviews were different. Seizures that occurred within a week was not considered as SRS. Therefore, the time points of the earliest and latest seizures were 8 days and 56 days, respectively. The duration of SRS is the time that SRS lasted, and the frequency of SRS is the number of the occurrence of SRS per day. The criteria for seizures in EEG was de-

defined as distinctive activities from the baseline, often repetitive epileptiform and/or rhythmic discharges evolving for at least 2~3 sec accompanied by behavioral changes on video-monitoring [13,14]. An examples of ictal EEG activity during a seizure was illustrated in Fig. 2A.

**Magnetic resonance imaging (MRI) and positron emission tomography (PET)**

All neuroimaging procedures were performed under anesthesia with a mixture of ketamine (80 mg/kg) and xylene (5.2 mg/kg). Structural brain images were studied by 7.0 T MRI scanners (Magnetom 7T, Siemens, Enlargen, Germany). For the MRI, Spin Echo sequence was acquired using the imaging parameters with repetition time (TR)=6000 ms, echo time (TE)=60 ms, voxel size=0.22×0.22×0.4 mm, pixel band width (BW)=80 Hz/pixel, and



**Fig. 2.** Severities of seizures by durations and daily frequency at different time points. (A) An example of seizure activity in EEG recording. (B) Seizure durations for each day for 30 days since the pilocarpine injection (day 0). (C) Seizure durations at acute, latent and chronic phases after the pilocarpine injection. (D) Daily seizure frequency for each day for 30 days since the pilocarpine injection (day 0). (E) Daily seizure frequency at acute, latent and chronic phases after the pilocarpine injection. Stage 1 to 5: symptom severity of seizures based on the revised Racine Classification.

flip angle (FA)=90°. The total acquisition time (TA) was 14 min and 21 sec.

Each animal was deprived of food for 12 hours, and accumulated [<sup>18</sup>F]FDG-6-PO<sub>4</sub> metabolic imaging was performed after administration of [<sup>18</sup>F]FDG (500 µCi/100 g body weights) using a Focus 120 Micro PET system (Concorde Microsystems, Knoxville, TN, USA) with 1.18 mm×1.13 mm matrix size, and 1.3 mm full width at half maximum (FWHM) resolution. Both MRI and PET were obtained at 7 time points including the baseline, 3 hours, 1, 3, 7 days, 4 and 8 weeks following the initial insult (Fig. 1). The repeated exposures to MRI and PET would have some changes in the imaging conditions in these animals, which were minimized by the standard procedures as described previously [9].

### **MRI-PET co-registration**

For MRI and PET coregistration, the brain regions of the animal micro PET image were manually extracted for statistical analysis first. PET images were reconstructed using the ordered subset expectation maximization (OSEM) algorithm. Nominal pixel size was 0.43×0.43×0.81 mm<sup>3</sup>, and then coregistered to rat brain template using statistical parametrical mapping (SPM8, Wellcome Trust Centre for Neuroimaging, <http://www.fil.ion.ucl.ac.uk/spm>). Second, it was normalized into the MRI template for accurate anatomical information in stereotaxic space. Third, all of the brain images were normalized the [<sup>18</sup>F]FDG rat brain template. The individual normalized images were then smoothed with a 2-mm FWHM isotropic Gaussian kernel. Voxel-based statistical analyses were performed using SPM8 toolbox implanted in MATLAB. Finally, T-value maps were created superimposed on transverse planed of the MRI template to identify voxels of statistical significance [15, 16].

### **Correlation between neuroimaging and seizure severities**

Seizure severities were determined by the duration and frequency of SRS for each day after pilocarpine injection were quantified during 8 weeks. The duration of SRS is the time that SRS lasted, and the frequency of SRS is the number of the occurrence of SRS per day. The total duration and frequency of seizures within each phase (acute, latent and chronic phases after SE) were divided by the number of days to calculate average daily seizure duration and frequency.

For statistical analysis, correlation between duration and frequency of class 3 to 5 SRS at chronic phase and changes in MRI and FDG-PET acquired at each time point was examined. The seizure severities estimated by averaged duration and frequency of SRS was calculated by averaging the total durations and frequency of class 3 to 5 SRS during chronic phase, which were examined

for correlation with intensity of each voxel from the brain imaging scanned at each time point, using the 3-dimensional mapping of Pearson correlation coefficients, constructed to represent the brain areas that were significantly correlated with seizure duration or frequency (p-value<0.05 with FWE correction for multiple comparison). Co-registration of raw images and statistical images of Pearson correlation was created by MRlcro software.

## **RESULTS**

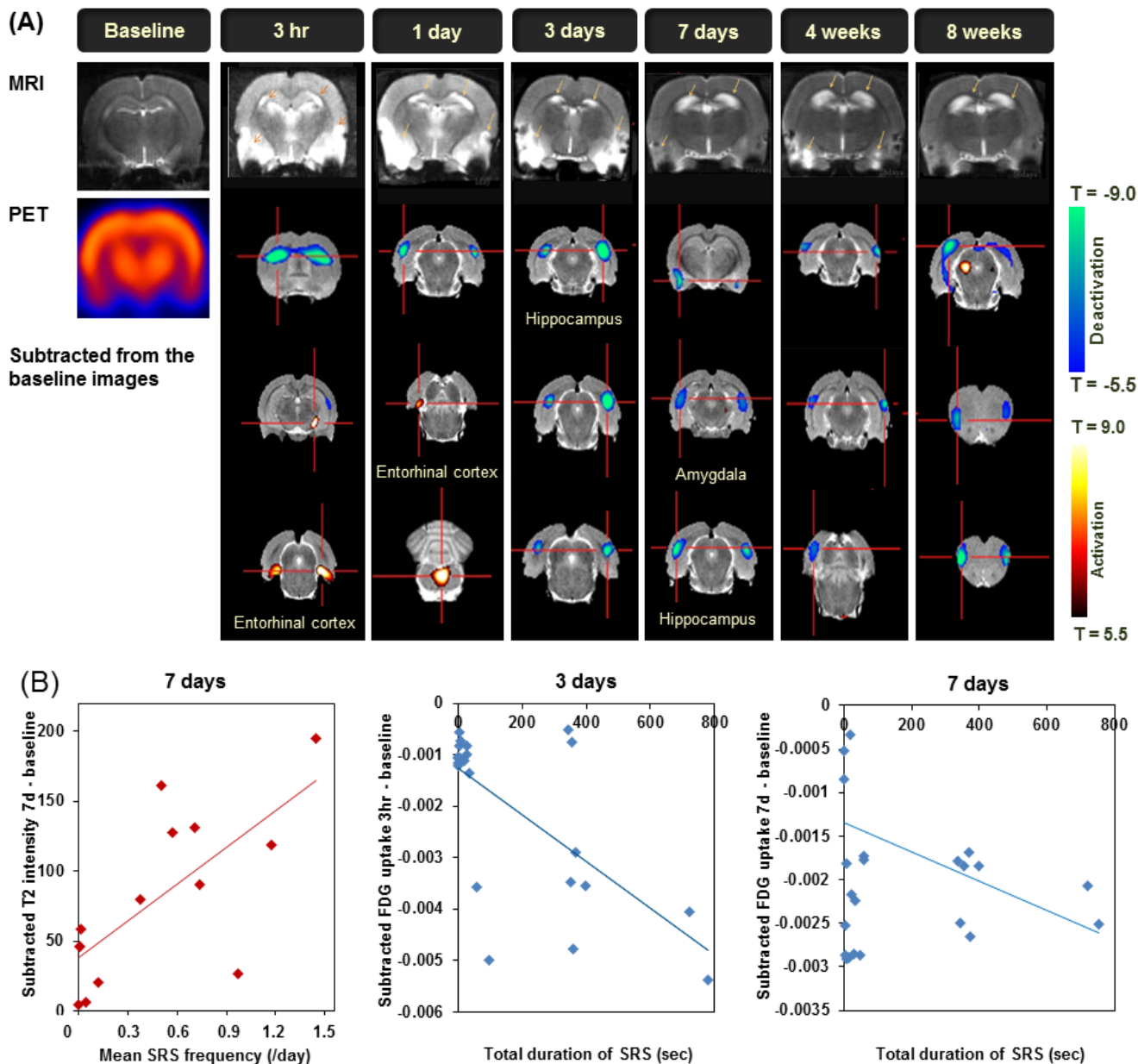
### **Induction of SE by pilocarpine and development of SRS after SE**

Continuous video-EEG monitoring data were obtained from all experimental animals after pilocarpine injection. We assessed daily seizure counts and duration during the entire study period (Fig. 2B~E). The initial SE was induced 4.9±2.5 min after pilocarpine injection, and the latent period for the appearance of the first SRS was 8.0±1.3 day after SE. At acute phase, mean seizure count per day were 1.3, 3.1, and 2.8 for class 3, 4, 5 SRS, and mean seizure durations per day were 42.4 sec, 202.1 sec, and 195.9 sec for class 3, 4, 5, respectively. At chronic phase, mean seizure counts per day were 0.4, 0.3, and 0.1 for class 3, 4, 5 SRS, and mean seizure durations per day were 27.4 sec, 26.6 sec, and 14.6 sec for class 3, 4, 5, respectively. Seizures within 3 days were considered to be caused by the initial insult closely related to pilocarpine injection, and seizures that occurred 8 days after the initial insult only were considered as SRS.

### **Neuroimaging findings**

We also examined time course of changes in T<sub>2</sub> signal intensity on follow-up MR images, from 3 hours to 8 weeks (7 time points), in all pilocarpine-induced epileptic rats following SE. We found that 7T MRI mainly showed increased T<sub>2</sub>WI signal intensities in bilateral hippocampi, piriform/entorhinal cortices (Fig. 3A, upper row). The hippocampal T<sub>2</sub> signal intensity was slightly increased at 3 hours after the initial insult and became more focal and prominent at 1 day and 3 days after the insult. This T<sub>2</sub> signal further increased at 7 days and persisted with atrophic changes throughout the chronic phase at 4 and 8 weeks. Significant T<sub>2</sub> increase was seen in the thalamus at 1 day, but resolved by 7 days. In piriform/entorhinal cortices and amygdala, a markedly increased T<sub>2</sub> signal appeared at 1 day and 3 days, and significantly decreased at 7 days. T<sub>2</sub> signal intensity increased again in piriform cortex and amygdala at the chronic phase (4 and 8 weeks after the initial insult).

Lower rows of Fig. 3A illustrated subtraction FDG-PET glucose metabolism at each time point to the baseline PET image and coregistered with MRI to yield accurate anatomical localization.



**Fig. 3.** Correlation between neuroimaging changes and seizure severities. (A) In addition to the MRI changes (upper row), FDG-PET glucose metabolism (lower rows) mainly decreased especially in bilateral hippocampi, amygdala, part of subcortical and frontal areas throughout the entire stages, although glucose metabolism focally increased in entorhinal cortex, cerebellum bilaterally at acute stages (3 hours and 1 day after the initial insult, respectively), and right hypothalamus at chronic stage (8 weeks). (B) Mean daily seizure frequency during the chronic stage was positively correlated MRI T2 signal changes in bilateral hippocampal areas at 7 days after the initial insult (latent phase, left). Longer seizure duration was correlated with more decreased glucose metabolism in bilateral hippocampal areas at 3 and 7 days (latent and chronic phases, middle and right, respectively). All of these findings were statistically significant with corrected p-value < 0.05.

FDG uptake revealed mostly decreases in bilateral hippocampi, amygdala, and part of subcortical or frontal areas throughout acute, subacute, and chronic stages. Although the main findings of PET subtraction were decreased glucose metabolism, some areas showed focal increase of metabolism; in bilateral entorhinal, cerebellum at acute stages (3 hours, 1 day, respectively), and right

hypothalamus at chronic stage (8 weeks).

**Correlation between neuroimaging changes and seizure severities**

Neuroimaging changes in MRI and PET at each time point were investigated whether they have significant correlation with dura-

tion and frequency of SRS during chronic phase. Fig. 3B showed relationship between MRI/PET changes and seizure severities such as mean daily frequency and/or total duration after SE, namely SRS. Mean daily frequency of SRS was positively correlated MRI T2 signal in bilateral hippocampal areas at subacute stage of 7 days (in Fig. 3B, left,  $r=0.606$ , corrected  $p$ -value $<0.05$ ). Total seizure duration was negatively correlated with FDG-PET glucose metabolism in both hippocampal areas at subacute to chronic stages of 3 days ( $r=-0.589$ , corrected  $p$ -value $<0.05$ ; Fig. 3B, middle) and 7 days ( $r=-0.764$ , corrected  $p$ -value $<0.05$ ; Fig. 3B, right).

## DISCUSSION

In the present study we have investigated the relationship between 7T MRI/FDG-PET neuroimaging abnormalities and seizure severities at various time points. We observed a significant correlation between higher MRI T2 signal intensities in hippocampus and amygdala during the latent phase (3 days) and more frequent SRS with class 3 to 5 modified Racine classification during the chronic phase for 8 weeks. In addition, more reduced FDG-PET glucose metabolism in these areas during the latent and chronic phases (3 and 7 days) was correlated with longer duration of SRS during the chronic phase for 8 weeks.

Our T2 MRI findings are consistent with those from the previous studies in pilocarpine-induced SE epilepsy model [17, 18]. Previous follow-up MRI studies have shown temporal changes in T2 signal in animal brain that underwent SE induced by pilocarpine [19, 20] and kainic acid [16, 21, 22].

We further assessed the relationship between T2 signal intensity and class 3 to 5 SRS frequency/duration. More frequent SRS were correlated with higher T<sub>2</sub> signal intensity in both hippocampi and amygdala during the latent phase (7 days after the initial insult), indicating that structural damage during latent phase in pilocarpine rat model contribute to the development of SRS and the severity of epilepsy.

Similarly, previous studies using FDG-PET reported decrease in glucose metabolism in the epileptic rat brain following pilocarpine [18, 23] or kainic acid [16, 22] administration. A widespread hypometabolism in the early stage after SE in pilocarpine rat model has been reported [18, 23, 24]. One study showed glucose hypometabolism throughout rat brain, mostly in hippocampus, entorhinal cortex, and thalamus bilaterally at 3 days after the initial insult induced by lithium-pilocarpine. In the kainic acid-induced SE model, FDG uptake decreased globally in the entire cerebrum at 24 h, and this decrease was persistent for 6 weeks [16, 22]. Another study reported that PET hypometabolism was correlated with the neuronal cell loss during the latent phase while and correlated with

astrogliosis in the chronic phase [9].

The longer duration of class 3 to 5 SRS in chronic phase was correlated with decreased glucose metabolism in both hippocampi and amygdala at the latent phases (3 and 7 days after the initial insult). In our results, the prominent decrease in glucose metabolism in the entorhinal cortex in the latent phase (14 days after the initial insult) was correlated with the more frequent SRS and correlated with shorter duration of the latent phase. However, we did not observe significant correlation between glucose hypometabolism in entorhinal cortex at all stages after SE and SRS frequency at chronic phase.

Although our study was done in animal models, these findings can extend to human epilepsy and may have important clinical impacts. Significant correlation between duration of epilepsy and hippocampal glucose hypometabolism was observed in epilepsy patients [25, 26]. Longer epilepsy duration was correlated with more decreased glucose metabolism in the parahippocampal gyrus, hippocampus, and inferior temporal gyrus in epileptic brain [25]. A relationship between longer epilepsy duration and greater hypometabolism in hippocampus was observed in 91 TLE patients, suggesting epilepsy as a progressive disease [26]. In fact, the prognosis for seizure control and the severity of memory impairment can be predicted by the degree and the extent of temporal hypometabolism in temporal lobe epilepsy patients. Our study indicates that structural and functional abnormalities in hippocampus and amygdala during the early process of epileptogenesis, especially the latent phase, may contribute to the epileptogenic process and also to the severity of epileptic seizures. In addition, these findings can be considered as an early neuroimaging biomarker of epileptogenesis, which would help investigate anti-epileptogenic effects of various treatment modalities.

In summary, this study investigated the detailed relationship between neuroimaging, immunochemistry, and behavioral seizures in pilocarpine-induced rat epilepsy model for 8 weeks. We observed a significant correlation between more severe MRI T2 signal changes in bilateral hippocampal and amygdala regions during the latent phase and longer SRS duration during the chronic phase. In addition, more decreased FDG-PET glucose metabolism in these areas during the acute/latent phases was correlated with longer duration of SRS during the chronic phase. These findings indicate that structural and functional abnormalities in both hippocampus and amygdala during the early process of epileptogenesis, especially the latent phase following pilocarpine-induced SE, may contribute to the development of spontaneous seizures and the severity of epilepsy. These findings can be considered as an early neuroimaging biomarker of epileptogenesis, which will be helpful in future experimental animal studies, for instance, investigating

anti-epileptogenic or neuroprotective effects of various treatment modalities.

#### ACKNOWLEDGEMENTS

This work was supported by grants of the Basic Science Research Program through the National Research Foundation of Korea (NRF) funded by the Ministry of Education, Science and Technology (2014R1A2A1A11052103 and 2017R1A2A2A05069647), and the Korea Health Technology R&D Project through the Korea Health Industry Development Institute (KHIDI), funded by the Ministry of Health & Welfare (HI14C1989) to H. W. Lee.

#### REFERENCES

- Curia G, Longo D, Biagini G, Jones RS, Avoli M (2008) The pilocarpine model of temporal lobe epilepsy. *J Neurosci Methods* 172:143-157.
- Turski WA, Cavalheiro EA, Schwarz M, Czuczwar SJ, Kleinrok Z, Turski L (1983) Limbic seizures produced by pilocarpine in rats: behavioural, electroencephalographic and neuropathological study. *Behav Brain Res* 9:315-335.
- Dedeurwaerdere S, Jupp B, O'Brien TJ (2007) Positron Emission Tomography in basic epilepsy research: a view of the epileptic brain. *Epilepsia* 48 Suppl 4:56-64.
- Duconseille E, Woerly S, Kelche C, Will B, Cassel JC (1998) Polymeric hydrogels placed into a fimbria-fornix lesion cavity promote fiber (re)growth: a morphological study in the rat. *Restor Neurol Neurosci* 13:193-203.
- Blackshire JL, Sathish S, Duncan BD, Millard M (2002) Real-time, frequency-translated holographic visualization of surface acoustic wave interactions with surface-breaking defects. *Opt Lett* 27:1025-1027.
- Duncan JS (2002) Neuroimaging methods to evaluate the etiology and consequences of epilepsy. *Epilepsy Res* 50:131-140.
- Doherty CP, Cole AJ, Grant PE, Fischman A, Dooling E, Hoch DB, White TH, Cosgrove GR (2004) Multimodal longitudinal imaging of focal status epilepticus. *Can J Neurol Sci* 31:276-281.
- Scott RC, King MD, Gadian DG, Neville BG, Connelly A (2003) Hippocampal abnormalities after prolonged febrile convulsion: a longitudinal MRI study. *Brain* 126:2551-2557.
- Zhang L, Guo Y, Hu H, Wang J, Liu Z, Gao F (2015) FDG-PET and NeuN-GFAP immunohistochemistry of hippocampus at different phases of the pilocarpine model of temporal lobe epilepsy. *Int J Med Sci* 12:288-294.
- Cavalheiro EA, Leite JP, Bortolotto ZA, Turski WA, Ikonomidou C, Turski L (1991) Long-term effects of pilocarpine in rats: structural damage of the brain triggers kindling and spontaneous recurrent seizures. *Epilepsia* 32:778-782.
- Hamani C, Mello LE (2002) Spontaneous recurrent seizures and neuropathology in the chronic phase of the pilocarpine and picrotoxin model epilepsy. *Neurol Res* 24:199-209.
- Racine RJ (1972) Modification of seizure activity by electrical stimulation. II. Motor seizure. *Electroencephalogr Clin Neurophysiol* 32:281-294.
- D'Ambrosio R, Miller JW (2010) What is an epileptic seizure? Unifying definitions in clinical practice and animal research to develop novel treatments. *Epilepsy Curr* 10:61-66.
- Fisher RS, Scharfman HE, deCurtis M (2014) How can we identify ictal and interictal abnormal activity? *Adv Exp Med Biol* 813:3-23.
- Hayakawa N, Uemura K, Ishiwata K, Shimada Y, Ogi N, Nagaoka T, Toyama H, Oda K, Tanaka A, Endo K, Senda M (2000) A PET-MRI registration technique for PET studies of the rat brain. *Nucl Med Biol* 27:121-125.
- Leroy C, Roch C, Koning E, Namer IJ, Nehlig A (2003) In the lithium-pilocarpine model of epilepsy, brain lesions are not linked to changes in blood-brain barrier permeability: an autoradiographic study in adult and developing rats. *Exp Neurol* 182:361-372.
- Goffin K, Van Paesschen W, Dupont P, Van Laere K (2009) Longitudinal microPET imaging of brain glucose metabolism in rat lithium-pilocarpine model of epilepsy. *Exp Neurol* 217:205-209.
- Roch C, Leroy C, Nehlig A, Namer IJ (2002) Magnetic resonance imaging in the study of the lithium-pilocarpine model of temporal lobe epilepsy in adult rats. *Epilepsia* 43:325-335.
- André V, Dubé C, François J, Leroy C, Rigoulot MA, Roch C, Namer IJ, Nehlig A (2007) Pathogenesis and pharmacology of epilepsy in the lithium-pilocarpine model. *Epilepsia* 48 Suppl 5:41-47.
- Bouillere V, Valenti MP, Hirsch E, Semah F, Namer IJ (2002) Correlation between PET and SISCOM in temporal lobe epilepsy. *J Nucl Med* 43:991-998.
- Jupp B, O'Brien TJ (2007) Application of coregistration for imaging of animal models of epilepsy. *Epilepsia* 48 Suppl 4:82-89.
- Jupp B, Williams J, Binns D, Hicks RJ, Cardamone L, Jones N, Rees S, O'Brien TJ (2012) Hypometabolism precedes limbic atrophy and spontaneous recurrent seizures in a rat model of TLE. *Epilepsia* 53:1233-1244.
- Guo Y, Gao F, Wang S, Ding Y, Zhang H, Wang J, Ding MP (2009) In vivo mapping of temporospatial changes in glucose



- utilization in rat brain during epileptogenesis: an 18F-fluorodeoxyglucose-small animal positron emission tomography study. *Neuroscience* 162:972-979.
24. Lee EM, Park GY, Im KC, Kim ST, Woo CW, Chung JH, Kim KS, Kim JS, Shon YM, Kim YI, Kang JK (2012) Changes in glucose metabolism and metabolites during the epileptogenic process in the lithium-pilocarpine model of epilepsy. *Epilepsia* 53:860-869.
  25. Akman CI, Ichise M, Olsavsky A, Tikofsky RS, Van Heertum RL, Gilliam F (2010) Epilepsy duration impacts on brain glucose metabolism in temporal lobe epilepsy: results of voxel-based mapping. *Epilepsy Behav* 17:373-380.
  26. Theodore WH, Kelley K, Toczek MT, Gaillard WD (2004) Epilepsy duration, febrile seizures, and cerebral glucose metabolism. *Epilepsia* 45:276-279.