

UCSF

UC San Francisco Previously Published Works

Title

Delayed Sigmoid Colon Erosion by Artificial Urinary Sphincter Tubing

Permalink

<https://escholarship.org/uc/item/62q6h4z7>

Authors

Shieh, Christine
Shaw, Nathan M
Decker, Hannah
et al.

Publication Date

2022-08-01

DOI

10.1016/j.urology.2022.04.035

Peer reviewed



Delayed Sigmoid Colon Erosion by Artificial Urinary Sphincter Tubing

Christine Shieh, Nathan M. Shaw, Hannah Decker, Ian Soriano, and Benjamin N. Breyer

A 65-year-old male presents with groin discomfort from a left inguinal hernia. He has a history of prostate cancer status—post radiation therapy and prostatic stenosis treated with urethroplasty. He subsequently developed severe urinary incontinence and underwent artificial urinary sphincter (AUS) placement in 2016. The AUS was replaced in June 2020 due to mechanical failure; he has since experienced no issues and maintained excellent continence.

At this visit, the patient reports that the hernia has been present for several months but has gradually increased in size. He complains of increased pain and difficulty walking. He also reports scrotal swelling over the past 5 days, making it difficult to use his AUS.

Laboratory workup in the ED is unremarkable. He shows no systemic signs of illness or obstructive symptoms. Physical exam reveals a nonreducible inguinal hernia. Computed tomography images obtained are shown below (Fig. 1).

What complication of AUS placement is most likely shown in the highlighted areas given his current presentation?

- A) device infection
- B) urethral erosion by urethral cuff
- C) bowel erosion by AUS tubing
- D) intraoperative injury

Highlighted areas show C) bowel erosion by AUS tubing.

CT images revealed a large incarcerated left inguinal hernia containing loops of nondilated descending and sigmoid colon, with imaging concerning for AUS tubing within the hernia sac (Fig. 1). The patient underwent hernia repair with synthetic mesh. Intraoperatively, there was AUS tubing visualized within the lumen of the colon in the hernia (Fig. 2). The hernia was unable to be reduced due to being held at two distinct adhesions, revealed to be

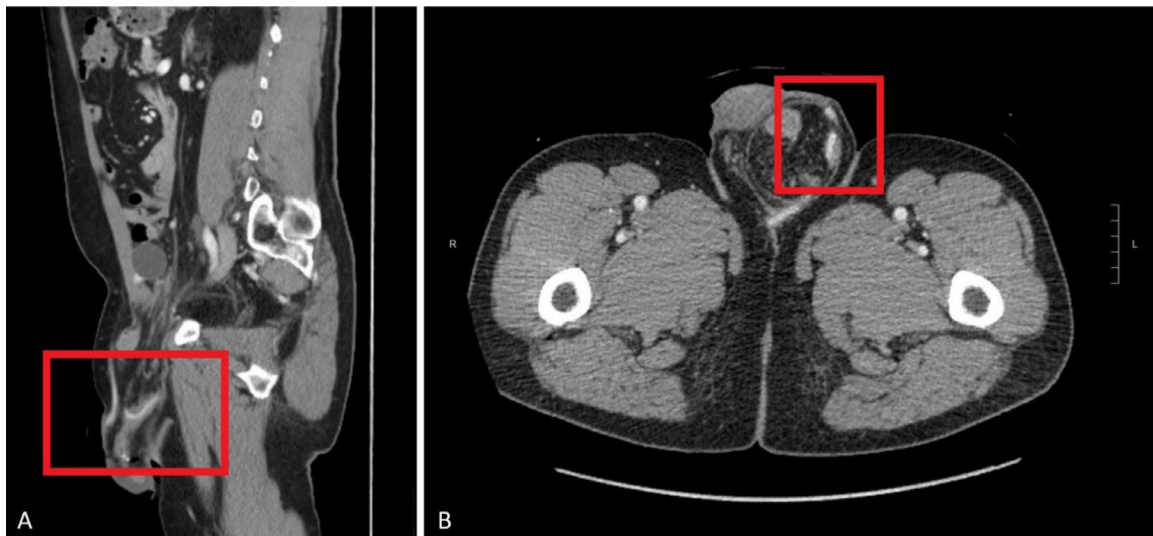


Figure 1. CT images of left inguinal hernia; (A) sagittal plane; (B) coronal plane.

Financial Disclosure: The authors declare that they have no relevant financial interests.

From the School of Medicine, Virginia Commonwealth University, Richmond, VA; the Department of Urology, University of California San Francisco, San Francisco, CA; the Department of Surgery, University of California San Francisco, San Francisco, CA; and the Department of Biostatistics and Epidemiology, University of California San Francisco, San Francisco, CA

Address correspondence to Benjamin N. Breyer M.D., M.A.S., F.A.C.S., University of California San Francisco, Zuckerberg San Francisco General Hospital and Trauma Center, 1001 Potrero Suite 3A, San Francisco, CA 94110. E-mail: Benjamin.Breyer@ucsf.edu

Submitted: April 14, 2022, accepted (with revisions): April 27, 2022

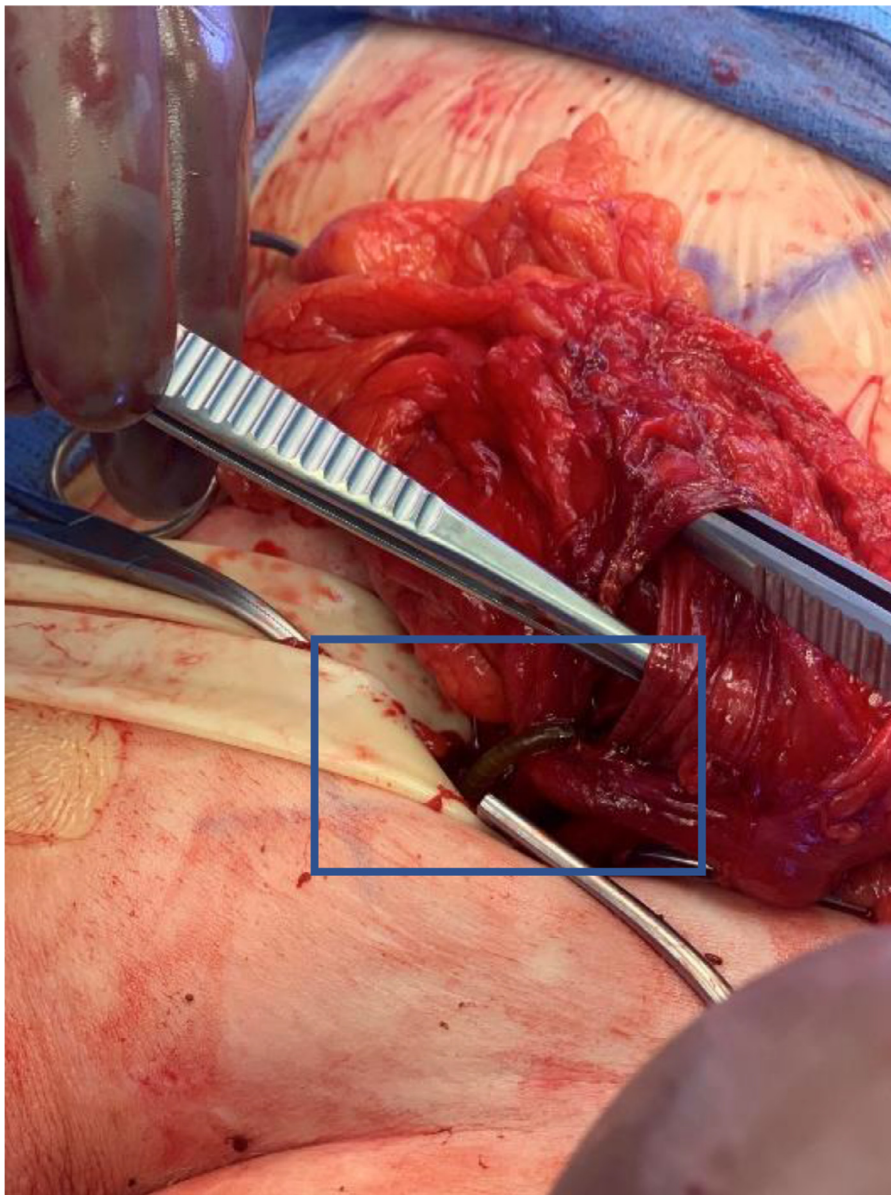


Figure 2. Intraoperative photo of AUS tubing protruding through the inguinal ring.

AUS tubing entering and exiting the colon. Ultimately, in addition to hernia repair, the patient underwent bowel resection and AUS explant.

The most common complications of AUS placement include infection, device malfunction, and urethral erosion.¹ Erosion of bowel by AUS tubing is exceedingly rare. To our knowledge there has only been one previous report of AUS tubing erosion into the bowel.² The most striking feature of this case is the delay in presentation (2 years) during which time the patient had a working device and no symptoms. The discovery of bowel erosion by AUS

tubing was only made incidentally during workup for symptoms secondary to his hernia; it is unclear when this erosion occurred. We present this case to highlight diagnostic and intra-operative imaging for this rare complication.

References

1. Khouri RK, Ortiz NM, Dropkin BM, et al. Artificial urinary sphincter complications: risk factors, workup, and clinical approach. *Curr Urol Rep.* 2021;22:30.
2. Yuan X, Mudge BJ, Raezer DM. Small intestine erosion by artificial urinary sphincter reservoir tubing. *J Urol.* 2004;172:1363.