

UC Davis
Dermatology Online Journal

Title

Revisiting the Rintala advancement flap for nasal tip reconstruction

Permalink

<https://escholarship.org/uc/item/5dv0s7zx>

Journal

Dermatology Online Journal, 26(8)

Authors

Girijala, Raghavendra L
Ramamurthi, Aishwarya
Walker, Gregory D
et al.

Publication Date

2020

DOI

10.5070/D3268049898

Copyright Information

Copyright 2020 by the author(s). This work is made available under the terms of a Creative Commons Attribution-NonCommercial-NoDerivatives License, available at <https://creativecommons.org/licenses/by-nc-nd/4.0/>

Peer reviewed

Revisiting the Rintala advancement flap for nasal tip reconstruction

Raghavendra L Girijala¹ MD, Aishwarya Ramamurthi² BS, Gregory D Walker³ MD MBA, Chad Housewright³ MD

Affiliations: ¹Department of Internal Medicine, Baylor University Medical Center, Dallas, Texas, USA, ²University of Texas Southwestern Medical School, Dallas, Texas, USA, ³Department of Dermatology, Baylor Scott & White Medical Center, Temple, Texas, USA

Corresponding Author: Raghavendra Girijala, 150 Sabine Street, Apartment 440, Houston, TX 77007, Tel: 847-387-7519, Email: rgirijala@gmail.com

Abstract

The approach to nasal reconstruction is based on the nature of the defect and the donor tissue. The Rintala flap, first described by Rintala and Asko-Slejavaara, is a surgical technique used to close midline nasal defects. It is a simple, one-stage procedure and is most effective for defects ranging from 1.5 to 2.5 centimeters. In addition, the Rintala flap is an excellent tissue match and maintains the natural contour of the nose. Other flaps employed in nasal defect closure include the paramedian forehead flap and the Rieger flap. The authors discuss the Rintala flap technique and utility with comparison to alternative flaps used for nasal reconstruction.

Keywords: flap, Mohs micrographic surgery, nasal reconstruction, Rintala

Introduction

Given the complexity of the nasal anatomy and aesthetic importance of the nose, reconstruction of nasal defects in Mohs micrographic surgery requires consideration of the defect type, location, and size. Nasal defects over two centimeters are often repaired with the paramedian forehead flap, whereas closures under 1.5 centimeters employ primary closure, local transposition flaps, or rotational flaps [1]. For defects ranging from 1.5 to 2.5 centimeters in the nasal tip, the Rintala advancement flap, first described by Rintala and

Asko-Slejavaara in 1969, can be a tool in the Mohs surgeon's armamentarium [2].

The approach to nasal reconstruction is predicated on subunit analysis, which includes the ala, columella, dorsum, sidewalls, soft tissue triangles, and tip [1]. From an aesthetic viewpoint, repair within subunit boundaries generates more inconspicuous scarring owing to concealment within the light-shadow interface [1]. The nature of the donor tissue (including tissue color and texture), vascular supply afforded by the closure technique, and defect size must also be considered when utilizing nasal flaps.

The Rintala flap can be confidently used in defects ranging from 1.5 to 2.5 centimeters but has been effective in cases with closures up to four centimeters; this is predicated on the degree of laxity proximal to the defect [3]. The planning and execution of the flap is shown in **Figure 1**. Customarily, it is best to adhere to a 3:1 length to width ratio when planning advancement flaps to allow for adequate perfusion. However, because of the robust vascular supply in the nasal dorsum and root, up to a 5:1 ratio can be used for the Rintala flap.

Closure of the surgical defect is initiated with vertically oriented incisions made on both sides of the nasal dorsum, at the junction of the nasal sidewall and nasal dorsum, to utilize the tissue reservoir in the glabella. Said vertical incisions can be positioned at the width of the defect. If the defect is

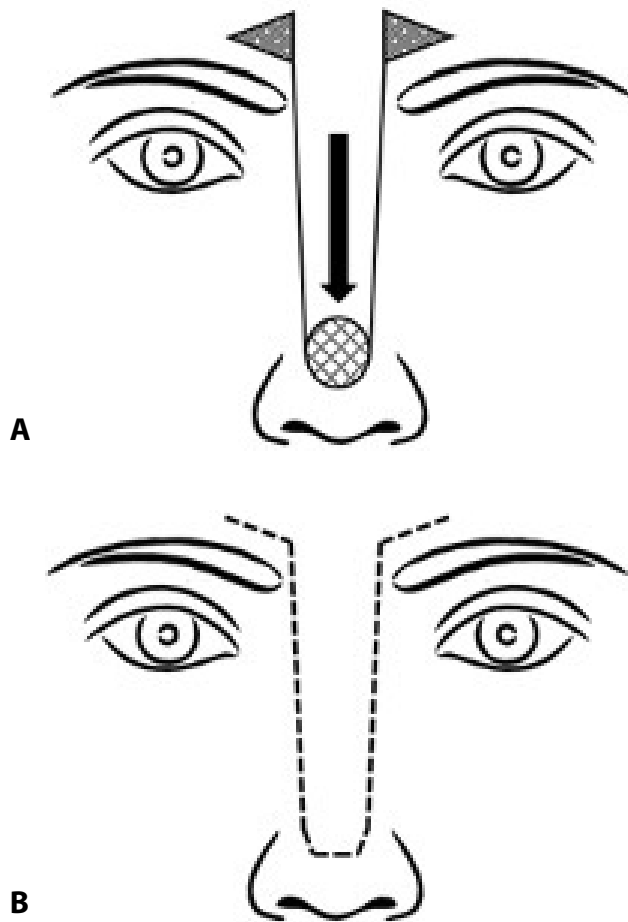


Figure 1. **A)** Surgical planning with the Rintala flap for reconstruction of the nose. **B)** Depiction of the scar line after closure using the Rintala flap.

narrower, they should be tapered laterally to the junction of the nasal sidewall and nasal dorsum.

Subsequently, the flap is elevated at the perichondrium or periosteum, depending on the area of the nasal tip defect. Undermining is conducted proximally, with most Rintala flaps finding adequate tissue reservoir at the level of the nasal root. However, if the undermining extends to the glabella, a transition to the adipose plane is recommended to avoid the supratrochlear arteries. If additional laxity is required, Burow triangles can be created in the forehead rhytides to avoid tissue redundancy and allow for minimal tension as the flap drapes inferiorly into the primary defect.

Notably, the Rintala flap is most efficacious in the closure of midline nasal lesions by using superiorly-based tissue in the glabella for advancement to the nasal tip. As a result, minimal scar formation occurs

owing to post-operative suture lines occurring along the brow configuration [1]. Furthermore, the Rintala flap is a single stage procedure, is technically easy to perform, and has an excellent tissue match with respect to color and texture [3].

However, this is not to imply that the Rintala flap is without complications, even when used in the appropriate subset of patients. Because of the random pattern of blood supply in the subdermal plexus in the Rintala flap, the narrow pedicle prepared in the forehead determines the risk of ischemia at the flap's distal end and subsequently, flap necrosis [3]. Furthermore, a shortened flap and undue tension can result in nasal shortening and tip elevation [3]. Transient sensory disturbance of the forehead has also been reported [1]. Nevertheless, appropriate surgical planning can limit the risk of complications. In addition, the technique maximizes aesthetic outcomes by adhering to the natural contour of the nose.

Discussion

Other flaps are often employed in nasal closures. Large nasal defects (two centimeters or more) can be closed with the paramedian forehead flap, an interpolated axial flap based on the supratrochlear artery [4]. Notable advantages of the paramedian forehead flap are excellent tissue match (in both color and texture) and rich vascular supply from the supratrochlear artery. In addition, collateral arteries such as the dorsal nasal branch of the angular artery and the supraorbital artery supply the tissue, resulting in a durable and reliable outcome [4]. However, this procedure can come at a significant cost for the patient in the form of increased numbers of visits and missed work associated with its staged nature, as well as higher financial cost and possible psychological burden.

Alternatively, the Rieger flap has been demonstrated as a reliable reconstructive option in nasal tip and nasal dorsum defects that range from 1.0 to 1.5 centimeters [5]. This modified rotational flap utilizes the tissue reservoir of the superior nasal dorsum and/or nasal root as it recruits from tissue laxity in the horizontal and vertical vectors; the latter is due to the

flap's distal rotational aspect [5]. However, given this rotational component, the Rieger flap is limited by the pivotal restraint of the rotating base. In contrast, the Rintala flap possesses no such limitation because it is a modified unilateral advancement. Furthermore, not all patients have the horizontal laxity required for Rieger flaps. In these cases, it may be more useful to recruit any vertically oriented laxity from the tissue reservoir of the nasal dorsum, nasal root, and or glabella, which can be conducted with the Rintala flap.

References

1. Motamedi KK, Amin SH, DeJoseph LM, Silver WE. Aesthetic modification to the rintala flap: a case series. *Aesthetic Plast Surg.* 2014;38:395-398. [PMID: 24610113].
2. Rintala AE, Asko-Seljavaara S. Reconstruction of midline skin defects of the nose. *Scand J Plast Reconstr Surg.* 1969;3:105-108. [PMID: 4924039].
3. Onishi K, Okada E, Hirata A. The Rintala flap: a versatile procedure for nasal reconstruction. *Am J Otolaryngol.* 2014;35:577-581. [PMID: 25053186].
4. Smart RJ, Yeoh MS, Kim DD. Paramedian forehead flap. *Oral Maxillofac Surg Clin North Am.* 2014;26:401-410. [PMID: 24973992].
5. Redondo P, Bernad I, Moreno E, Ivars M. Elongated Dorsal Nasal Flap to Reconstruct Large Defects of the Nose. *Dermatol Surg.* 2017;43:1036-1041. [PMID: 28375969].

Conclusion

There are several excellent options for surgical closure of nasal defects. We hope that this discussion sheds light on the Rintala flap as an alternative technique for the repair of 1.5 to 2.5 centimeter midline nasal tip defects.

Potential conflicts of interest

The authors declare no conflicts of interests.