

UCSF

UC San Francisco Previously Published Works

Title

Delayed Acute Granulomatous Anterior Uveitis after Inadvertent Intraocular Injection of Tattoo Ink from a Scleral Tattoo Procedure

Permalink

<https://escholarship.org/uc/item/3wp049g4>

Journal

Ocular Immunology and Inflammation, 29(5)

ISSN

0927-3948

Authors

Haq, Zeeshan
Pasricha, Neel
Bever, Greg
[et al.](#)

Publication Date

2021-07-04

DOI

10.1080/09273948.2020.1784439

Peer reviewed



Published in final edited form as:

Ocul Immunol Inflamm. 2021 July 04; 29(5): 1029–1031. doi:10.1080/09273948.2020.1784439.

Delayed Acute Granulomatous Anterior Uveitis after Inadvertent Intraocular Injection of Tattoo Ink from a Scleral Tattoo Procedure

Zeeshan Haq, MD¹, Neel Pasricha, MD¹, Greg Bever, MD¹, Gerami Seitzman, MD¹, Jay M. Stewart, MD¹

¹Department of Ophthalmology, University of California – San Francisco, San Francisco, CA

Abstract

Purpose—To improve awareness of delayed onset uveitis in patients with a history of intraocular tattoo ink injection.

Results—A 47-year-old man underwent a scleral tattoo procedure during which there was inadvertent intraocular injection of tattoo ink into his right eye. He subsequently developed endophthalmitis, retinal detachment, and retinal necrosis. He was treated with intravitreal and oral antibiotics and underwent vitreoretinal surgical intervention. A vitreous specimen was obtained and demonstrated significantly elevated levels of several heavy metals. One month later, he developed an acute granulomatous anterior uveitis in the same eye that was managed with a combination of topical and perioperative intravitreal, intravenous, and oral corticosteroids.

Conclusion—This case highlights the importance of monitoring patients with a history of intraocular tattoo ink injection for delayed onset uveitis in addition to retinal toxicity.

Background

Scleral tattooing is a new body modification technique in which tattoo ink is injected into the subconjunctival space in order to color the sclera. According to data from Google Trends®, interest regarding this procedure has increased severalfold worldwide since its inception in the mid-2000s. However, it is performed by artists with no professional medical training or microsurgical equipment and, as such, can be associated with significant complications. Herein, we report a case of acute granulomatous anterior uveitis 1 month after inadvertent intraocular injection of tattoo ink from a scleral tattoo procedure.

Case Presentation

A 47-year-old man presented to the emergency room with bilateral eye pain and decreased vision in his right eye. Two days prior, he had undergone a scleral tattoo procedure with the intention of changing the color of his sclerae to blue.

Corresponding Author: Jay Stewart, MD, University of California, San Francisco, Department of Ophthalmology, 10 Koret Way, K301, San Francisco, CA 94143-0730, Tel. (628) 206-3123.

Disclosure of Interest

GS is a consultant with Dompé Pharmaceuticals. The other authors report no conflicts of interest.

His best-corrected visual acuity was 20/150 and 20/20 in his right and left eye, respectively. Confrontation visual field testing revealed a superior defect in his right eye and no abnormalities in his left eye. His intraocular pressure, pupils, and ocular motility were normal. Slit lamp examination showed conjunctival injection and subconjunctival light blue pigmentation in both eyes (Figure, A and B). There was a small hypopyon in the right eye (Figure, A). Dilated fundus examination was limited in the right eye due to dense vitreous debris and was unremarkable in the left eye. B-scan ultrasonography of the right eye demonstrated vitreous opacities, a probable retinal detachment, and retinal thickening in the area just posterior to the blue discoloration of the conjunctiva (Figure, C). These findings were concerning for penetrating trauma from his scleral tattoo procedure complicated by intraocular ink injection, endophthalmitis, and retinal detachment. No direct evidence of scleral trauma was visualized; however, there was a high suspicion that a full-thickness puncture injury had occurred in the inferotemporal quadrant 6 mm from the corneal limbus based on the anterior and posterior segment exam findings.

To evaluate for endophthalmitis, intraocular fluid was sampled and sent for microbial studies. Intravitreal vancomycin and ceftazidime were injected. He was started on oral moxifloxacin, atropine eye drops, and corticosteroid eye drops. In addition, he was given a tetanus booster and emtricitabine-tenofovir and dolutegravir for post-exposure prophylaxis. His eye pain lessened and the hypopyon resolved after 7 days. Bacterial and fungal cultures yielded no growth. HIV and hepatitis serologies were negative.

Due to concern for retinal toxicity from heavy metals found in tattoo ink, he subsequently underwent surgical intervention. The procedure involved a complex vitrectomy, lensectomy, retinectomy with evacuation of subretinal tattoo ink, and retinal detachment repair with silicone oil placement. The vitreous debris was light blue in color (Figure, D). A vitreous sample was sent for mass spectrometry analysis, which revealed high concentrations of multiple heavy metals (Table). His postoperative exam demonstrated trace residual blue debris overlying the retinal surface in the posterior pole and complete retinal reattachment (Figure, E). Serial postoperative optical coherence tomography scans of the macula demonstrated a blunted foveal depression, choroidal thickening, and no evidence of epiretinal membrane formation, cystoid macular edema, or retinal detachment.

Five weeks after surgical intervention, he developed acute right eye pain and photosensitivity. His exam demonstrated an acute granulomatous anterior uveitis (Figure, F). Topical prednisolone acetate 1% was initiated hourly with subsequent improvement in symptoms and examination. The steroid drops were slowly tapered. At the time of his planned silicone oil removal at postoperative month 3, he received a 4 mg intravitreal injection of triamcinolone and 500 mg of intravenous methylprednisolone intraoperatively with a 2-week oral prednisone taper postoperatively. At his last follow up appointment, he denied any eye pain, his vision was correctable to 20/25, his intraocular pressure was 7 mm Hg, and he had no new keratic precipitates or active anterior chamber inflammation.

Discussion

Reports of sight-threatening sequelae from scleral tattoo procedures are mounting in the ophthalmology literature.¹⁻³ Perforating trauma from the tattoo needle can cause damage to intraocular structures and lead to infections of the orbit and/or eye. In addition, deposition of tattoo ink into the trabecular meshwork and subretinal space can lead to ocular hypertension and retinal toxicity, respectively. In our case, the patient suffered a retinal detachment, endophthalmitis, retinal necrosis, and delayed acute granulomatous anterior uveitis. Prompt medical and surgical intervention can optimize outcomes; however, irreversible vision loss is not uncommon and, in some cases, enucleation may be necessary.

Previously published cases of scleral tattoo procedures complicated by ocular injury have included multiple manifestations of intraocular inflammation. Jalil *et al.* reported a case of severe panuveitis characterized by severe anterior uveitis and vitritis in a man who presented 3 days after attempted self-injection.¹ The inflammation improved after urgent lensectomy and vitrectomy, which was performed due to concern for the presence of a copper-containing intraocular foreign body. Duarte *et al.* reported cases of posterior scleritis associated with orbital cellulitis and nodular episcleritis 2 hours and 5 days, respectively, after scleral tattooing.² The former patient experienced resolution of his inflammation after 1 week of systemic antibiotics and 30 days of an oral prednisone regimen; whereas the latter patient was lost to follow up.

Despite successful treatment of endophthalmitis and surgical removal of intraocular tattoo ink, our case uniquely developed a steroid-responsive acute granulomatous anterior uveitis 6 weeks after initial presentation. Given the delayed onset and morphology of this episode of uveitis, we suspect this represents a foreign body-like inflammatory reaction in response to trace amounts of residual intraocular heavy metal. Elemental analysis of the vitreous fluid in our patient, compared to an age-matched normal control, demonstrated high levels of several heavy metals that can cause ocular toxicity. In particular, copper, which was present at a 100-fold higher concentration, is known to elicit a significant inflammatory reaction within the eye if present at sufficient levels. Moreover, cobalt, lead, and mercury have been implicated in optic neuropathy and chorioretinopathy, cataract formation, and photoreceptor toxicity and pseudoexfoliation, respectively.⁴

The entity of tattoo-associated uveitis has gained significant attention since the publication of the largest case series to date in 2014.⁵ In this report, 7 patients with a history of cutaneous tattooing developed simultaneous bilateral uveitis and tattoo elevation with induration. The inflammatory phenotype was either chronic or recurrent non-granulomatous anterior uveitis or chronic granulomatous panuveitis in all cases. Histopathologic analysis of tattoo biopsy specimens in 2 of the cases demonstrated non-caseating granulomatous inflammation in association with dermal tattoo pigment. The authors speculated that processes involved in systemic sarcoidosis and hypersensitivity reactions may have been at play. We cannot rule out the possibility that such mechanisms were involved in our case; however, the likelihood of this shared pathophysiology is low given the unilateral distribution of our patient's uveitis and lack of concomitant cutaneous tattoo induration.

Conclusion

Ophthalmologists should be aware of the unique risks, both short-term and long-term, associated with scleral tattooing and interested patients should be counseled accordingly. In addition to retinal toxicity from heavy metal exposure, patients with a history of inadvertent intraocular injection of tattoo ink should be monitored for intraocular inflammation.

Acknowledgements

The authors acknowledge the assistance of Karen Zeigler, DO, and Deborah French, MD, of the UCSF Department of Pathology, in the mass spectrometry analysis of the vitreous specimens.

Support

This work was supported by the National Eye Institute (1R01EY024004 and EY002162, Core Grant for Vision Research), Research to Prevent Blindness, and That Man May See, Inc.

References

1. Jalil A, Ivanova T, Bonshek R, Patton N. Unique case of eyeball tattooing leading to ocular penetration and intraocular tattoo pigment deposition. *Clin Exp Ophthalmol*. 2015;43(6):594–6. [PubMed: 25656085]
2. Duarte G, Cheja R, Pachon D, et al. Case series: Two cases of eyeball tattoos with short-term complications. *Am J Ophthalmol Case Rep*. 2017;5:26–8. [PubMed: 29503941]
3. Chan W, Freund PR, Gjerde H, et al. Complications of ocular tattooing: a Canadian case series. *Can J Ophthalmol*. 2019;54(6):e273–e7. [PubMed: 31836111]
4. Vennam S, Georgoulas S, Khawaja A, et al. Heavy metal toxicity and the aetiology of glaucoma. *Eye (Lond)*. 2020;34(1):129–37. [PubMed: 31745328]
5. Ostheimer TA, Burkholder BM, Leung TG, et al. Tattoo-associated uveitis. *Am J Ophthalmol*. 2014;158(3):637–43 e1. [PubMed: 24875002]

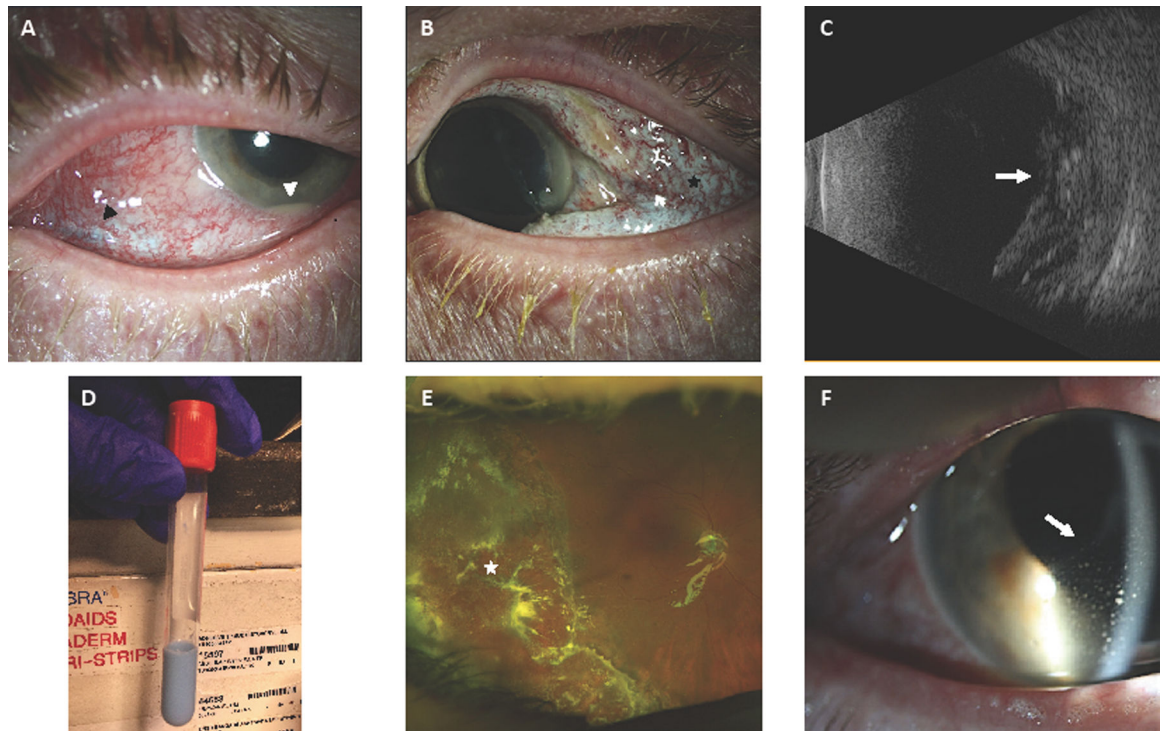


Figure 1: Key Clinical Photographs

A. Slit lamp photograph of the right eye showing conjunctival injection, inferotemporal subconjunctival blue pigmentation (black arrowhead), and a 0.5 mm hypopyon (white arrowhead).

B. Slit lamp photograph of the left eye showing conjunctival injection, diffuse subconjunctival blue pigmentation (black star), and severe conjunctival chemosis.

C. B-scan ultrasound of the right eye showing moderate vitreous opacities (white arrow), a probable retinal detachment, and diffuse thickening of the retina and choroid.

D. Photograph of surgically aspirated vitreous fluid stained with light blue tattoo ink.

E. Wide-field fundus photography of the right eye demonstrates blue debris overlying the optic nerve head and adjacent retinal tissue within the posterior pole and a region of retinectomized tissue in the temporal periphery (white star) with a surrounding laser barricade.

F. Slit lamp photograph of the right eye showing conjunctival injection and mutton fat keratic precipitates (white arrow) predominantly located in Arlt's triangle.

Table 1.

Mass Spectrometry Analysis of Vitreous Specimens

Heavy Metal	Patient Vitreous Concentration* (mcg/L)	Control Vitreous Concentration** (mcg/L)	Measurement Standard Deviation (mcg/L)	Patient / Control (%)
Titanium	623844.5	20.3	± 6.3	3073026
Chromium	1582.7	14.5	± 0.5	10815
Nickel	833.1	8.2	± 1.0	10060
Manganese	177.9	4.1	± 0.1	4239
Arsenic	98.3	0.4	± 0.1	24475
Copper	58.3	0.5	± 0.0	12856
Cobalt	25.5	0.7	± 0.1	3543
Selenium	22.0	11.2	± 1.1	96
Zinc	12.2	2.3	± 0.3	431
Antimony	9.3	7.5	± 1.8	24
Lead	3.0	0.2	± 0.1	1400
Mercury	0.4	0.2	± 0.0	100
Cadmium	0.2	0.0	± 0.0	N/A
Beryllium	0.0	0.0	± 0.0	N/A
Thallium	0.0	0.0	± 0.0	N/A

* Heavy metal concentrations in a vitreous cavity aspirate specimen from this scleral tattoo patient.

** Heavy metal concentrations in a vitreous cavity aspirate specimen from an age-matched normal control patient.