

UCLA

UCLA Previously Published Works

Title

Intestinal Perforation Following Ileoscopy Through a Prolapsed Stoma in an Pediatric Intestinal Transplant Recipient With an Unrecognized Parastomal Hernia

Permalink

<https://escholarship.org/uc/item/2ng3p2dk>

Journal

ACG Case Reports Journal, 3(4)

ISSN

2326-3253

Authors

Mehrotra, Pavni
Yeh, Joanna
Hall, Theodore R
et al.

Publication Date

2016

DOI

10.14309/crj.2016.96

Peer reviewed

Intestinal Perforation Following Ileoscopy Through a Prolapsed Stoma in an Pediatric Intestinal Transplant Recipient With an Unrecognized Parastomal Hernia

Pavni Mehrotra, MD, MS¹, Joanna Yeh, MD², Theodore R. Hall, MD³, Vatche G. Agopian, MD⁴, Douglas G. Farmer, MD⁴, Elizabeth A. Marcus, MD², Robert S. Venick, MD, MS^{2,4}, and Laura J. Wozniak, MD, MS²

¹Department of Pediatrics, David Geffen School of Medicine, UCLA, Los Angeles, CA

²Pediatric Gastroenterology, Hepatology, and Nutrition, David Geffen School of Medicine, UCLA, Los Angeles, CA

³Department of Radiology, David Geffen School of Medicine, UCLA, Los Angeles, CA

⁴Division of Liver and Pancreas Transplantation, David Geffen School of Medicine, UCLA, Los Angeles, CA

ABSTRACT

Ileoscopy with mucosal biopsy is fundamental in the management and surveillance of inflammatory bowel disease patients and intestinal transplant recipients. There is a paucity of data describing the risks of ileoscopy in the presence of a prolapsed stoma. Parastomal hernias are frequently associated with prolapsed stomas. We report the first case of perforation during ileoscopy in the setting of a prolapsed stoma and unrecognized parastomal hernia. Recognition of parastomal hernia associated with stoma prolapse is of paramount importance in patients undergoing ileoscopy as it may increase the risk of perforation.

INTRODUCTION

Retrograde ileoscopy via stoma with mucosal biopsy is an important tool in the management of inflammatory bowel disease and the gold standard for allograft surveillance after intestinal transplantation. Perforation is a rare complication of ileoscopy,¹⁻³ and the degree to which stoma prolapse and parastomal hernia increase this risk is not known.

CASE REPORT

Our patient previously underwent liver and small bowel transplant at age 1 year for underlying short bowel syndrome due to intestinal atresia and intestinal failure associated liver disease. She underwent ileostomy takedown at age 2.5 years, but due to complications from obstructive symptoms and acute rejection of her intestinal transplant, she required replacement of an end ileostomy 1 year later. She subsequently had chronic ileostomy prolapse, likely due to the extent of bowel dilation at the time of stoma creation. Conservative, nonoperative management of this stomal complication was undertaken based on her underlying medical conditions and parental wishes. Due to a long history of gastroparesis and feeding intolerance, she was dependent on gastrojejunal tube feeds.

At age 5 years, she presented for gastrojejunostomy feeding tube exchange with concurrent allograft surveillance via enteroscopy and ileoscopy with mucosal biopsy. Enteroscopy with gastrojejunostomy feeding tube exchange and surveillance mucosal biopsies was performed without incident. Digital stoma exam was performed prior to ileoscopy and was normal. Despite careful insufflation and gentle advancement of the endoscope into the prolapsed ileostomy, resistance was met and surveillance was only possible up to 20 cm. The mucosa was noted to be grossly

ACG Case Rep J 2016;3(4):e123. doi:10.14309/crj.2016.96. Published online: September 14, 2016.

Correspondence: Pavni Mehrotra, c/o Laura Wozniak, UCLA Pediatric Gastroenterology, Hepatology, and Nutrition, 10833 Le Conte Ave, MDCC 12-383, Los Angeles, CA 90095-1752 (puberoi@chla.usc.edu).



Copyright: © 2016 Mehrotra et al. This work is licensed under a Creative Commons Attribution-NonCommercial-NoDerivatives 4.0 International License. To view a copy of this license, visit <http://creativecommons.org/licenses/by-nc-nd/4.0>.

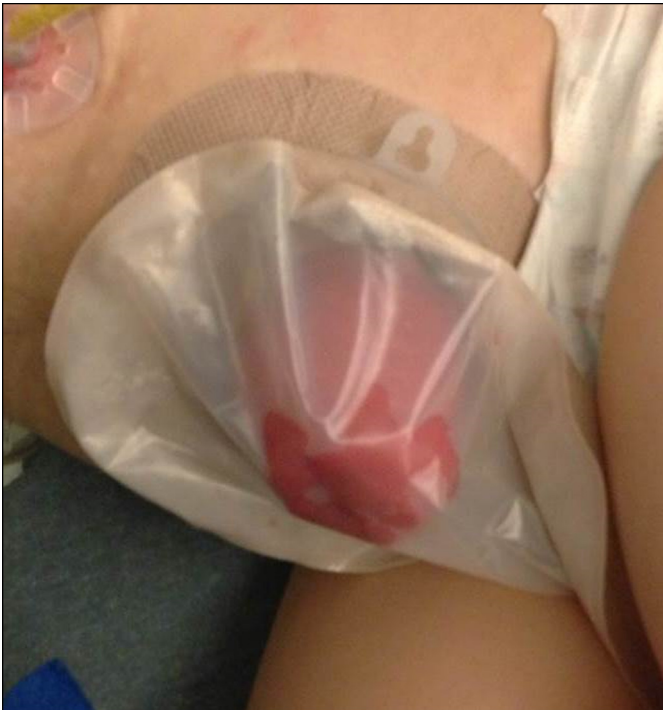

Figure 1. Increased edema of ileostomy immediately following ileoscopy.

friable. Mucosal biopsies were collected without incident, and the endoscope was withdrawn. There were no anesthesia complications during the procedure. At the conclusion of the procedure, her abdomen was soft but mildly distended. The prolapsed stoma remained pink but appeared more edematous (Figure 1). In the recovery area, the patient had progressive retching and abdominal discomfort.

Plain abdominal radiographs revealed extensive pneumoperitoneum and Rigler's sign (air in the intestinal lumen as well as free air in the peritoneal cavity) indicating perforation (Figure 2). An air bubble was also seen within the ostomy. The patient was admitted to the pediatric intensive care unit and started on broad-spectrum antibiotics. Abdominal computed tomography with contrast via both gastrojejunostomy tube and ileostomy showed free air within the peritoneum and the stoma but did not reveal the site of perforation (Figure 3). Air could be seen in a loop of bowel passing adjacent to the patient's end ileostomy.

The patient underwent exploratory laparotomy, and a perforation was found in association with a parastomal hernia (Figure 4). Once the herniated loop of bowel was reduced, the patient's stoma prolapse was significantly smaller. In addition to reduction of her parastomal hernia, the patient underwent extensive lysis of adhesions, segmental small bowel resection, and revision of her end ileostomy. Her postoperative recovery was uneventful, and she was discharged home after completing a 3-week course of intravenous antibiotics. Three years later, she is alive with functioning liver and intestinal allografts.

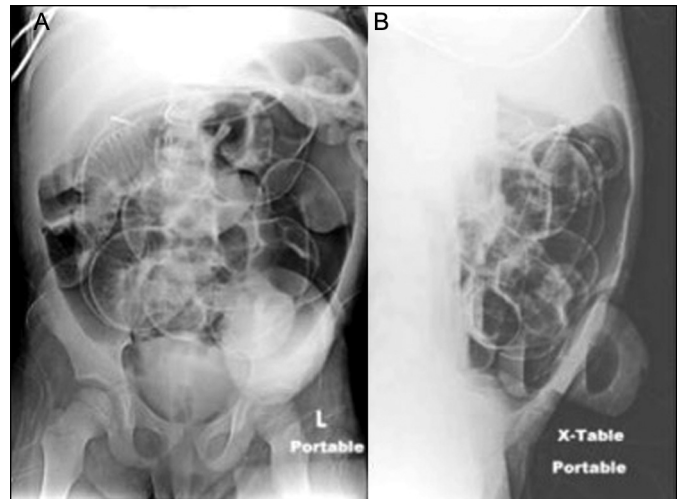


Figure 2. Abdominal radiographs revealing (A and B) extensive pneumoperitoneum and Rigler's sign (air in the intestinal lumen as well as free air in the peritoneal cavity) indicating perforation, and (B) presence of an air bubble within ostomy on cross table lateral.

DISCUSSION

Endoscopy is an essential procedure used in conjunction with other clinical tests to diagnose and manage gastrointestinal disease. It allows for direct inspection of the bowel, mucosal biopsy, and therapeutic intervention. In particular, retrograde ileoscopy via stoma is a fundamental tool used for surveillance in inflammatory bowel disease patients and intestinal transplant recipients. This procedure has been found to be safe, valuable, and relatively easy to perform in adults with Crohn's disease and a diverting or end ileostomy.¹ Similarly, it has also been reported to be safe in the intestinal transplant population. Sigurdsson et al reported only a single perforation out of 1273 endoscopies in intestinal transplant recipients, 760 of which were ileoscopies.² Data from our center showed 11 perforations out of 1770 endoscopies in intestinal transplant recipients,

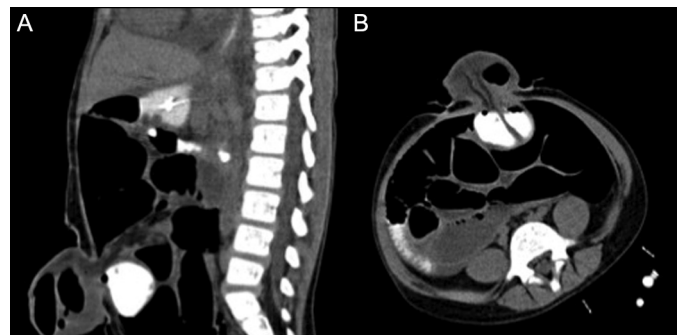


Figure 3. (A) Sagittal and (B) axial abdominal computed tomography with contrast via the gastrojejunostomy tube and ileostomy revealing free air within the peritoneum and the stoma. No enteral contrast was seen extravasating from the bowel. An air bubble was seen in the ostomy and was noted to be in a loop of bowel passing adjacent to the patient's end ileostomy.

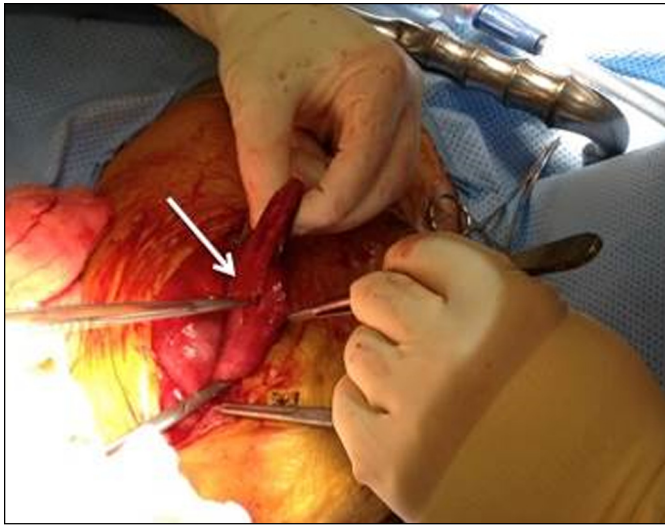


Figure 4. Intraoperative finding of an ileal perforation (white arrow) in association with a parastomal hernia.

including 725 upper endoscopies, 708 ileoscopies, and 337 colonoscopies.³ Nine of the perforations occurred during ileoscopies, while 2 occurred during colonoscopies. Although this suggests that perforation may be more likely during ileoscopy procedures, further studies are needed to better assess additional risk factors including patient clinical characteristics, stoma features, and the indications for endoscopy.

Although evidence supports that ileoscopy is overall a safe procedure, there is a paucity of data describing the risks of ileoscopy in the presence of a prolapsed stoma. Stoma prolapse is considered a late complication that occurs in up to 16% of adult patients.⁴ Obesity, increased intraabdominal pressure, chronic obstructive pulmonary disease, bowel redundancy, weak fascia, and technical factors can all lead to increased risk for stoma prolapse.⁴ End stomas have a lower incidence of prolapse than loop stomas.⁴

Stoma prolapse may occur in conjunction with a parastomal hernia, which is an incisional hernia that results in protrusion of bowel through the abdominal wall defect. Parastomal herniation is a common complication after stoma creation, with an incidence as high as 48% depending on the type of stoma and length of follow-up.⁵ As such, parastomal hernias are the most common side effect of a permanent stoma. They occur in up to 28% of end ileostomies and up to 6% of loop ileostomies.⁵ Risk factors are similar to those for stoma prolapse and include obesity, increased intraabdominal pressure, chronic obstructive pulmonary disease, advanced age, poor nutritional status, malignancy, chronic obstructive pulmonary disease, steroid use, and technical factors.^{4,6} Parastomal hernias are most often identified by the presence of a bulge within the stoma or under the adjacent skin and may be associated

with pain. However, parastomal hernias may also be asymptomatic as was the case with our patient. Diagnosis can usually be made by history, physical examination, digital examination of stoma, and computed tomography.⁷

To our knowledge, we report the first case of an intestinal perforation following routine ileoscopy through a prolapsed stoma with an unrecognized parastomal hernia. Contrast imaging failed to reveal the site of perforation; however, it was easily found upon exploratory laparotomy and noted to be associated with a parastomal hernia. We suggest that in patients with prolapsed stomas, there should be a high suspicion for parastomal hernias and extra care should be taken during endoscopy. Even if a subcutaneous bulge is not appreciated on exam, a parastomal hernia can still exist within the stoma itself. If the endoscope cannot be easily advanced into the stoma, extra pressure or force should not be exerted. Perforation should be considered in any patient with clinical deterioration following retrograde ileoscopy via stoma. Visualization of free air within the stoma on radiographic imaging is highly suggestive of a distal perforation near the stoma site or a perforation involving a loop of herniated bowel.

DISCLOSURES

Author contributions: P. Mehrotra wrote the manuscript. J. Yeh produced the figures. TR Hall, VG Agopian, DG Farmer, EA Marcus, and RS Venick revised the manuscript. LJ Wozniak wrote the manuscript and is the article guarantor.

Financial disclosure: None to report.

Informed consent was obtained for this case report.

Acknowledgements: The authors would like to thank the patient for allowing us to present the case.

Received December 9, 2015; Accepted January 28, 2016

REFERENCES

1. Vadlamudi N, Alkhoury N, Mahajan L, Lopez R, Shen B. Ileoscopy via stoma after diverting ileostomy: A safe and effective tool to evaluate for Crohn's recurrence of neoterminal ileum. *Dig Dis Sci*. 2011;56:866-70.
2. Sigurdsson L, Reyes J, Putnam PE, et al. Endoscopies in pediatric small intestinal transplant recipients: Five years experience. *Am J Gastroenterol*. 1998;93:207-11.
3. Yeh J, Ngo KD, Wozniak LJ, et al. Endoscopy following pediatric intestinal transplant. *J Pediatr Gastroenterol Nutr*. 2015;61:636-40.
4. Kim JT, Kumar RR. Reoperation for stoma-related complications. *Clin Colon Rectal Surg*. 2006;19:207-12.
5. Carne PW, Robertson GM, Frizelle FA. Parastomal hernia. *Br J Surg*. 2003;90:784-93.
6. Hotouras A, Murphy J, Thaha M, Chan CL. The persistent challenge of parastomal herniation: A review of the literature and future developments. *Colorectal Dis*. 2013;15:e202-14.
7. Shah NR, Craft RO, Harold KL. Parastomal hernia repair. *Surg Clin North Am*. 2013;93:1185-98.