

UC Davis

UC Davis Previously Published Works

Title

Adverse effects of a 10-day course of ibuprofen in Holstein calves

Permalink

<https://escholarship.org/uc/item/2164f61g>

Journal

Journal of Veterinary Pharmacology and Therapeutics, 39(5)

ISSN

0140-7783

Authors

Walsh, P
Chaigneau, FR Carvallo
Anderson, M
et al.

Publication Date

2016-10-01

DOI

10.1111/jvp.12295

Peer reviewed



HHS Public Access

Author manuscript

J Vet Pharmacol Ther. Author manuscript; available in PMC 2017 October 01.

Published in final edited form as:

J Vet Pharmacol Ther. 2016 October ; 39(5): 518–521. doi:10.1111/jvp.12295.

Short Communication: Adverse effects of a 10-day course of ibuprofen in Holstein calves

Paul Walsh^{1,2}, Francisco R CarvalloChaigneau³, Mark Anderson⁴, Nicole Behrens², Heather McEligot², Brianna Gunnarson², and Laurel J Gershwin²

¹Pediatric Emergency Medicine, Sutter Medical Center, Sacramento, and Department of Emergency Medicine, University of California Davis. 2800 L Street, Sacramento, CA

²Department of Pathology, Microbiology, and Immunology, School of Veterinary Medicine, University of California Davis, 1 Shields Ave, Davis CA 95616

³California Animal Health and Food Safety Laboratory, San Bernardino branch. 105 W Central Ave, San Bernardino, CA 92408

⁴California Animal Health and Food Safety Laboratory, 620 W. Health Sciences Drive, Davis, CA 95616

Abstract

Nonsteroidal anti-inflammatory drugs (NSAIDs) are recommended for various conditions in cattle. Ibuprofen is an inexpensive short-acting NSAID and is readily available in liquid formulation for administration to bottle-fed calves. We compared the adverse effects of a 10-day course of ibuprofen and placebo in 16 five- to six-week-old Holstein bull calves that were being treated for experimentally induced bovine respiratory syncytial virus infection. Ibuprofen was administered as a liquid in milk replacer at 30 mg/kg divided three times daily. We found an increased prevalence of abomasal ulceration 5 of 8 in the ibuprofen compared to placebo group 2 of 6 ($P = \text{NS}$). There was one (1 of 8) case of mild interstitial nephritis in the ibuprofen and none (0 of 8) in the placebo group ($P = \text{NS}$). Renal function as measured by serum BUN and creatinine levels was not different between groups; no animal demonstrated an increase in creatinine.

Nonsteroidal anti-inflammatory drugs (NSAIDs) are recommended for their anti-inflammatory and analgesic effects in cattle (Bates et al., 2015; Roberts et al., 2015) NSAIDs decreased the severity of respiratory infections in cattle and pigs in most, (Bednarek et al., 2003; Lockwood et al., 2003; Friton et al., 2004; Salichs et al., 2013) but not all trials, (Wilson et al., 2015), and NSAIDs are currently recommended as adjunctive treatment for calves with respiratory clinical signs in the Merck Veterinary Manual (Kahn & Scott, 2012). NSAIDs have also been recommended for mastitis (DeGraves & Anderson, 1993) and are used to treat lameness and pain, labeling notwithstanding.

Ibuprofen is a prototypical and widely available off-patent NSAID. The oral form is inexpensive and its liquid formulation can be administered with milk replacer. Ibuprofen has a very short half-life (1.55 h), is approved for over-the-counter use in humans, and is safe for

lactating mothers.(DeGraves et al., 1993) Significant clinical adverse effects were not reported following one 25 mg/kg dose of ibuprofen in lactating cows (DeGraves et al., 1993). The primary safety concerns for NSAIDs are their potential to cause renal impairment and gastrointestinal (GI) inflammation and ulceration. Elevation of serum creatinine has been reported in ibuprofen-treated equine foals (Breuhaus et al., 1999). One study found an asymptomatic GI ulcer in one of eight foals treated with ibuprofen (Breuhaus et al., 1999).

Our objective was to determine the prevalence of gastrointestinal and renal adverse events in calves treated with a 10-day course of ibuprofen for bovine respiratory syncytial virus (BRSV) infection.

This study was part of a 'one health' therapeutic experiment described in the human literature. Briefly, 16 five- to six-week-old Holstein bull calves were randomized to receive placebo or ibuprofen as treatment for BRSV infection. Liquid ibuprofen was administered in milk replacer at 10 mg per kilogram three times daily for 10 days. The dose and route were based on human experience and availability of the oral form (Katz, 1999). The animals were fully examined daily by a veterinarian following their morning feeding and were monitored twice daily by other trained study investigators. We selected impaired renal function and abomasal ulceration as our primary safety outcomes. The primary renal outcome was the difference between the ibuprofen and placebo groups' renal function as measured by serial serum creatinine. The secondary renal outcome was histological evidence of damage consistent with the administration of NSAIDs (Michel & Kelly, 1998). Our gastrointestinal outcome was histologically confirmed gastric ulceration. Beyond daily physical examinations, we did not seek antemortem evidence of ulceration by endoscopy. The significance of endoscopic findings in the absence of clinical signs is unclear and the stress of endoscopy might itself induce ulcerations.

We also measured anorexia, clinical signs, weight change, serum protein, albumin, albumin/globulin ratio (a marker for nephrotic syndrome), and BUN/creatinine ratio (a marker for upper GI bleeding) and included these in bivariate analysis and exact logistic regression.

Serum blood urea nitrogen (BUN) and creatinine were measured at baseline and on day 10 using a Roche Cobas c501 analyzer at a California Animal Health and Food Safety Laboratory. Necropsy was performed on day 10, and the GI tract and kidneys were examined by board certified veterinary pathologists. Suspicious appearing areas of the GI tract were further examined microscopically for ulceration. Histopathological examination was also performed in representative areas of the kidneys on paraffin-embedded, formalin-fixed tissue with hematoxylin and eosin stain.

It was determined that a 50% increase in serum creatinine would reflect a clinically important deterioration in renal function. We assumed a mean creatinine of 1.0 mg/dL, an SD of 0.3, and normal creatinine distribution; eight animals per group provided a 90% power to detect a 0.5 mg/dL increase in mean creatinine.

Categorical outcomes were compared using Fisher's exact test. BUN and creatinine were compared using Wilcoxon's rank-sum testing. Data were entered into a customized

FileMaker Pro database (FileMaker Pro Inc., Santa Clara, CA) and analyzed using Stata 13 statistical software (Statacorp LLC, College Station, TX, USA).

One animal, in the ibuprofen group, was euthanized on day 8 for respiratory distress. We used his sample from day 8 instead of the planned day 10 sample. The other calves completed the protocol uneventfully. Contrary to our expectations, serum BUN and creatinine decreased in all animals in both groups (see Fig. 1). The difference between the two groups was neither statistically nor clinically significant. No animal developed renal impairment as defined by our protocol. One calf in the ibuprofen group had mild interstitial nephritis diagnosed on histology (Fisher's exact $P = 1.0$).

We found serosal hemorrhage or ulceration of the abomasum near the pylorus in 2 of 8 (25%) of calves in the placebo group and 5 of 8 (62.5%) in the ibuprofen group (Fisher's exact $P = 0.32$). A detailed description of these is provided in Table 1 and representative photomicrographs (Fig. 2). We found no association between the outcomes and other variables.

These data have arisen from and become pertinent because of a study to evaluate the role of ibuprofen in milk replacer to decrease inflammation in pneumonia. All animals had clinically obvious upper and lower respiratory tract clinical signs and so our results are qualitatively different from studies of well animals. We found increased abomasal ulceration and a single case of renal interstitial nephritis in the ibuprofen group. Although these differences did not reach statistical significance, the results should be considered as null findings rather than definitive evidence of safety or harm. Abomasal ulcers are notoriously common in calves, particularly those fed milk replacer and with access to hay, (Welchman & Baust, 1987; Wiepkema et al., 1987; Breukink et al., 1989). The relative infrequency and lack of severity of abomasal ulcerations in the placebo group may reflect a low anxiety environment and underscores the necessity for control groups. Our duration of treatment helped to avoid underestimating adverse effects. Because we used histological endpoints, we cannot know whether resolution would have occurred on withdrawing the drug.

Our findings contrast somewhat with those of DeGraves et al. (1993) that found no increase in adverse effects in six cows given ibuprofen. The primary measure of adverse outcomes in that study was clinical findings; in these, our results are similar. We too did not suspect these adverse effects based on the calves' daily clinical examinations even though animals in this study were ill, younger, and received longer duration of treatment.

Ibuprofen is rapidly eliminated, inexpensive, off-patent, and available in a variety of formulations. However, our work suggests that some caution is in order if prolonged treatment is planned. Despite NSAIDs common mechanisms of action, human experience demonstrates substantially different side effect profiles even between members within the same class. While ibuprofen has proven remarkably safe in human children (Royer et al., 1984; Ashraf et al., 1999) a structurally similar drug suprofen was withdrawn from the market after 400 cases of renal failure were closely associated with its use (Rossi et al., 1988; Skúladóttir et al., 2010). Given the potential for such idiosyncrasies, drug safety data need to be gathered on an individual as well as a class basis.

The main limitation of our study is its small sample size. A larger sample size would let us better address whether our findings are indicative of an underlying increase in risk with ibuprofen. However, a relative strength of our study is the use of two groups. Although this decreased the number of calves receiving ibuprofen, it facilitated the comparison between the outcomes with comparably ill calves in which ibuprofen or another NSAID might be prescribed. Our gastrointestinal tract findings may not apply to older cattle where abomasal ulceration is much less common (Aukema & Breukink, 1974). Our study examined adverse effects in calves with acute BRSV infection, and this could have led to increased adverse events compared with healthy calves. Focal interstitial nephritis can arise from other specific and nonspecific causes with reported prevalence of 4% (abattoir) to 10% (condemned calves) (Monaghan & Hannan, 1983; Biss et al., 1994; Maxie & Newmann, 2007). However, this lesion is also characteristic of NSAID exposure. Another limitation is the relative insensitivity of creatinine to renal function changes. Serial inulin or iodixanol measurement of renal functions would have been preferable (Imai et al., 2012; Murayama et al., 2013). However, such measurements of renal function are of uncertain clinical importance in the face of normal range creatinine. Neutrophil gelatinase-associated lipocalin (NGAL) is another potentially attractive marker for renal impairment. However, enzyme-linked immunoadsorbent-based assays done on serum or plasma are performed poorly in bottle-fed calves due to the high lipemic index from high-fat milk replacer.

In conclusion, serum creatinine levels remained within a similar range for both groups. Abomasum ulceration occurred more in ibuprofen than placebo-treated animals, but this did not reach statistical significance. A single case of renal interstitial nephritis occurred in the ibuprofen group. A larger study is required to determine the boundaries of the effect size of these adverse effects of ibuprofen in calves.

References

- Ashraf E, Ford L, Geetha R, Cooper S. Safety profile of ibuprofen suspension in young children. *Inflammopharmacology*. 1999; 7(3):219–225. [PubMed: 17638093]
- Aukema JJ, Breukink HJ. Abomasal ulcer in adult cattle with fatal haemorrhage. *Cornell Veterinarian*. 1974; 64(2):303–317. [PubMed: 4856975]
- Bates AJ, Eder P, Laven RA. Effect of analgesia and anti-inflammatory treatment on weight gain and milk intake of dairy calves after disbudding. *New Zealand Veterinary Journal*. 2015; 63(3):153–157. [PubMed: 25371291]
- Bednarek D, Zdzisi ska B, Kondracki M, Kandefer-Szersze M. Effect of steroidal and non-steroidal anti-inflammatory drugs in combination with long-acting oxytetracycline on non-specific immunity of calves suffering from enzootic bronchopneumonia. *Veterinary Microbiology*. 2003; 96(1):53–67. [PubMed: 14516708]
- Biss ME, Alley MR, Madie P, Hathaway SC. Lesions in the carcasses and viscera of very young slaughter calves condemned at post-mortem meat inspection. *New Zealand Veterinary Journal*. 1994; 42(4):121–127. [PubMed: 16031761]
- Breuhaus BA, DeGraves FJ, Honore EK, Papich MG. Pharmacokinetics of ibuprofen after intravenous and oral administration and assessment of safety of administration to healthy foals. *American Journal of Veterinary Research*. 1999; 60(9):1066–1073. [PubMed: 10490073]
- Breukink HJ, Wensing T, van Dijk S, Mevius D. Effect of clenbuterol on the incidence of abomasal ulcers in veal calves. *Veterinary Record*. 1989; 125(5):109–111. [PubMed: 2773244]
- DeGraves FJ, Anderson KL. Ibuprofen treatment of endotoxin-induced mastitis in cows. *American Journal of Veterinary Research*. 1993; 54(7):1128–1132. [PubMed: 8368609]

- DeGraves FJ, Anderson KL, Aucoin DP. Pharmacokinetics of ibuprofen in lactating dairy cows. *American Journal of Veterinary Research*. 1993; 54(7):1133–1135. [PubMed: 8368610]
- Friton GM, Cajal C, Ramirez Romero R, Kleemann R. Clinical efficacy of meloxicam (Metacam) and flunixin (Finadyne) as adjuncts to antibacterial treatment of respiratory disease in fattening cattle. *Berliner und Münchener tierärztliche Wochenschrift*. 2004; 117(7-8):304–309. [PubMed: 15298058]
- Imai K, Yamagishi N, Okura N, Fukuda T, Hirata T, Okada K, Sato S, Furuhashi K. Estimation of glomerular filtration rate in calves using the contrast medium iodixanol. *The Veterinary Journal*. 2012; 193(1):174–179. [PubMed: 22064323]
- Kahn, C.; Scott, S. *The Merck Veterinary Manual*. In: Aiello, S.; Moses, M., editors. *The Merck Veterinary Manual*. Merck & Co; Whitehouse Station, N.J: 2012.
- Katz, L. Letter to McNeill Healthcare Ed Services. D.o.H. Federal Drug Administration; Rockville, MD: 1999. Letter to McNeill Healthcare.
- Lockwood PW, Johnson JC, Katz TL. Clinical efficacy of flunixin, carprofen and ketoprofen as adjuncts to the antibacterial treatment of bovine respiratory disease. *Veterinary Record*. 2003; 152(13):392–394. [PubMed: 12696705]
- Maxie, M.; Newmann, S. *Jubb, Kennedy, and Palmer's Pathology of Domestic Animals*. 5th. Maxie, M., editor. Elsevier; Pennsylvania: 2007. p. 452-552.
- Michel DM, Kelly CJ. Acute interstitial nephritis. *Journal of the American Society of Nephrology*. 1998; 9(3):506–515. [PubMed: 9513915]
- Monaghan ML, Hannan J. Abattoir survey of bovine kidney disease. *Veterinary Record*. 1983; 113(3): 55–57. [PubMed: 6604362]
- Murayama I, Miyano A, Sasaki Y, Kimura A, Sato S, Furuhashi K. Glomerular filtration rate in Holstein dairy cows estimated from a single blood sample using iodixanol. *Journal of Dairy Science*. 2013; 96(8):5120–5128. [PubMed: 23791486]
- Roberts SL, Hughes HD, Burdick Sanchez NC, Carroll JA, Powell JG, Hubbell DS, Richeson JT. Effect of surgical castration with or without oral meloxicam on the acute inflammatory response in yearling beef bulls. *Journal of Animal Science*. 2015; 93(8):4123–4131. [PubMed: 26440192]
- Rossi AC, Bosco L, Faich GA, Tanner A, Temple R. The importance of adverse reaction reporting by physicians. Suprofen and the flank pain syndrome. *JAMA*. 1988; 259(8):1203–1204. [PubMed: 3276945]
- Royer GL, Seckman CE, Welshman IA. Safety Profile: Fifteen Years of Clinical Experience with Ibuprofen. *The American Journal of Medicine*. 1984; 77(1, Part 1):25–34. [PubMed: 6235745]
- Salichs M, Sabate D, Homedes J. Efficacy of ketoprofen administered in drinking water at a low dose for the treatment of porcine respiratory disease complex. *Journal of Animal Science*. 2013; 91(9): 4469–4475. [PubMed: 23825328]
- Skúladóttir HM, Andrésdóttir MB, Hardarson S, Árnadóttir M. The acute flank pain syndrome: a common presentation of acute renal failure in young males in Iceland. *NDT Plus*. 2010; 3(5):510–511. [PubMed: 25984076]
- Welchman DD, Baust GN. A survey of abomasal ulceration in veal calves. *Veterinary Record*. 1987; 121(25-26):586–590. [PubMed: 3438993]
- Wiepkema PR, Van Hellemond KK, Roessingh P, Romberg H. Behaviour and abomasal damage in individual veal calves. *Applied Animal Behaviour Science*. 1987; 18(3):257–268.
- Wilson BK, Step DL, Maxwell CL, Wagner JJ, Richards CJ, Krehbiel CR. Evaluation of multiple ancillary therapies used in combination with an antimicrobial in newly received high-risk calves treated for bovine respiratory disease. *Journal of Animal Science*. 2015; 93(7):3661–3674. [PubMed: 26440032]

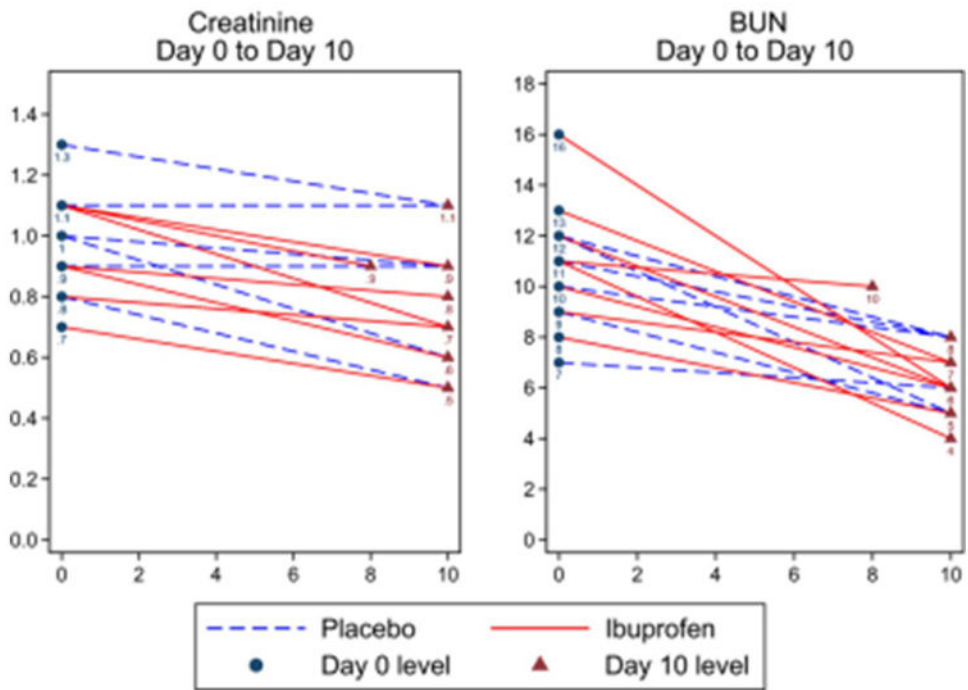


Figure 1. Creatinine and BUN levels for each animal in mg/dL. Results end on day 8 for one animal who was euthanized on Day 8 of treatment.

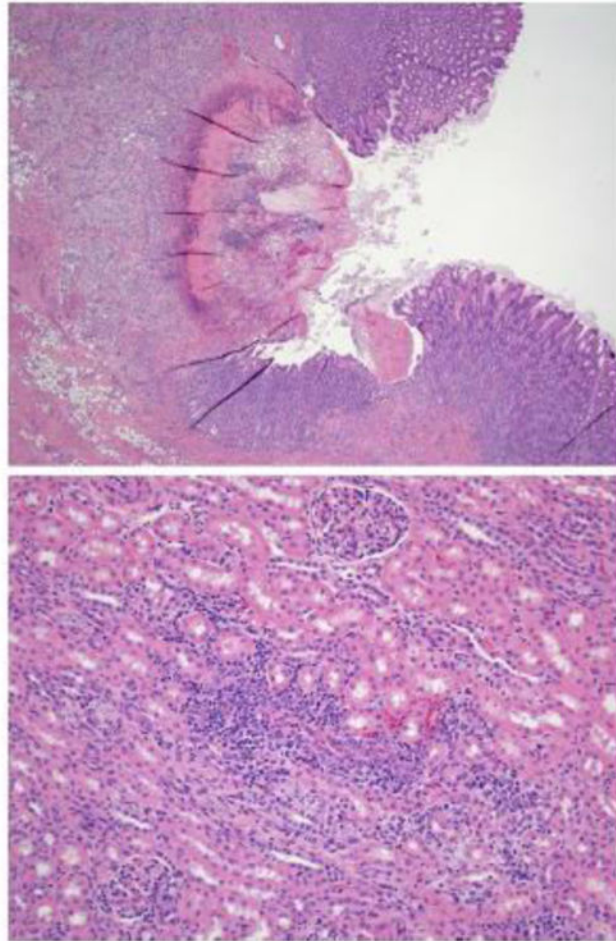


Figure 2.
(Top panel) Example of abomasal ulcer, this from Calf 186. hematoxylin and eosin (H&E) stain $\times 4$. (Bottom panel) Interstitial nephritis, this from calf 145. H&E stain $\times 20$.

Table 1

Histological gastrointestinal tract findings by drug group. The first column is the animals' ear tag ID.

Animal	Drug	Histological Findings
169	Placebo	In the pylorus, there was a single pinpoint red focus on the mucosa.
178	Placebo	In the abomasum, in the pyloric region, there are eight 1 mm diameter red foci interpreted as ulcerations
153	Ibuprofen	In the pyloric region of the abomasum, there are more than a dozen linear red depressed lesions in the mucosa, interpreted as ulcers that are approximately 1 mm wide and up to 1 cm in length
155	Ibuprofen	In the abomasum, there is a linear mucosal ulceration near the pylorus that is approximately 1 cm in length and 2 mm in width
156	Ibuprofen	In the pyloric region of the abomasum, there are five areas of depression in the mucosa, which tend to be irregularly linear, about 1 mm in width and up to 1 cm in length. These were interpreted as areas of mucosal ulceration.
185	Ibuprofen	In the serosa of the abomasum, on the greater curvature at the fundic pyloric junction, there is an oval 8 cm diameter area of a serosal hemorrhage with no obvious mucosal lesions associated.
186	Ibuprofen	Abomasal ulcer